

## Intervention in Patients with Maxillary Skeletal Insufficiency

*James A. McNamara, M. Thomas, D. Graber; United States*

Orthodontists deal on a daily basis with concerns about the transverse dimension, with manifestations often expressed clinically as crossbite, both anterior and posterior. A less obvious but far more common orthodontic problem, whose etiology in part is related to imbalances in the transverse dimension, is a discrepancy between tooth size and arch size, which can be seen clinically as crowding or protrusion of the teeth. A previous investigation of this relationship by our group (Howe et al 1983) found that dental crowding was associated more commonly with small dental arches than with large tooth size. One solution to this problem is the use of rapid maxillary expansion (RME) in growing patients, even in patients who do not exhibit crossbites.

For more than 25 years, we have been studying the relationship between tooth-size and arch-perimeter imbalances and the transverse dimension. We have been gathering data both retrospectively and prospectively concerning the treatment effects of RME initiated in mixed- and early permanent-dentition patients. The first investigation (McNamara et al 1983) examined the treatment effects produced by a Haas-type RME followed by fixed appliance therapy. An attempt was made to recall all patients treated during a specific time interval in a single private practice who had undergone RME followed by standard edgewise orthodontics and who were 5 or more years posttreatment. Longitudinal dental casts from 112 patients were obtained and analyzed. On average, subjects were 12 years 2 months of age at the time of initial records, 14 years 6 months of age at the end of treatment, and 20 years 5 months of age at the time of long-term records. For controls, the longitudinal dental casts from 41 untreated subjects were matched according to age and analyzed at the same time periods. To summarize the findings of this study briefly, when the normally occurring decreases in arch perimeter seen in the control group were taken into consideration, the residual relative increases in maxillary and mandibular arch perimeter were 6.0 and 4.5 mm, respectively, in the treated group at age 20 years—clinically relevant amounts.

Chang and coworkers (1997) analyzed a randomly chosen subgroup of patients from the previously described sample. The purpose of their investigation was to examine cephalometrically the long-term effects of RME on bite opening and on the anteroposterior position of the maxilla. The sample was comprised of 25 patients who had undergone rapid maxillary expansion with the Haas-type expander followed by standard edgewise therapy. This RME sample was compared to a group of 25 patients who had undergone single-phase edgewise treatment and to an untreated control group of 23 subjects. The results of this study indicated that RME therapy followed by fixed appliances had little long-term effect on either the vertical or anteroposterior dimensions of the face (ie, no clinically significant side effects).

The next group of studies involves the prospective treatment of patients in the early mixed dentition. Since 1981, we have gathered cephalometric and dental cast data on all young patients undergoing RME therapy, with or without prior dental decompensation with a Schwarz appliance, in the author's private group faculty practice. This longitudinal prospective sample has been the basis of several publications; two recent studies will be described here.

Geran and coworkers (2005) evaluated the serial study models of 51 patients (average age, 8 years 10 months) who underwent early treatment with a bonded acrylic splint expander (Fig 1), followed by a removable palatal plate as a retainer. About two thirds of the patients had four brackets placed temporarily on the maxillary anterior teeth to achieve incisal alignment (see Fig 1). Phase II treatment with fixed appliances was completed when the patients were 13 years 10 months of age, and follow-up records were obtained 6 years later (19 years 9 months). Geran and coworkers found that the increases in transpalatal width present at the end of active treatment were maintained at the time of follow-up records. In addition, in comparison to a matched control group, residual maxillary arch perimeter was 3.8 mm greater in the treated group than in the controls. Similarly, residual mandibular arch perimeter was 2.6

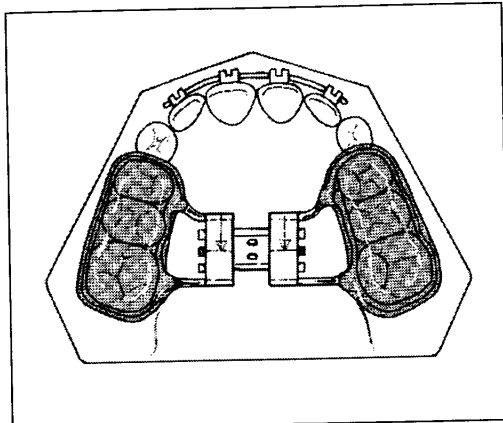


Fig 1 Bonded acrylic expander.

mm greater in the RME group than in the controls, although no active expansion of the mandibular dental arch was attempted in Phase I.

O'Grady and colleagues (2005) studied the long-term records of 23 patients who were treated with a Schwarz appliance followed by RME and later by Phase II fixed-appliance treatment. They compared the changes in dental arch dimensions of these patients to 27 RME/fixed appliance

patients and 16 matched controls. As with the Geran study, patients in the O'Grady study began treatment at about 9 years of age, finished fixed appliance treatment at about 14.5 years, and were recalled for records at 20 to 21 years of age. The Schwarz/RME protocol results in available maxillary arch perimeter were 3.8 mm larger than closely matched controls; mandibular arch perimeter was 3.7 mm larger than control values. The findings of the O'Grady study were similar to the Geran study regarding the findings for the RME/fixed appliance group.

Although the evaluation of the long-term data from this rather large study of patients (N = 1,135) treated in a private practice setting is ongoing, the analysis of the data thus far is very promising regarding the long-term stability of patients with borderline crowding problems managed with these treatment protocols. We now are examining other treatment effects associated with this protocol of expanding the maxilla in the early mixed dentition, including the so-called spontaneous correction of Class II malocclusion, the facilitation of permanent canine eruption, "broadening the smile," and the flattening of the Curve of Wilson. Many such clinical problems appear simultaneously in the same patient, a patient with underlying maxillary skeletal deficiency. Thus, RME is available as a useful adjunct to fixed appliance treatment in a variety of situations other than simply the correction of a crossbite.

## SL019

### SHORT LECTURE

# Novel Experimental Model for Tooth Movement Using Genetically Engineered Animals

*Keiji Moriyama, S. Fujihara, S. Nomura; Japan*

**O**rthodontic force induces cellular dynamic changes in the periodontal ligament (PDL) and alveolar bone. The sequence of molecular events that occurs during tooth movement has been extensively studied, mostly by conventional histologic and cell biological experiments. Osteopontin (OPN) is a major noncollagenous bone matrix protein involved in physiologic and pathologic calcification. It has also been found that *OPN* gene expression in

osteocytes is enhanced by mechanical stress loading during tooth movement. The aim of this study was to investigate the regulatory mechanism of *OPN* gene expression during tooth movement with a new in vivo experimental model using genetically engineered mice.

The transgenic mice carrying various lengths of the 5'-flanking sequence jointed with green fluorescence protein (GFP) cDNA were generated. The maxillary first molars were