


Utility Arches



JAMES A. MCNAMARA, DDS, PHD

The utility arch has multiple uses in various stages of orthodontic treatment. This auxiliary archwire has been developed according to biomechanical principles described by Burstone^{1,2} and refined for incorporation into Bio-progressive therapy.^{3,4}

Although it is a complete arch extending across both buccal segments, the utility arch engages only the first molars and the four incisors. It originally was developed to provide a method of leveling the curve of Spee in the mandible, but it has been adapted to perform many more functions than just lower incisor intrusion.

With an .018" appliance, the recommended wire for the mandibular arch is .016" x .016" or .016" x .022" Blue Elgiloy (not heat-treated). For most maxillary arches, .016" x .022" Blue Elgiloy is recommended. With an .022" appliance, .019" x .019" Blue Elgiloy can be used in either arch.

When using utility arches in combination with full arch appliances, it is necessary to have auxiliary tubes in a gingival position on the first molar bands. In a pre-orthopedic phase of treatment when the buccal segments are not banded, the main buccal tube or bracket on the first molar can be used to anchor the utility arch posteriorly.

Passive Utility Arch

The passive utility arch can be used for stabilization or space holding. It is ideal in the mixed dentition, when it permits eruption of the canines and premolars. A passive utility arch by definition is not activated and should not move teeth in any direction.

Dr. McNamara is Professor of Dentistry (Orthodontics), Professor of Anatomy and Cell Biology, and Research Scientist at the Center for Human Growth and Development, The University of Michigan, Ann Arbor. He is in the private practice of orthodontics in Ann Arbor.

A passive utility arch (Fig. 1) originates in the auxiliary tube on the first molar. The *molar segment* of the archwire is cut flush with the distal aspect of the auxiliary tube. Immediately anterior to the tube, a 90° bend is placed with a 142 arch-forming plier, and a *posterior vertical step*, usually 3-4mm long, is formed.

Another right-angle bend is then placed in the wire, so that the *horizontal or vestibular segment* travels anteriorly parallel to the occlusal plane. At the embrasure between the canine and the lateral incisor, another right-angle bend redirects the wire toward the occlusal surface.

After an *anterior vertical step* of 5-8mm, a final 90° bend creates the *incisal segment*, which should lie in the brackets of the lower anterior teeth. Any irregularities in the position of the lower anterior teeth are usually corrected with a sectional leveling arch before a utility arch is placed. The archwire continues in a similar fashion to the opposite molar.

Intrusion Utility Arch

The intrusion utility arch is designed similarly to the passive arch, but it is activated to intrude the lower anterior teeth.⁵ After activation, a light continuous force is delivered by the long lever arm from the molars to the incisors. As with the passive arch, the intrusion arch is stepped down at the molars, passes through the buccal vestibule, and is stepped up at the incisors to avoid distortion from occlusal forces.

Engaging the utility arch will produce approximately 25g of force on each of the lower incisors—a force level considered ideal for lower incisor intrusion.³ The overall effect is an intrusion and possible torquing of the lower incisors, as well as a tipping back of the lower molars (Fig. 2). Molar rotation and expansion

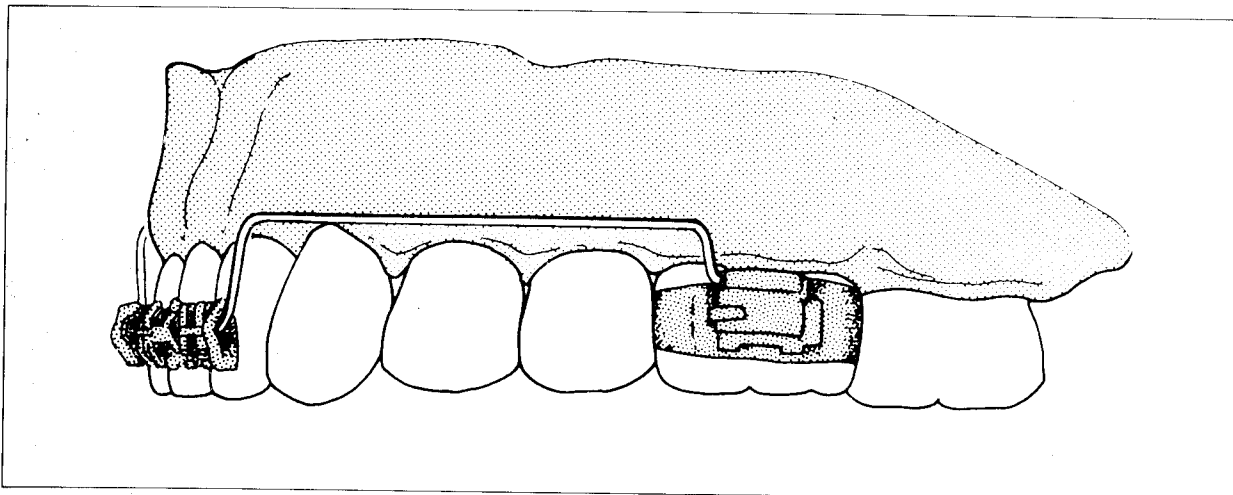


Fig. 1 Passive utility arch, with posterior vertical step fitting snugly against auxiliary tube on lower first molar.

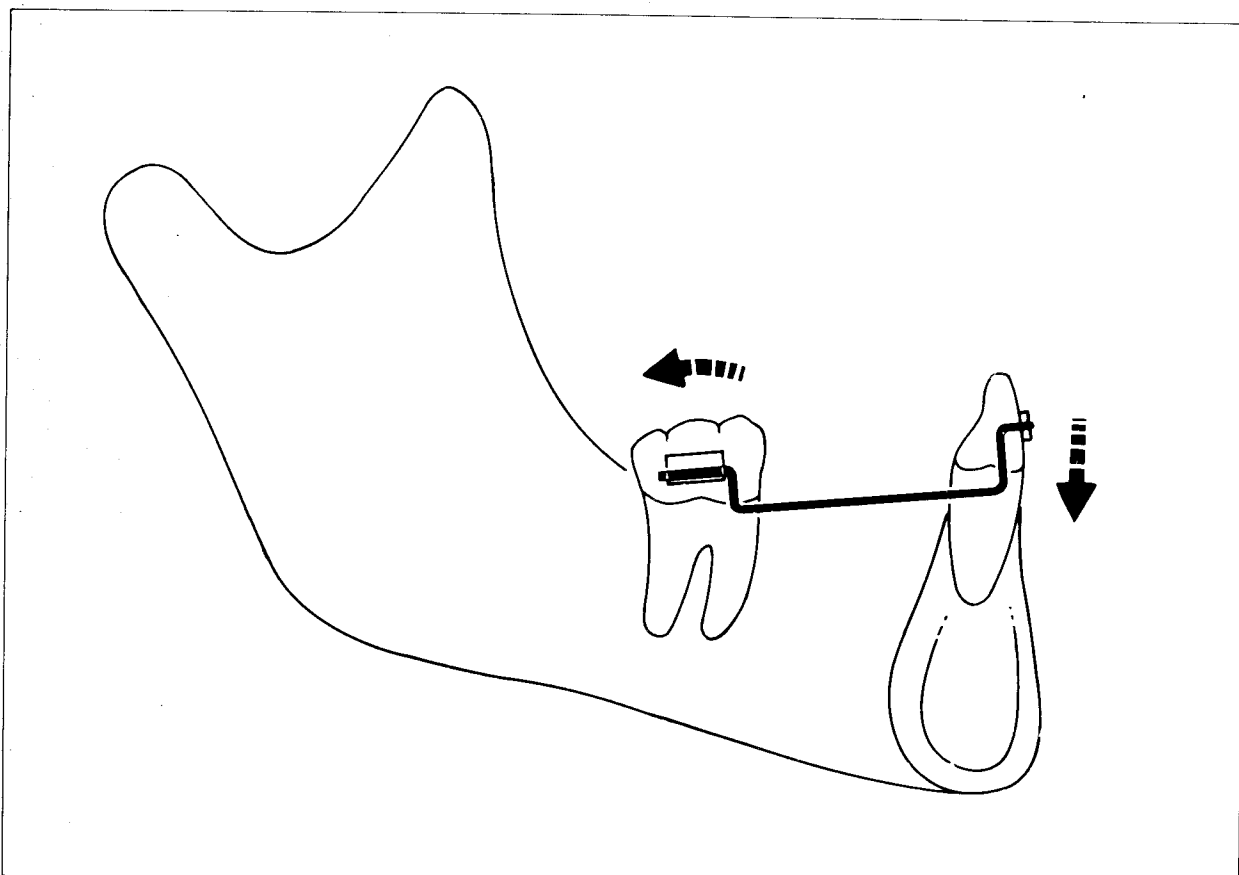


Fig. 2 Effect of intrusive force on mandibular incisors: incisors are intruded and torqued while molar is tipped posteriorly.

UTILITY ARCHES

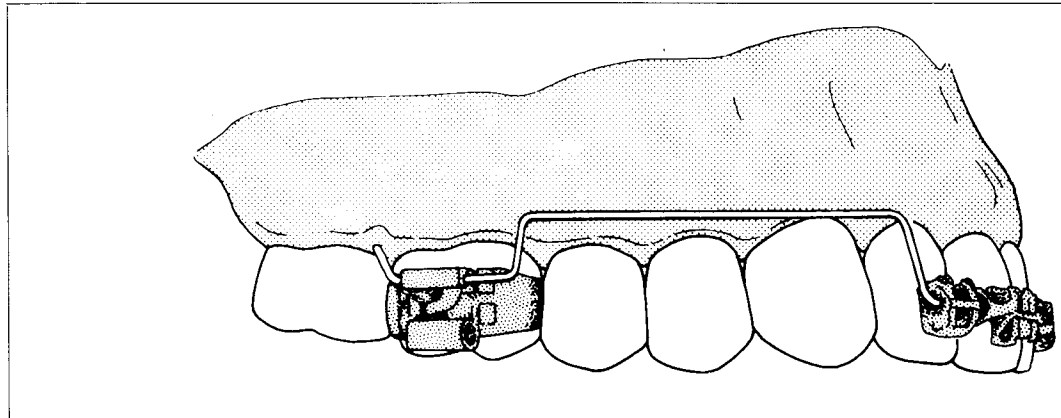


Fig. 3 Intrusion utility arch, with posterior vertical step 5-8mm anterior to auxiliary tube on upper first molar, allowing slight retrusive activation.

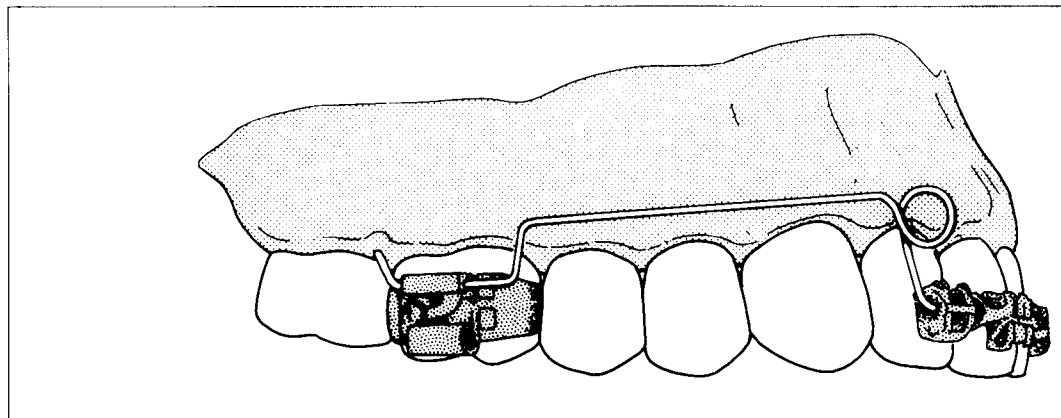


Fig. 4 Retraction utility arch. The loop anterior to the anterior vertical step is activated while the molar segment is retruded.

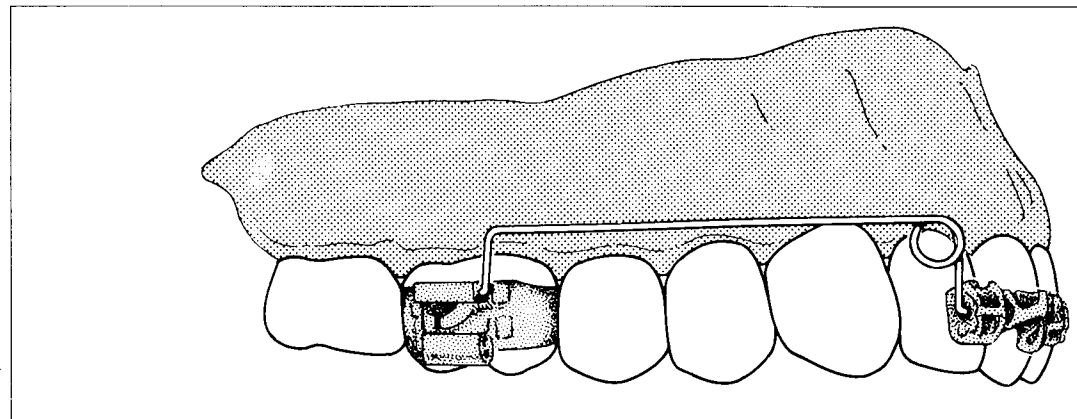


Fig. 5 Protrusion utility arch, with posterior vertical step fitting flush against auxiliary molar tube.

or contraction of molar width can be achieved by activating the molar section of the arch.

Figure 3 shows an intrusion utility arch designed for the maxilla. Here there is a 5mm space between the anterior border of the auxiliary tube and the posterior vertical step of the utility arch. This allows a slight retrusive activation of the arch to be made by pulling the wire posteriorly and then twisting the end of the arch gingivally.

Any type of utility arch can be activated for an intrusive movement by placing an occlusally directed gable bend in the vestibular segment. A loop-bending plier can be used for this activation during a routine office visit.

Retrusion Utility Arch

The usefulness of a retrusion utility arch (Fig. 4) in retracting and intruding incisors is obvious in cases of upper incisor flaring. However, this type of mechanics is also helpful in retracting the four anterior teeth as a unit, particularly in the maxilla. The retrusion utility arch can close interproximal spaces while intruding and aligning the upper anterior teeth and correcting midline discrepancies.

The retrusion arch originates in the auxiliary tube on the molar, and 5-8mm of wire should protrude anteriorly before a posterior vertical step of 3-4mm is placed. The vestibular segment extends anteriorly to the interproximal region between the lateral incisor and the canine. At this point, a 90° bend is placed with a 142 arch-bending plier.

A loop-bending plier is then used to place a loop in which the anterior leg crosses behind the posterior leg. After a 5-8mm anterior vertical step, another right-angle bend then carries the wire across the anterior teeth. A gentle anterior contour is placed in the wire to simulate the arch form.

On the other side of the arch, the anterior vertical step is again created in the interproximal area between lateral incisor and canine. The retraction loop is again placed with the loop-bending plier, and then the loop-bending

plier (instead of the arch-forming plier) is used to create the 90° bend to the horizontal vestibular segment. This then extends to the posterior vertical step at the middle of the second premolar.

As with the intrusion utility arch, there are two possible types of activation. First, a Weingart plier can be used to grasp the extension of the utility arch posterior to the auxiliary tube. The wire is pulled 2-3mm posteriorly and then bent upward at a 90° angle. Care must be taken that this protruding end of the utility arch does not impinge on the gingiva or cheek. Second, an occlusally directed gable bend in the vestibular segment can be used to produce intrusion.

Protrusion Utility Arch

The protrusion utility arch is useful for proclining upper and lower incisors. It is most commonly used for flaring and intruding maxillary incisors in Class II cases (Fig. 5).

In contrast to the retrusion utility arch, the posterior vertical step of the protrusion arch must be flush with the auxiliary tube. The vestibular segment traverses anteriorly to the interproximal region between the canine and lateral incisor. A loop-bending plier is then used to place a loop distal to the anterior vertical step and occlusal to the vestibular segment. The anterior leg of the loop should be positioned mesially, thus providing some canine offset.

The anterior vertical step is 5-8mm long, depending on patient tolerance. The incisal segment runs through the incisor brackets, and the utility arch is completed in a similar fashion on the other side.

When the protrusion utility arch is passive, the anterior segment should lie approximately 2mm anterior to its expected position in the incisor brackets. The protrusive force is produced by tying the anterior segment of the utility arch into the anterior brackets. An occlusally directed gable bend in the vestibular segment can be used for intru-

UTILITY ARCHES

sion.

The protrusion arch is activated by removing the anterior segment from the brackets, bending the posterior vertical step forward from 90° to 45°, and replacing the archwire in the brackets. Other adjustments can be made in both the anterior and posterior vertical steps to produce further activation.

Other Considerations

While the above material represents the types of utility arches used clinically by the author, other clinicians have mentioned various modifications of these archwires.

If one is concerned about unwanted posterior tipping of the molar, this can be reduced significantly by placing torque in the auxiliary tube so the roots of the molars are tipped buccally into the buccal cortical plate.^{3,4} This so-called "cortical anchorage" is reported to be particularly effective in the mandible.

Utility arches can be designed differently for extraction and nonextraction cases.^{3,4} In extraction cases, the forces generated on the molars are often directed mesially and occlusally. A distolingual bend in the molar segment of the utility arch can prevent this mesial rotation of the first molars. Such a bend may not be necessary in nonextraction cases.

A utility arch can incorporate a tipback bend of 30-45° at the junction of the posterior vertical step and the molar segment. This allows an automatic intrusive activation as the archwire is engaged in the brackets. When the utility arch is engaged passively in the auxiliary tube, the anterior segment usually lies in the vestibule. The tipback bend may or may not be placed during initial fabrication; a similar effect can be gained with the vestibular gable bend after appliance placement.

Conclusion

The utility arch is an integral part of interceptive as well as comprehensive orthodontic treatment. It is efficient in intruding upper and lower incisors and is especially effective in protruding and retruding anterior teeth.

One of the major difficulties in correcting anteroposterior discrepancies (particularly in Class II malocclusion) is an impairment of anteroposterior tooth movement by anterior vertical interference. Utility arches can be used—both in orthopedic and orthognathic surgical therapy—to move upper and lower incisors gingivally so that tooth position can be properly corrected.

ACKNOWLEDGMENTS: Illustrations by Mr. William L. Brudon.

REFERENCES

1. Burstone, C.D.: Mechanics of the segmented arch technique, *Angle Orthod.* 36:99-120, 1966.
2. Burstone, C.D.: Deep overbite correction by intrusion, *Amer. J. Orthod.* 72:1-22, 1977.
3. Bench, R.W.; Gugino, C.F.; and Hilgers, J.J.: Bioprogressive Therapy, Part VII: The utility and sectional arches in Bioprogressive therapy mechanics, *J. Clin. Orthod.* 12:192-207, 1978.
4. Ricketts, R.M.; Bench, R.W.; Gugino, C.F.; Hilgers, J.J.; and Schulhof, R.J.: *Bioprogressive Therapy*, Rocky Mountain Orthodontics, Denver, 1979.
5. Otto, R.L.; Anholm, J.M.N.; and Engel, G.A.: A comparative analysis of intrusion of incisor teeth achieved in adults and children according to facial type, *Amer. J. Orthod.* 77:437-446, 1980.

*Department of Orthodontics
1027 Kellogg Dental Building
School of Dentistry
The University of Michigan
Ann Arbor, MI 48109*