

Treatment and posttreatment craniofacial changes after rapid maxillary expansion and facemask therapy

Tiziano Baccetti, DDS, PhD,^a Lorenzo Franchi, DDS, PhD,^b and James A. McNamara, Jr, DDS, PhD^c

Florence, Italy, and Ann Arbor, Mich

The aim of this study was to evaluate treatment and posttreatment dentoskeletal changes in 2 groups of subjects with Class III malocclusions. Subjects were treated with a bonded acrylic-splint expander and a face mask, and the optimal timing for this treatment protocol was assessed. The treated sample (29 subjects) was divided into 2 groups according to the stage of dental development. The early treatment group consisted of 16 subjects in the early mixed dentition (erupting permanent incisors and/or first molars), whereas the late treatment group consisted of 13 subjects in the late mixed dentition (erupting permanent canines and premolars). Cephalograms were available at 3 time periods: T_1 , pretreatment, T_2 , end of active treatment, and T_3 , posttreatment. The mean T_1 - T_2 interval (active treatment period) and the mean T_2 - T_3 interval (posttreatment period) were approximately 1 year each in both treatment groups. None of the patients wore any skeletal retention appliance during the posttreatment period (T_2 - T_3). Groups of subjects with untreated Class III malocclusion were used as controls at both observation intervals. A significant increase in the sagittal growth of the maxilla was seen only when treatment was performed in the early mixed dentition. A restraining effect on mandibular growth rate associated with a more upward and forward direction of condylar growth was found in both treatment groups. An increase in vertical intermaxillary relationships was observed in Class III patients treated in the late mixed dentition. Posttreatment, the Class III craniofacial growth pattern was re-established in the absence of any skeletal retention appliance. Relapse tendency affects the sagittal growth of the maxilla in the early treated subjects and the sagittal position of the mandible in the late treated subjects. Orthopedic treatment of Class III malocclusion in the early mixed dentition is able to induce more favorable craniofacial adaptations than treatment in the late mixed dentition. (Am J Orthod Dentofacial Orthop 2000;118:404-13)

One of the greatest challenges in contemporary orthodontics and dentofacial orthopedics is to obtain stable favorable outcomes after orthopedic treatment of Class III malocclusion. Unfortunately, evaluation of the modifications that occur after treatment of a skeletal disharmony with effective appliances, such as a face mask combined with rapid maxillary expansion, is constrained by a series of limiting factors, including:

1. The scarcity of cephalograms taken during the post-treatment period;
2. The difficulty of both defining and calculating actual "relapse" after active therapy, due to the use of different skeletally based appliances for retention; and
3. The very limited availability of groups of untreated subjects with Class III malocclusion followed lon-

gitudinally during growth to serve as controls for the appraisal of posttreatment changes.

A few indications about dentoskeletal changes after active therapy of Class III malocclusion by means of maxillary expansion and protraction can be derived from the literature.¹⁻⁴ Regardless of the retention protocol after active orthopedic treatment of Class III skeletal disharmony, most clinical studies seem to agree that maxillary and mandibular growth rates in the postprotraction period are similar in treated and untreated Class III subjects. For example, Shanker et al¹ found no significant differences in horizontal and vertical changes at A-point in treated Chinese children compared with untreated children with Class III malocclusion matched for gender, age, and race. A 12-month posttreatment period was examined, and no retention appliance was used at the completion of active treatment.

Ngan et al² analyzed maxillary and mandibular modifications in a sample of Chinese subjects with Class III malocclusions treated with a banded expander and a face mask and compared these patients with a matched control group. A few patients in this study wore a mandibular retractor for retention. The maxilla was found to move forward and downward at a slightly greater rate in the treated group than in the controls during the first 2

^aResearch Associate, Department of Orthodontics, The University of Florence.

^bPostdoctoral Resident, Department of Orthodontics, The University of Florence.

^cThomas M. and Doris Graber Endowed Professor of Dentistry, Department of Orthodontics and Pediatric Dentistry, School of Dentistry; Professor of Cell and Developmental Biology, School of Medicine; and Research Scientist, Center for Human Growth and Development, The University of Michigan, Ann Arbor.

Reprint requests to: Tiziano Baccetti, DDS, PhD, Università degli Studi di Firenze, Via del Ponte di Mezzo, 46-48, 50127, Firenze, Italy; e-mail, con-dax@tin.it.

Submitted, February 2000; revised and accepted, April 2000.

Copyright © 2000 by the American Association of Orthodontists.

0889-5406/2000/\$12.00 + 0 8/1/109840

doi:10.1067/mod.2000.109840

Table I. Mean age and age range for treated groups at different observation times, and mean duration of observation intervals

	Treated sample (n = 29)					
	Early treatment group (n = 16)			Late treatment group (n = 13)		
	Mean	SD	Min-Max	Mean	SD	Min-Max
T ₁	7y	7m	5y 5m-7y 8 m	8y 8m	1y	7y 8m-10y
T ₂	7y 9m	8m	6y 6m-9y 2m	9y 7m	11m	8y 4m-10y 10m
T ₃	8y 10m	11m	7y 2m-10y 8m	10y 9m	11m	9y 7m-13y
T ₁ -T ₂	10m	4m	6m-1y 6m	10m	2m	6m-1y 2m
T ₂ -T ₃	1y 3m	7m	6m-2y 5m	1y 3m	7m	6m-2y 5m

years after treatment. Maxillary growth was similar in both treated and control groups during another 2 years of posttreatment observation. No significant differences between treated and control groups in the sagittal and vertical position of the mandible were identified during the 4-year period after discontinuation of therapy.

McGill and McNamara³ evaluated postprotraction changes in patients with Class III malocclusion treated with a bonded acrylic-splint expander and a facemask. All patients wore either a 3-way sagittal appliance or a passive acrylic palatal plate as retention devices. During the 13.7-month posttreatment period, a decrease in the ANB angle was observed as a result of less than average maxillary growth and slightly more than expected mandibular growth. According to the results of the study by Macdonald et al,⁴ during a 2-year period after facemask therapy, the maxilla continued to grow anteriorly similar to the Class III controls, but less than the Class I controls. Postprotraction mandibular growth was equal for treatment and control groups. No active appliance was used in the posttreatment period.

Previous cephalometric and morphometric investigations with Class III untreated controls demonstrated that treatment of Class III malocclusion by means of maxillary expansion and protraction is more effective in the early than in the late mixed dentition.⁵⁻⁷ However, information about the possible role of treatment timing on posttreatment changes after active therapy for Class III malocclusion is lacking.

The aim of this study, therefore, is to evaluate treatment and posttreatment skeletal changes induced by orthopedic treatment of Class III malocclusion by means of a bonded acrylic-splint expander and facemask in the early mixed dentition and in the late mixed dentition.

SUBJECTS AND METHODS

Subjects

Treatment group. Records from 105 patients with Class III malocclusion treated with a bonded rapid

maxillary expander (RME) and facemask therapy were obtained from North American practitioners experienced in this type of treatment. The clinicians were asked to take cephalograms at the following time periods: pretreatment (T₁), within 1 month after RME and facemask removal (T₂), and at least 6 months later (T₃). Therefore, for each patient an active treatment period (T₁-T₂) and a posttreatment period (T₂-T₃) could be evaluated.

From this large sample, 29 subjects (15 females and 14 males) were selected for the treatment group on the basis of inclusionary criteria. Patients were included if they were of European American ancestry, if they presented for treatment either in the early mixed dentition (erupting permanent incisors and/or first permanent molars) or late mixed dentition (erupting permanent canines and/or premolars), and if they had the following Class III occlusal and skeletal signs: anterior crossbite, Class III deciduous or permanent canine relationship, mesial step deciduous molar relationship or Class III permanent molar relationship, and pretreatment Wits appraisal⁸ greater than or equal to -2 mm. Further, to be included in the study, the patients should not have worn any retention appliance during the posttreatment period (T₂-T₃).

The treated group was divided into 2 subgroups according to the stage of dentitional development. The early treatment group (ETG) comprised 16 subjects treated in the early mixed dentition; the late treatment group (LTG) included 13 subjects treated in the late mixed dentition. The mean ages of ETG at T₁, T₂, and T₃, mean duration of the ETG active treatment period, and mean duration of the ETG posttreatment period are reported in Table I.

Control samples. Control samples with untreated Class III malocclusion were selected from the files of the Department of Orthodontics of the University of Florence. These samples were used as comparison groups as they matched the treated groups as to race,

Table II. Mean age and age range for control groups at different observation times, and mean duration of observation intervals

	Control samples					
	Early control group 1 (n = 17)			Late control group 1 (n = 15)		
	Mean	SD	Min-Max	Mean	SD	Min-Max
T ₁	6y 5m	8m	5y 3m-7y 8m	9y 6m	1y 6m	8y-13y 1m
T ₂	8y 4m	1y 2m	6y 11m-10y 3m	11y 4m	1y 6m	8y 11m-14y 2m
T ₁ -T ₂	1y 11m	1y 2m	7m-4y 8m	1y 9m	10m	6m-4y
	Early control group 2 (n = 11)			Late control group 2 (n = 10)		
	Mean	SD	Min-Max	Mean	SD	Min-Max
	T ₂	7y 7m	7m	6y 10m-8y 4m	10y 3m	1y 5m
T ₃	8y 7m	8m	8y-10y	12y	1y 3m	10y 2m-14y 2m
T ₂ -T ₃	1y 10m	1y	7m-4y	1y 9m	10m	6m-4y

stage of dentitional development, Class III occlusal and skeletal signs, and gender.

The control samples comprised 4 groups of subjects: early control group 1 (ECG1); early control group 2 (ECG2); late control group 1 (LCG1); late control group 2 (LCG2). The control subjects were grouped according to both dentitional stage and the availability of serial cephalometric films during the observational period. ECG1 (17 subjects) and LCG1 (15 subjects) were used as control groups for the appraisal of the results of the active treatment period (T₁-T₂) in ETG and LTG, respectively. ECG2 (11 subjects) and LCG2 (10 subjects) were used as control groups for the appraisal of posttreatment changes (T₂-T₃) in ETG and LTG, respectively. The mean age of control samples at all observational phases and mean duration of the observation intervals (T₁-T₂ and T₂-T₃) are reported in Table II.

Cephalograms for each subject in all treatment and control groups at T₁, T₂, and T₃ were taken using a standardized protocol. The enlargement factors were similar among radiographic units (about 8%); thus, no correction was made for enlargement in the analysis of the films.

Treatment Protocol

The components of orthopedic face mask therapy in the treated group included a facemask (according to the design of Petit⁹), a bonded maxillary acrylic splint expander with vestibular hooks, and heavy elastics.¹⁰ The expansion screw of the bonded maxillary expander was activated once per day until the desired change in the transverse dimension was achieved (ie, the lingual cusps of the upper posterior teeth approximated the buccal cusps of the lower posterior teeth). Elastics of increasing force were used until a heavy orthopedic force (400 g) was delivered. The direction of elastic trac-

tion was forward and downward from the hooks on the bonded maxillary expander to the adjustable crossbar of the face mask, so that the elastics did not interfere with the function of the lips. The patients were instructed to wear the facemask at least 14 hours per day; the actual amount of wear for each patient was unknown.

None of the patients wore any skeletally based retention appliance (eg, FR-3 of Fränkel, chincup, mandibular retractor) during the posttreatment period.

Cephalometric Analysis

Cephalometric analysis for the assessment of both treatment results and posttreatment changes was based on a previously described reference system traced through craniofacial stable structures.^{11,12}

1. Stable basicranial line (SBL). This line is traced through the most superior point of the anterior wall of sella turcica at the junction with tuberculum sellae (point T¹³), and it is drawn tangent to lamina cribrosa of the ethmoid bone. These basicranial structures do not undergo remodeling after the age of 4 to 5 years.¹⁴
2. Vertical T (VertT). A line constructed perpendicular to SBL and passing through point T.

The cephalometric analysis was constructed with the following landmarks: A-point (A), B-point (B), prosthion (Pr), infradentale (Id), gnathion (Gn), menton (Me), gonial intersection (Goi), articulare (Ar), basion (Ba), condylion (Co), center of the condyle (Cs) (ie, a point equidistant from the anterior, posterior, and superior borders of the condyle head), pterygomaxillary fissure (Ptm), anterior nasal spine (ANS), and posterior nasal spine (PNS). The definitions of all these landmarks correspond to those of Björk,¹⁵ Ødegaard,¹⁶ and Riolo et al.¹⁷

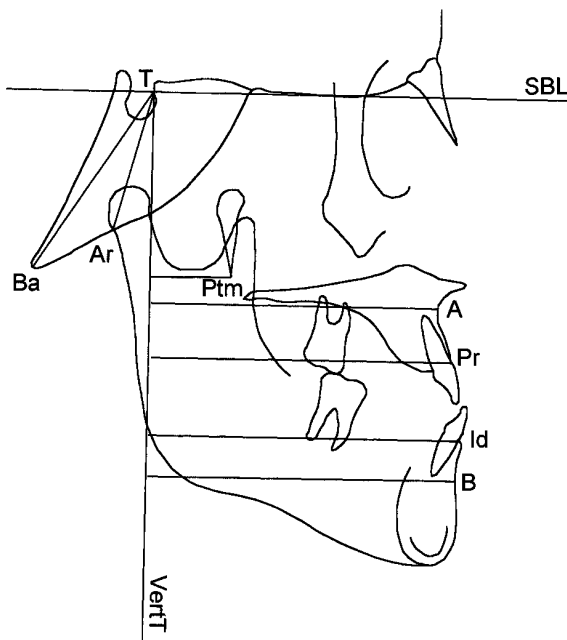


Fig 1. Linear measurements to assess sagittal relationships; angular measurements to assess cranial base angulation.

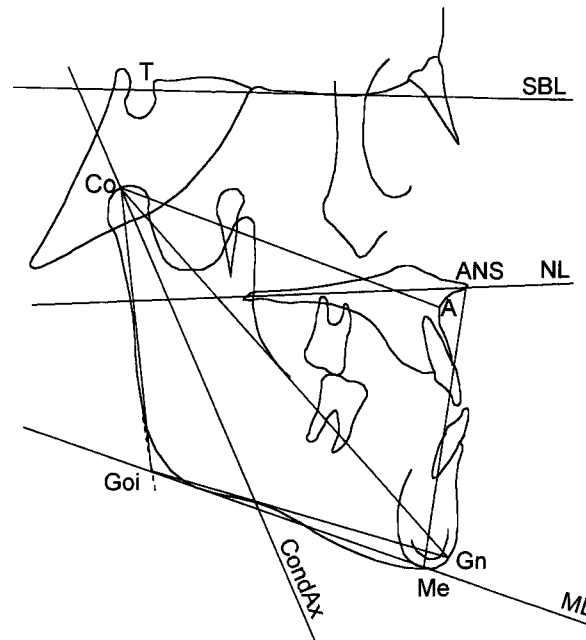


Fig 2. Linear and angular measurements to assess vertical relationships and condylar inclination; linear measurements to assess mandibular dimensions.

Linear measurements for the assessment of sagittal relationships (Fig 1): A-VertT, Ptm-VertT, Pr-VertT, Id-VertT, and B-VertT.

*Linear measurements for the assessment of mandibular dimensions*¹⁸ (Fig 2): Co-A, Co-Gn, Co-Goi, and Goi-Gn.

Angular measurements for the assessment of cranial base angulation (Fig 1): Ba-T-VertT and Ar-T-VertT.

Angular and linear measurements for the assessment of vertical relationships (Fig 2): mandibular line (ML)-SBL, nasal line (NL)-SBL, nasal line-mandibular line (NL-ML), gonial angle (Ar-Goi-Me), and ANS-Me.

Angular measurements for the assessment of condyle inclination (Fig 2): condylar axis (CondAx)-SBL, and CondAx-ML. The condylar axis is a line passing through condylion and point Cs.

The method error for the cephalometric measurements is reported elsewhere.⁵

Data Analysis

In order to assess significant differences between craniofacial starting forms at the time of the first observation, comparisons between treated and control groups at T₁ were performed (ETG at T₁ vs ECG1 at T₁; LTG at T₁ vs LCG1 at T₁). No significant differences for any of the cephalometric variables were found.

To overcome discrepancies in the observation periods, all differences were annualized. The effects of active treatment were assessed by contrasting craniofacial changes in the early treatment group (ETG) to those in early control group (ECG1). Similarly, the changes in late treatment group (LTG) were compared with those in late untreated group (LCG1). Posttreatment modifications after active therapy in ETG were compared to growth changes in ECG2, while posttreatment changes in LTG were compared to growth changes in LCG2. All comparisons were performed by means of nonparametric statistics for independent samples (Mann-Whitney U test, $P < .05$), and they were carried out with the Statistical Package for the Social Sciences (SPSS for Windows, ver. 8.0, SPSS, Inc., Chicago, Ill).

RESULTS

Effects of Active Treatment in the Early Treatment Group (T₁-T₂, Table III)

The early treatment group showed significantly greater increments in maxillary sagittal growth both at the skeletal (A-VertT) and dentoalveolar (Pr-VertT) levels. Midfacial length (Co-A) increments also were significantly larger in ETG. Significantly smaller increments for mandibular sagittal position (B-VertT), for total mandibular length (Co-Gn), and for the length of

Table III. Descriptive statistics and statistical comparison of annualized changes between early treatment group (active treatment changes) and early control group 1

Cephalometric measurements	Annualized differences T_2-T_1 Early treatment group (n = 16)					Annualized differences T_2-T_1 Early control group 1 (n = 17)					Mann-Whitney test	
	Mean	SD	Median	Maximum	Minimum	Mean	SD	Median	Maximum	Minimum	Z	P
	A-VertT (mm)	3.58	2.26	3.22	8.37	0.67	0.99	0.8	0.76	3.32	-0.08	-3.81
Co-A (mm)	3.59	1.60	3.36	6.54	1.48	2.44	1.41	2.11	5.54	0.39	-2.02	*
Ptm-VertT(mm)	0.64	1.54	0.33	5.09	-1.43	0.06	0.16	0.06	0.48	-0.3	-0.58	NS
Pr-VertT (mm)	4.14	2.43	3.53	9.78	1.10	1.51	0.91	1.25	3.99	0.36	-3.57	***
Id-VertT (mm)	-0.29	2.49	0.27	3.25	-6.19	1.54	1.19	1.22	5.19	0.31	-2.01	*
B-VertT (mm)	-1.13	2.27	-1.18	3.07	-6.03	1.98	1.33	1.52	5.04	0.38	-3.78	***
Co-Gn (mm)	0.95	1.93	0.81	5.16	-1.96	4.49	2.2	3.68	10.33	2.23	-3.99	***
Co-Goi (mm)	1.46	1.33	1.42	3.49	-0.21	1.33	1.01	1.51	3.25	-0.99	-0.14	NS
Goi-Gn (mm)	0.39	1.70	0.42	2.84	-2.91	2.99	1.66	2.63	6.35	0.66	-3.60	***
Ba-T-VertT (°)	-0.94	2.06	-0.81	1.83	-5.03	-0.11	0.55	-0.18	1.48	0.83	-1.04	NS
Ar-T-VertT (°)	0.37	3.79	0.06	11.38	-5.25	0.49	0.89	0.46	1.96	-1.05	-1.04	NS
ML-SBL (°)	-0.25	1.86	0.11	2.21	-4.74	-0.07	0.72	0.05	1.25	-1.55	-0.25	NS
NL-SBL (°)	-1.31	2.04	-1.22	1.78	-4.64	-0.23	0.73	-0.09	1.36	-1.96	-1.66	NS
NL-ML (°)	1.06	2.30	0.77	5.19	-3.44	0.15	0.93	0.41	1.45	-2.01	-1.08	NS
Ar-Goi-Me (°)	-1.32	2.50	-0.40	1.89	-8.11	-0.25	1.19	-0.21	2.59	-2.06	-0.97	NS
ANS-Me (mm)	2.63	2.46	2.71	7.50	-1.67	1.66	0.66	1.73	2.81	0.46	-1.11	NS
CondAx-SBL (°)	4.85	8.79	1.60	26.18	-6.60	-3.73	2.92	-3.56	0.55	-12.02	-3.71	***
CondAx-ML (°)	-1.72	2.29	-1.45	1.65	-7.67	3.65	3.09	2.83	12.46	-1.38	-4.47	***

* $P < .05$; ** $P < .01$; *** $P < .001$

NS, Not significant.

the mandibular body (Goi-Gn) were assessed in ETG and compared with those in ECG1. The direction of condylar growth as revealed by the change in inclination of the condylar axis in relation to both cranial base (CondAx-SBL) and the mandibular line (CondAx-ML) was significantly more upward and forward in ETG.

Posttreatment Changes in the Early Treatment Group (T_2-T_3 , Table IV)

Posttreatment increments in the anteroposterior position of the maxilla (A-VertT), in dentoalveolar maxillary protrusion (Pr-VertT), and in midfacial length (Co-A) were significantly smaller in ETG than in ECG2. Increments in lower anterior facial height (ANS-Me) were also significantly smaller in ETG during the posttreatment period.

Effects of Active Treatment in the Late Treatment Group (T_1-T_2 , Table V)

Treatment performed in the late mixed dentition led to significantly smaller increments in the amount of mandibular growth along total mandibular length (Co-Gn), associated with significantly smaller increments in mandibular skeletal (B-VertT) and dentoalveolar (Id-VertT) protrusion.

Increments in the inclination of the mandibular line in relation to cranial base (ML-SBL) and to nasal line

(NL-ML) were significantly greater in LTG when compared with corresponding controls (LCG1). A significantly larger increase in lower anterior facial height (ANS-Me) was recorded in LTG as well. Measurements for the inclination of the condylar axis in relation both to the cranial base (CondAx-SBL) and to the mandibular line (CondAx-ML) showed a significantly more upward and forward direction of condylar growth in LTG when compared with LCG1.

Posttreatment Changes in the Late Treatment Group (T_2-T_3 , Table VI)

Significantly greater increments in the anteroposterior position of mandibular base (B-VertT) and the mandibular dentition (Id-VertT) were found in LTG when compared with LCG2 during the posttreatment period.

DISCUSSION

The present investigation analyzed treatment and posttreatment changes after orthopedic therapy of Class III malocclusion by means of a bonded rapid maxillary expander and a facemask in the early and late mixed dentitions. The role of treatment timing in relation to skeletal and dentoalveolar modifications associated with this type of treatment protocol was assessed. Groups of children with untreated Class III malocclusions were used as control samples to evalu-

Table IV. Descriptive statistics and statistical comparison of annualized changes between early treatment group (post-treatment changes) and early control group 2

Cephalometric measurements	Annualized differences T_3-T_2 Early treatment group (n = 16)					Annualized differences T_3-T_2 Early control group 2 (n = 11)					Mann-Whitney test	
	Mean	SD	Median	Maximum	Minimum	Mean	SD	Median	Maximum	Minimum	Z	P
A-VertT (mm)	0.46	2.15	0.64	6.43	-2.81	1.37	0.87	0.95	3.32	0.60	-1.97	*
Co-A (mm)	0.32	1.39	0.74	2.44	-2.30	1.27	1.30	1.79	5.53	1.17	-2.51	*
Ptm-VertT (mm)	0.44	2.10	-0.25	7.22	-1.55	0.14	0.15	0.13	0.56	0.00	-1.18	NS
Pr-VertT (mm)	1.03	2.08	0.79	6.43	-1.38	1.81	1.02	1.51	3.99	0.74	-2.02	*
Id-VertT (mm)	2.73	3.97	2.21	12.26	-1.62	2.25	1.41	2.09	5.19	0.32	0.00	NS
B-VertT (mm)	2.45	3.89	2.26	12.12	-1.97	2.48	1.45	2.08	5.04	0.38	-0.39	NS
Co-Gn (mm)	3.01	1.53	3.41	5.41	-0.59	4.62	2.24	3.68	10.34	2.32	-1.62	NS
Co-Goi (mm)	1.16	1.52	1.37	4.83	-2.00	1.16	1.43	1.13	4.61	-0.99	-0.34	NS
Goi-Gn (mm)	2.41	2.06	2.74	6.19	-1.82	3.20	2.08	2.55	7.23	0.66	-0.35	NS
Ba-T-VertT (°)	-0.32	3.86	0.27	8.56	-8.46	-0.41	0.45	-0.29	0.22	-1.41	-1.23	NS
Ar-T-VertT (°)	-1.18	3.30	-0.66	3.36	-8.64	0.14	0.86	-0.16	1.33	-1.04	-1.04	NS
ML-SBL (°)	-0.12	2.36	-0.10	5.64	-5.32	-0.30	0.65	-0.18	0.49	-1.44	-0.79	NS
NL-SBL (°)	0.45	2.16	0.69	3.94	-5.19	-0.64	0.25	-0.55	-0.28	-1.09	-1.58	NS
NL-ML (°)	-0.58	1.81	-0.36	1.70	-4.29	0.34	0.71	0.25	1.45	-0.97	-1.18	NS
Ar-Goi-Me (°)	-0.30	2.20	0.02	2.98	-6.45	-0.69	1.24	-0.81	1.05	-2.95	-0.98	NS
ANS-Me (mm)	0.48	1.46	1.10	2.14	-2.48	1.66	0.86	1.87	2.58	-0.32	-2.37	*
CondAx-SBL (°)	0.52	5.38	0.19	11.66	-9.04	-2.72	4.16	-2.99	4.77	-12.02	-1.63	NS
CondAx-ML (°)	-0.08	1.79	0.15	2.60	-3.39	2.42	4.51	1.72	12.45	-5.38	-1.92	NS

* $P < .05$

NS, Not significant.

Table V. Descriptive statistics and statistical comparison of annualized changes between late treatment group (active treatment changes) and late control group 1

Cephalometric measurements	Annualized differences T_2-T_1 Late treatment group (n = 13)					Annualized differences T_2-T_1 Late control group 1 (n = 15)					Mann-Whitney test	
	Mean	SD	Median	Maximum	Minimum	Mean	SD	Median	Maximum	Minimum	Z	P
A-VertT (mm)	1.89	2.27	1.78	6.47	-1.29	1.17	0.91	1.17	2.98	-0.63	-1.16	NS
Co-A (mm)	2.44	2.03	2.79	5.88	-2.05	2.18	1.24	1.78	5.5	0.79	-0.67	NS
Ptm-VertT (mm)	0.22	1.54	0.15	2.88	-1.82	0.02	0.39	0.08	0.56	-1	-0.21	NS
Pr-VertT (mm)	2.37	2.55	1.79	8.12	-1.72	1.3	0.89	1.38	3.13	-0.77	-1.17	NS
Id-VertT (mm)	-1.41	3.02	-1.45	2.84	-7.85	1.97	1.16	1.98	4.38	-0.13	-3.15	**
B-VertT (mm)	-1.92	3.73	-1.50	4.27	-9.37	2.06	1.77	2.08	5.4	-0.76	-3.02	**
Co-Gn (mm)	1.70	1.74	1.51	5.08	-1.42	4.33	2.41	3.65	10.94	1.59	-3.11	**
Co-Goi (mm)	1.01	1.89	0.60	4.59	-1.50	1.97	1.77	1.28	5.1	0.14	-1.31	NS
Goi-Gn (mm)	1.01	2.13	1.07	3.84	-3.07	3.07	2.3	2.42	8.38	-0.16	-1.96	NS
Ba-T-VertT (°)	0.73	2.31	0.80	3.93	-3.96	-0.26	0.8	-0.33	2	-1.41	-1.86	NS
Ar-T-VertT (°)	1.22	2.04	1.63	4.30	-2.37	0.23	0.74	0.25	1.89	-0.84	-1.08	NS
ML-SBL (°)	1.96	2.23	2.01	6.83	-1.89	-0.27	0.84	-0.6	1.98	-1.09	-2.88	**
NL-SBL (°)	-0.69	2.61	-0.29	3.44	-5.62	-0.38	0.74	-0.55	1.22	-1.63	-0.21	NS
NL-ML (°)	2.64	3.35	2.81	11.57	-1.59	0.11	0.92	-0.2	2.58	-0.1	-2.65	**
Ar-Goi-Me (°)	-0.28	1.83	-0.04	2.50	-3.67	-0.74	1.41	-0.52	1.67	-3.24	-0.67	NS
ANS-Me (mm)	3.60	3.16	3.58	11.95	-0.73	1.66	1.17	1.27	3.64	-0.32	-2.28	*
CondAx-SBL (°)	5.09	6.05	3.77	16.15	-2.18	-3.38	6.34	-2.99	4.77	-23.54	-3.52	***
CondAx-ML (°)	-0.48	1.82	0.54	1.53	-3.91	3.11	6.56	2.21	23.1	-5.38	-2.23	*

* $P < .05$; ** $P < .01$; *** $P < .001$

NS, Not significant.

ate cephalometric changes both during and after the active treatment period.

In the group treated in the early mixed dentition, RME and facemask therapy was able to produce sig-

nificant favorable adaptations in both the maxilla and mandible. These data confirm the results of a previous investigation.⁵ The increase in sagittal growth of the maxilla was approximately 4 times greater in the early

Table VI. Descriptive statistics and statistical comparison of annualized changes between late treatment group (post-treatment changes) and late control group 2

Cephalometric measurements	Annualized differences T_3-T_2 Late treatment group (n = 13)					Annualized differences T_3-T_2 Late control group 2 (n = 10)					Mann-Whitney test	
	Mean	SD	Median	Maximum	Minimum	Mean	SD	Median	Maximum	Minimum	Z	P
A-VertT (mm)	1.15	1.54	1.58	3.13	-2.78	1.01	0.99	1.15	2.98	-0.63	-0.68	NS
Co-A (mm)	1.21	1.27	1.40	3.34	-0.74	1.44	1.44	2.01	5.50	0.79	-0.80	NS
Ptm-VertT (mm)	-0.28	1.26	-0.04	1.10	-3.34	-0.06	0.44	0.06	0.55	-1.00	0.00	NS
Pr-VertT (mm)	1.36	1.34	1.25	2.95	-1.56	1.09	0.86	1.19	2.47	-0.77	-0.49	NS
Id-VertT (mm)	2.95	2.34	3.22	6.94	-1.97	1.62	1.12	1.60	3.98	-0.13	-1.98	*
B-VertT (mm)	3.25	3.10	3.71	7.65	-4.42	1.59	1.88	1.24	5.40	-0.76	-1.98	*
Co-Gn (mm)	3.30	1.49	3.60	5.34	0.91	4.37	2.83	3.56	10.94	1.59	-0.49	NS
Co-Goi (mm)	1.44	2.50	1.80	6.80	-4.76	2.27	1.74	1.66	5.08	0.40	-0.62	NS
Goi-Gn (mm)	1.96	2.68	1.65	9.43	-2.62	2.71	2.40	2.07	8.38	-0.16	-0.62	NS
Ba-T-VertT (°)	-0.31	1.98	-0.34	3.39	-3.02	-0.10	0.87	-0.30	2.00	-0.94	-0.31	NS
Ar-T-VertT (°)	-0.88	2.91	-1.17	5.23	-6.39	0.47	0.68	0.45	1.89	-0.85	-1.55	NS
ML-SBL (°)	-0.65	1.59	-1.28	2.49	-2.66	-0.08	0.97	-0.35	1.98	-0.97	-1.36	NS
NL-SBL (°)	-0.14	1.60	-0.13	1.58	-4.01	-0.24	0.88	-0.13	1.22	-1.63	-0.55	NS
NL-ML (°)	-0.51	1.82	-0.81	2.73	-3.87	0.16	1.13	-0.22	2.58	-1.00	-0.87	NS
Ar-Goi-Me (°)	-0.67	2.43	0.31	5.52	-3.65	-0.42	1.41	-0.28	1.67	-3.24	-0.93	NS
ANS-Me (mm)	0.91	1.39	0.63	4.60	-0.76	1.74	1.20	1.25	3.64	0.42	-1.67	NS
CondAx-SBL (°)	-1.08	3.88	-1.40	6.29	-7.20	-5.00	7.10	-3.53	2.52	-23.54	-1.55	NS
CondAx-ML (°)	1.10	2.18	0.41	4.95	-1.55	4.91	7.24	3.06	23.1	-3.50	-1.67	NS

* $P < .05$

NS, Not significant.

treatment group than in the controls. The increase in the anteroposterior position of the maxillary dentition in early treatment subjects reflected the amount of sagittal skeletal change in the maxilla. No significant modification in maxillary measurements was found in the group treated in the late mixed dentition. The amount of supplementary sagittal growth of the maxilla in the late treatment group when compared with Class III controls was minimal.

Both early and late treatments induced significant favorable changes in mandibular sagittal position and in the amount and direction of mandibular growth. The association of smaller increments in total mandibular length with a more forward and upward direction of condylar growth (anterior morphogenetic rotation¹⁹) in both treated groups confirms previous observations that showed the efficiency of this mechanism in controlling mandibular growth in Class III patients.

As for vertical measurements, treatment in the early mixed dentition did not produce any significant change, whereas treatment in the late mixed dentition was associated with a backward rotation of the mandibular plane both in relation to the cranial base and to the palatal plane. Significantly greater increments in lower anterior facial height also were found in this group.

The results of the present study differ from those reported by Baik,²⁰ who was unable to find any signif-

icant difference in treatment outcome in 3 age groups of Class III subjects treated by means of RME and face mask therapy. However, the Baik study did not include any comparison with the growth changes in a control group of untreated subjects. In another investigation,²¹ the same treatment protocol appeared to induce more favorable effects in younger age groups (4 to 7 and 7 to 10 years) when compared with an older age group (10 to 14 years).

With regard to craniofacial modifications during the posttreatment period, the early treatment group showed smaller increments in the sagittal position of the maxillary base and dentition when compared with corresponding controls. Similar data were found for the measurement of midfacial length. Lower anterior facial height also exhibited smaller posttreatment increments in the early treatment group when compared with controls. The group treated in the late mixed dentition presented with significantly greater increments in the anteroposterior position of the mandibular base and of the mandibular dentition in the posttreatment period.

No other cephalometric variables revealed any significant difference in treated groups when compared with respective Class III controls during the posttreatment period. The clinical significance of these results is that a Class III craniofacial growth pattern is clearly re-established after orthopedic treatment of the maloc-

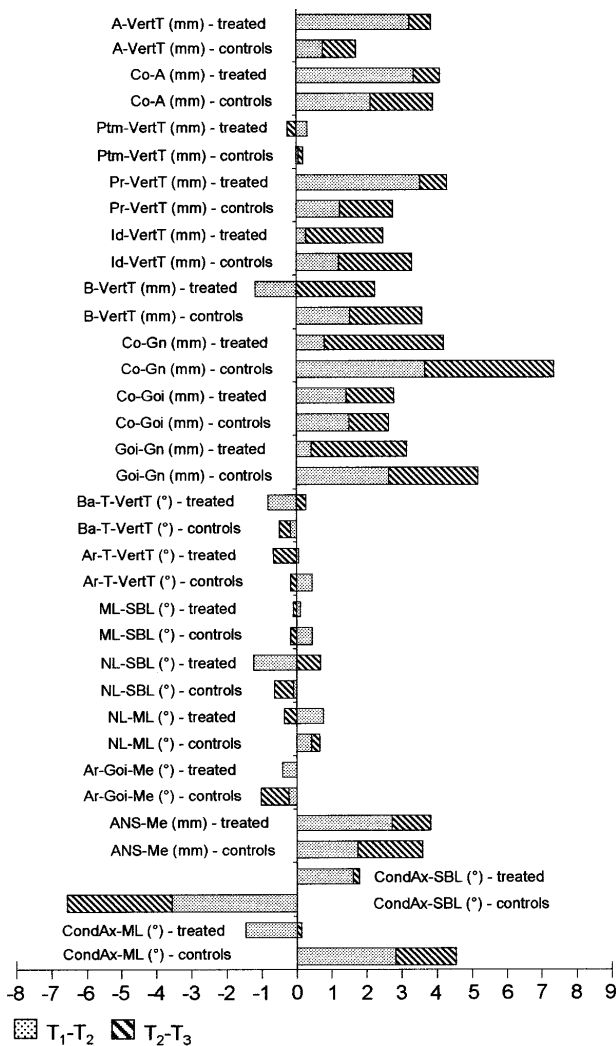


Fig 3. Combined active treatment and posttreatment changes in early treatment groups.

clusion, in agreement with previously published data regarding posttreatment modifications after maxillary expansion and protraction.¹⁻⁴

The significant posttreatment changes in both treated groups have to be interpreted as relapse after active treatment. In fact, because Class III subjects show a different pattern of skeletal growth when compared with normal Class I subjects,^{4,12} posttreatment changes can be defined as “relapse” only when growth modifications in treated subjects are more unfavorable than in untreated Class III subjects in a matched time interval. In the present study, the creation of different treated and control groups according to the stage of dentitional development allowed for the identification of posttreatment changes in relation to different treatment timing. Relapse tendency in early treatment sub-

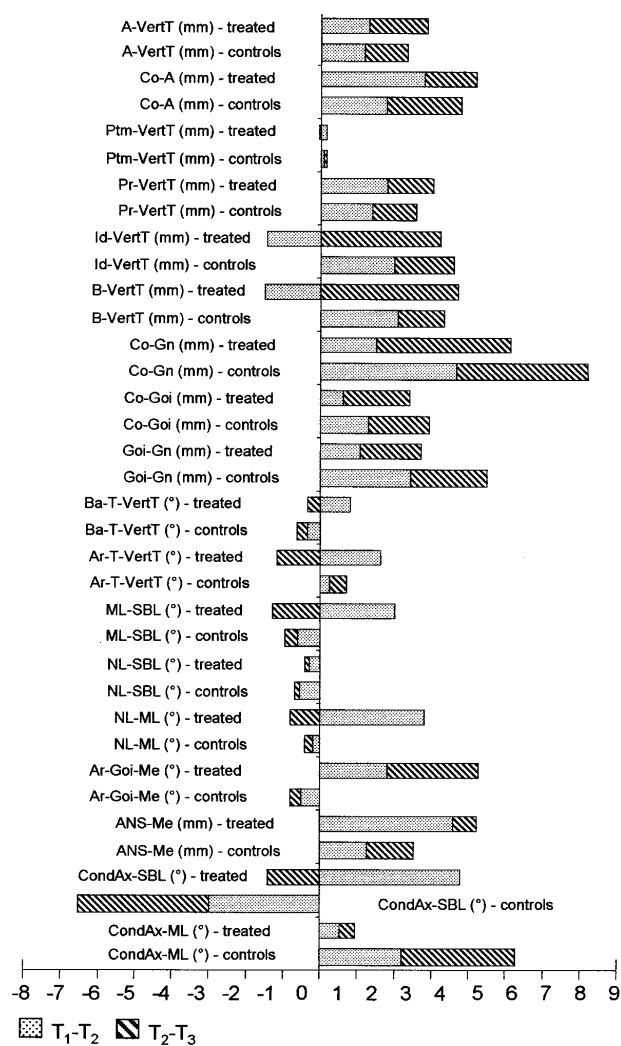


Fig 4. Combined active treatment and posttreatment changes in late treatment groups.

jects primarily affected the maxillary region, whereas late treatment subjects exhibited a significant rebound in mandibular sagittal position.

It also should be emphasized that none of the patients in either early or late groups wore any retention appliance used for further Class III correction after active treatment of the skeletal disharmony. Therefore, the present data correspond to the maximal amount of unfavorable changes that can be anticipated 1 year after discontinuation of active orthopedic treatment of Class III malocclusion.

For a further appraisal of the role of treatment timing on the effects of maxillary expansion and protraction therapy, outcomes of both active treatment and posttreatment periods must be combined in order to define an “overall treatment effect” of orthopedic

Class III treatment in both early and late treatment groups (Figs 3 and 4). From the start of treatment (T_1) through the end of the posttreatment period (T_3), for instance, the amount of supplementary maxillary sagittal growth (A-VertT) in the early treatment group in relation to untreated controls was 2.3 mm; it was just 0.5 mm in the late treatment group. The overall restraining effect on mandibular protrusion (B-VertT) induced by treatment with respect to controls was 2.5 mm in early treatment subjects and about 1 mm in late treatment subjects. With regard to overall treatment results on mandibular growth, restraining effect on total mandibular length (Co-Gn) was about 3 mm in the group treated in the early mixed dentition, whereas it was about 2 mm in the group treated in the late mixed dentition.

In association with the above finding, the direction of condylar growth from T_1 to T_3 was 5.7° more upward and forward than in corresponding controls in the early treatment group and 4.3° in the late treatment group. As for overall skeletal alterations in the vertical plane, early treatment left the intermaxillary vertical relationships practically unchanged, whereas treatment in the late mixed dentition induced a backward rotation of the mandible that led to an opening of the intermaxillary angle ML-NL of about 2° in association with an increase in lower anterior facial height of about 2 mm. Aggregate data deriving from these observations provide additional evidence⁵ that treatment of Class III skeletal disharmony in the early mixed dentition leads to more favorable craniofacial effects than treatment in the late mixed dentition, even when a posttreatment period is included. Due to the posttreatment re-establishment of growth characteristics pertaining to Class III skeletal disharmony, correction of the malocclusion depends fundamentally on the amount of beneficial changes that can be obtained during active therapy. Treatment of Class III malocclusion in the early mixed dentition is more efficient in this respect.

The question remains whether the quantity of both supplementary growth in the maxilla and restraining effect on the growth of the mandible in Class III patients treated during the early developmental phases is able to withstand the outcomes of subsequent growth, especially during the pubertal growth spurt. In the present study posttreatment changes refer to "immediate" posttreatment modifications. A longer observation period is needed in order to understand more fully the clinical implications associated with differential timing for orthopedic treatment of Class III malocclusion. Further, the possible role of an efficient retention protocol in limiting relapse tendency in both the transverse and sagittal planes should be investigated as well.

CONCLUSIONS

The main findings of the present cephalometric study on treatment and posttreatment craniofacial alterations related to orthopedic therapy of Class III malocclusion by means of maxillary expansion and protraction in the early and late mixed dentitions are:

1. A significant increase in sagittal growth of the maxilla can be obtained only when treatment is performed in the early mixed dentition. Both early and late treatment of the malocclusion are able to induce a restraining effect on mandibular growth associated with a more upward and forward direction of condylar growth.
2. A backward positional rotation of the mandible associated with an increase in lower anterior facial height is observed in Class III patients treated in the late mixed dentition.
3. A Class III craniofacial growth pattern is re-established during 1 year of posttreatment observation in the absence of any skeletally based retention appliance. A significant relapse tendency affects the sagittal growth of the maxilla in the subjects who were treated early and the sagittal position of the mandible in the subjects treated later.
4. When considering combined outcomes of both active treatment and posttreatment periods, orthopedic treatment of Class III malocclusion in the early mixed dentition appears to induce more favorable overall craniofacial changes than treatment in the late mixed dentition.

We acknowledge the efforts of Dr Jean S. McGill in assembling the records of the treated sample. We also thank the clinicians who provided treatment cases for the study: Lawrence E. Galley, Robert Giering, Richard Meyer, Patrick J. Nolan, Gary L. Pool, Paul W. Reed, Kenneth M. Spain, Anthony R. Tesone, and James Thompson.

REFERENCES

1. Shanker S, Ngan P, Wade D, Beck M, Yiu C, Hägg U, Wei SH. Cephalometric A point changes during and after maxillary protraction and expansion. *Am J Orthod Dentofacial Orthop* 1996;110:423-30.
2. Ngan P, Hägg U, Yiu C, Wei SH. Treatment response and long-term dentofacial adaptations to maxillary expansion and protraction. *Semin Orthod* 1997;3:255-64.
3. McGill JS, McNamara JA Jr. Treatment and posttreatment effects of rapid maxillary expansion and facial mask therapy. In: McNamara JA Jr, ed. Growth modification: what works, what doesn't, and why. Monograph No 35. Craniofacial Growth Series. Ann Arbor: Center for Human Growth and Development, University of Michigan; 1999. p. 123-52.

4. Macdonald KE, Kapust AJ, Turley PK. Cephalometric changes after correction of Class III malocclusion with maxillary expansion/face-mask therapy. *Am J Orthod Dentofacial Orthop* 1999;116:13-24.
5. Baccetti T, McGill JS, Franchi L, McNamara JA Jr, Tollaro I. Skeletal effects of early treatment of Class III malocclusion with maxillary expansion and face-mask therapy. *Am J Orthod Dentofacial Orthop* 1998;113:333-43.
6. Franchi L, Baccetti T, McNamara JA Jr. Shape-coordinate analysis induced by rapid maxillary expansion and facial mask therapy. *Am J Orthod Dentofacial Orthop* 1998;114:418-26.
7. Baccetti T, Franchi L. Updating cephalometrics through morphometrics: thin-plate spline analysis of craniofacial growth/treatment changes. In: McNamara JA Jr, ed. *Growth modification: what works, what doesn't, and why*. Monograph No 35. Craniofacial Growth Series. Ann Arbor: Center for Human Growth and Development, University of Michigan; 1999. p. 257-73.
8. Jacobson A. Application of the "Wits" appraisal. *Am J Orthod* 1976;70:179-89.
9. Petit HP. Adaptation following accelerated facial mask therapy. In: McNamara JA Jr, Ribbens KA, Howe RP, eds. *Clinical alterations of the growing face*. Monograph No 14. Craniofacial Growth Series. Ann Arbor: Center for Human Growth and Development, The University of Michigan; 1983.
10. McNamara JA Jr, Brudon WL. Orthodontic and orthopedic treatment in the mixed dentition. Ann Arbor: Needham Press; 1993.
11. Tollaro I, Baccetti T, Franchi L. Mandibular skeletal changes induced by early functional treatment of Class III malocclusion: a superimposition study. *Am J Orthod Dentofacial Orthop* 1995;108:525-32.
12. Tollaro I, Baccetti T, Franchi L. Craniofacial changes induced by early functional treatment of Class III malocclusion. *Am J Orthod Dentofacial Orthop* 1996;109:310-8.
13. Viazis AD. The cranial base triangle. *J Clin Orthod* 1991;25:565-70.
14. Melsen B. The cranial base. *Acta Odontol Scand* 1974;32:Suppl62.
15. Björk A. The face in profile. *Sven Tandläk Tidsskr* 1947;40:Suppl.
16. Ødegaard I. Growth of the mandible studied with the aid of metal implants. *Am J Orthod* 1970;57:45-57.
17. Riolo ML, Moyers RE, McNamara JA Jr, Hunter WS. An atlas of craniofacial growth: cephalometric standards from The University School Growth Study, The University of Michigan. Monograph No 2. Craniofacial Growth Series. Ann Arbor: Center for Human Growth and Development, The University of Michigan; 1974.
18. McNamara JA Jr. A method of cephalometric evaluation. *Am J Orthod* 1984;86:449-69.
19. Lavergne J, Gasson N. Operational definitions of mandibular morphogenetic and positional rotations. *Scand J Dent Res* 1977;85:185-92.
20. Baik HS. Clinical results of the maxillary protraction in Korean children. *Am J Orthod Dentofacial Orthop* 1995;108:583-92.
21. Kapust A, Turley PK, Sinclair PM. Cephalometric effects of face mask/expansion therapy in Class III children: a comparison of three age groups. *Am J Orthod Dentofacial Orthop* 1998;113:204-12.

AVAILABILITY OF JOURNAL BACK ISSUES

As a service to our subscribers, copies of back issues of the *American Journal of Orthodontics and Dentofacial Orthopedics* for the preceding 5 years are maintained and are available for purchase from the publisher, Mosby, Inc, at a cost of \$13.00 per issue. The following quantity discounts are available: 25% off on quantities of 12 to 23, and one third off on quantities of 24 or more. Please write to Mosby, Subscription Customer Service, 6277 Sea Harbor Dr, Orlando, FL 32887, or call 800-654-2452 or 407-345-4000 for information on availability of particular issues. If unavailable from the publisher, photocopies of complete issues are available from Bell & Howell Information and Learning, 300 N. Zeeb Rd, Ann Arbor, MI 48106 (734)761-4700 or (800)521-0600.