

Ordinary Orthodontics: Starting with the End in Mind

James A. McNamara, Jr, DDS, PhD¹

Aim: "The opportunity of greatness lies in doing ordinary things extraordinarily well." That anonymous quote summarizes the purpose of this article, that is to discuss some of the "little things" dealing with the management of day-to-day orthodontic therapy that can not only affect the outcome of treatment, but can also make treatment more efficient and effective. **Methods:** This article considers various aspects of routine orthodontics, including appliance selection, band and bond placement, and archwire sequencing. The importance of proper bracket positioning, as well as the use of the transpalatal arch and the utility arch as routine parts of orthodontic mechanics is stressed. It also is extremely important for the clinician to have a clear vision of the goals that he or she wants to reach at the end of routine orthodontic treatment, and a general sequence of treatment is presented. **Conclusions:** It is hoped that some of the details described here as "ordinary orthodontics" will contribute to the improvement of fixed appliance therapy as practiced on a daily basis. *World J Orthod* 2000;1:45-54.

One of the most popular self-help books in the United States today is *The Seven Habits of Highly Effective People* by Stephen R. Covey.¹ In this best seller, Covey presents a principle-centered approach for solving personal and professional problems. One of his admonitions is to "begin with the end in mind." According to Covey, "To begin with the end in mind means to start with a clear understanding of your destination. It means to know where you're going so that you better understand where you are now and so that the steps that you take are always in the right direction."

Covey's approach to life in general can be directly applied to routine orthodontic treatment with fixed

appliances, in that the clinician should have a clear understanding of the sequence of events that will lead to an excellent clinical result. A personal examination of 30 years of transfer cases seen in private practice, however, reveals that not all clinicians share the same vision as to the sequence of events that should occur, even in relatively routine treatments. Nor do all clinicians prepare a patient for fixed appliance therapy in the same manner, as is evidenced by the wide variation observed in band and bond positions. This variation in bracket position occurs so frequently that, when accepting a transfer patient, many clinicians simply remove the existing appliances and replace them not only with their own specific prescription, but also place the brackets in position according to their own preference. Radical changes in treatment plan often occur as well. Most times, the details of appliance manipulation are as important as the original diagnosis and treatment plan in achieving an excellent orthodontic result. This article discusses many of those details.

¹ Thomas M. and Doris Graber Endowed Professor of Dentistry, Department of Orthodontics and Pediatric Dentistry, School of Dentistry; Professor of Cell and Developmental Biology, School of Medicine; and Research Scientist, Center for Human Growth and Development, The University of Michigan, Ann Arbor, Michigan. Private Practice of Orthodontics, Ann Arbor, Michigan, USA.

REPRINT REQUESTS/CORRESPONDENCE

Dr James A. McNamara, Department of Orthodontics and Pediatric Dentistry, School of Dentistry, University of Michigan, Ann Arbor, MI 48109-1078, USA. Fax: 734-763-8100. E-mail: mcnamara@umich.edu

APPLIANCE SELECTION

For the purpose of this paper, a basic approach to the treatment of relatively straightforward malocclu-

sions will be described. For example, the author routinely uses preadjusted appliances (Fig 1) rather than standard or neutral (ie, zero torque, zero angulation) edgewise appliances during comprehensive orthodontic therapy and recommends using the non-extraction Roth prescription of brackets when selecting a specific brand of appliance. This prescription for torque and angulation that is built into each bracket has proven satisfactory in the author's practice for nearly 2 decades.

It has been the practice's choice to use brackets with a 0.018-inch slot, although a 0.022-inch slot also can be effective. The introduction of memory wires that have low force values over a wide range of activation makes the difference in slot size less important than it was 2 or 3 decades ago. The primary reason for selecting a 0.018-inch slot is the ability to use 0.016 × 0.022-inch chrome-cobalt wires in the fabrication of utility arches.² The wire size is much easier to manipulate clinically than the 0.019 × 0.019-inch chrome-cobalt wire that is recommended for utility arch construction with a 0.022-inch slot appliance.

When selecting molar bands, it is important that an auxiliary tube is present on the brackets of both the upper and lower first molar bands (Fig 1). As utility arches can be used at virtually any point in treatment, it is essential that these auxiliary tubes be available.

The incorporation of ball hooks on the canine and premolar brackets (Fig 1) also is recommended. These ball hooks are available when intra- or inter-maxillary elastics are used. Care must be taken, however, in the fabrication of utility arches, so that the vestibular extensions of the arch do not contact the ball hooks.

GENERAL SEQUENCE OF TREATMENT

Although no two patients are treated precisely the same way, the approach to fixed appliance therapy used in the author's practice typically follows a prescribed sequence. In instances of significant Class II occlusal relationships, additional appliances (eg, Pendulum,³ Herbst,⁴ Twin block,⁵ Wilson distalizing arch⁶) are used. For the purpose of the following discussion, however, only minor sagittal occlusal problems exist.

Resolution of transverse discrepancies

As has been described elsewhere,^{7,8} a major factor in a surprising percentage of malocclusions is an underlying transverse discrepancy of the maxilla. If such a condition exists, rapid maxillary expansion

(RME) is used to correct both posterior and anterior crossbites as well as to increase arch space in mild to moderate tooth-size/arch-size discrepancy patients. RME is also used to "broaden the smile" in patients with a narrow maxilla and possibly to improve nasal airflow. In any event, transverse problems are always addressed prior to routine fixed appliance treatment.

Leveling and aligning

The initial leveling of the dental arch requires the application of light, continuous forces over relatively long distances. Thus, the selection of wires with adequate strength, springiness, and range is important. Round wires are usually preferred, so that unnecessary and undesirable root movement of the involved teeth is avoided whenever possible. Round wires are more flexible and are engaged more easily in the brackets. In some situations in which torque control is critical, however, rectangular copper NiTi wires are used as an initial leveling wire.

In instances of severely rotated teeth, we usually place a 0.0175-inch stainless steel coaxial wire or a 0.014-inch nickel titanium wire for initial leveling and alignment. A 0.016-inch NiTi wire, an archwire that may be used as the first leveling wire in less-rotated cases, usually follows the initial wire. In the later phase of initial leveling and alignment, a 0.016 × 0.022-inch rectangular NiTi wire is commonly used to begin adding appropriate root torque.

During this early phase of fixed appliance treatment, a soldered transpalatal arch is activated sequentially to produce distal molar rotation and buccal root torque.⁹ These activations, combined with appropriate placement of brackets on the maxillary canines and premolars (to be discussed later) should result in spontaneous improvement in occlusal relationship. A slight opening of space anterior to the maxillary canines frequently occurs (Fig 2). Thus, the upper archwire is secured to the brackets by way of "open" elastomeric chain from canine to molar bilaterally and across the 4 maxillary incisors.

When elastomeric chain is used segmentally, only the more proximal wing of the terminal bracket is incorporated into the chain. For example, when connecting the chain from the maxillary canine to the hook on the maxillary first molar, the chain is attached to both premolar brackets, but only to the distal wing of the canine bracket; the mesial wing is secured with a single elastomeric tie. This technique of attachment prevents the unwanted rotation of the canine from occurring. Similarly, the 4 incisors are connected by chaining from the mesial wing of 1

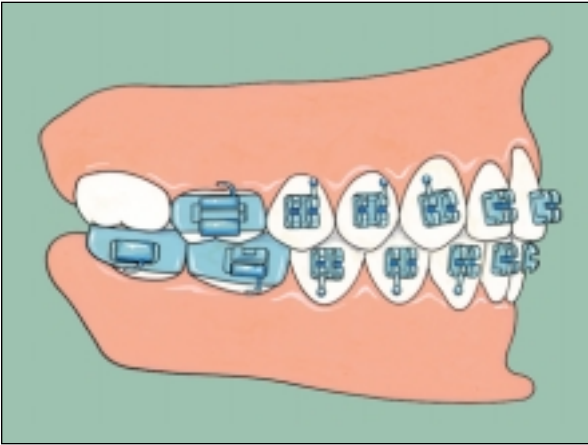


Fig 1 Typical bonds and bands used during fixed appliance therapy.

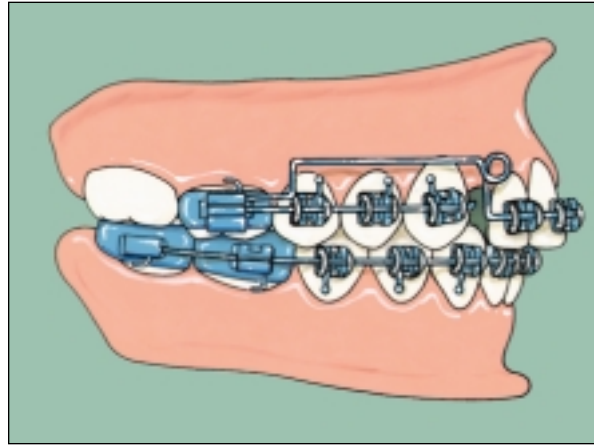


Fig 2 Distal rotation of the maxillary premolars and first molars typically produces small spaces distal to the maxillary lateral incisors. A retraction utility arch (shown before activation) can be used to retract the maxillary anterior teeth and close the spaces.

maxillary lateral incisor, around both central incisor brackets, and then around the mesial wing of the bracket on the other incisor. Single O-rings are placed on both distal wings to prevent unwanted tooth rotation. Continuous elastomeric chain is placed around the arch from first molar to first molar only after a Class I occlusion has been achieved and no further Class II correction is desired.

In the mandible, the archwire is ligated initially with single elastomeric ties and later with elastomeric chain extending from first molar to first molar only when a heavier rectangular wire is inserted.

Vertical separation (disclusion) of the incisors

The next goal of treatment is to provide separation of the maxillary and mandibular incisors, typically through upper and lower incisor intrusion. Ricketts has stressed the importance of avoiding unintentional incisal contact during the subsequent correction of anteroposterior discrepancies with such auxiliary appliances as a facebow or Class II elastics (Ricketts RM, personal communication, 1974).

The need to avoid incisal contact early in treatment is also illustrated by the evaluation of progress study casts taken before orthognathic surgery. When preparing a patient for surgery, the incisors should be repositioned with fixed appliances so that incisal contact is greatly reduced or eliminated altogether. Maximal posterior contact can be achieved when the presurgical study casts are hand-articulated to their desired postsurgical position. In this way, the sur-

geon is free to change the relationship of the maxilla and the mandible without encountering interferences produced by unintentional anterior contact.

Correction of the sagittal relationship of the posterior teeth

The correction of any residual Class II or Class III sagittal relationships is begun at this time. In the author's practice, interarch elastics (eg, 0.25-inch, 6-oz elastics) are typically used to produce the necessary correction, attaching the elastic anteriorly to the ball hooks on the maxillary canines and posteriorly to the hooks on the mandibular first or second molars in instances of Class II correction. Class II elastics are used initially, after a 0.016 × 0.022-inch NiTi wire is placed in both arches. Depending on anchorage requirements, a rectangular beta-titanium alloy or stainless steel wire also can be used. The use of stiffer archwires during elastic wear is important if there is concern about continued leveling and vertical control, as well as flaring of the mandibular incisors.

To facilitate sliding mechanics when attempting to slide a tooth along an archwire during space closure, a minimum 0.002-inch size difference should be maintained between the archwire and the bracket slot¹⁰ (eg, a 0.016-inch archwire sliding through a 0.018-inch bracket). The placement of elastomeric chain around the arch from molar to molar must be avoided until adequate molar correction is attained, again to prevent unwanted retraction of the maxillary incisor and also to avert possible anchorage loss.

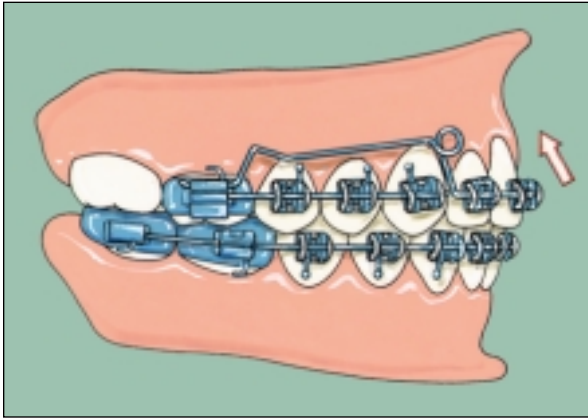


Fig 3 The upper retraction utility arch after activation. The maxillary anterior teeth have been moved superiorly and posteriorly, and the space distal to the lateral incisor has closed.

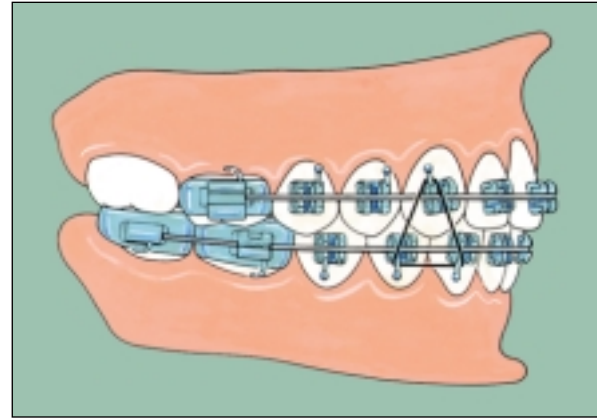


Fig 4 Triangular elastics (0.25-inch, 4- or 6-oz elastics) are used to seat the canines and adjacent teeth. Ligation of the archwires is not shown.

Retraction of maxillary anterior teeth

The mechanics described thus far (even in non-extraction cases) will often result in small spaces appearing distal to the maxillary lateral incisors (Fig 2). A retraction utility arch^{2,9} is usually used to intrude and retract the maxillary incisors (Fig 3). The lower archwire, now a 0.016 × 0.022-inch TMA (Ormco/Sybron, Orange, CA) wire, typically is stepped down in the mandibular incisor region. Other types of looped closing arches, made from beta-titanium, chrome-cobalt, or stainless steel wire can also be inserted to retract the maxillary incisors. Anterior space closure typically is supported by either full-time or nighttime wear of Class II elastics.

Fine detailing of the occlusion

After the molar correction has been achieved, and excess overjet and overbite have been eliminated, the finishing sequence begins. The archwires used at this time should have high formability, so that precise detailing of the occlusion can be accomplished. These wires should also have a high stiffness to allow sufficient force for final leveling and torquing movements. Archwires suitable for this purpose include rectangular wires made of beta titanium, chrome cobalt, or stainless steel. The author's choice is 0.016 × 0.022-inch TMA archwire. Triangular elastics are also used at the end of treatment to seat the canines and premolars before appliance removal (Fig 4).

As the patient nears completion of treatment, the archwires are removed and "debond evaluation"

casts are obtained. The casts are evaluated for errors in tooth position, adjustments are made in the archwires, and then these casts are sent to the laboratory for the fabrication of a tooth positioner, which is delivered at the time of appliance removal.

DETAILS OF BRACKET PLACEMENT

One of the most critical aspects of fixed appliance treatment is the position of the bracket on each tooth. Many clinicians take great pride in being known as a "good wire bender," and their typical final archwires give testament to their wire-bending skills, with multiple first-, second-, and third-order bends present in each wire. A final archwire requiring multiple artistic bends is, however, less an indication of a clinician's prowess in archwire fabrication and more an indication of an inability to place brackets correctly.

During the last 10 years, the author has been involved in a group practice in which all patients are seen by multiple orthodontists. Thus, it has been very important to formalize concepts of bracket position, so that it usually is impossible to tell which clinician in the practice initially placed the brackets and bands. Bracket placement has been standardized so that ideal bracket position can be visualized.

One of the primary goals of the practice's comprehensive orthodontic treatment is to correct overbite before correcting overjet, as has been described above. Thus, mechanics that open the bite anteriorly have been emphasized, and this opening of the bite is incorporated into routine bracket placement. In addition, favorable rotation of the buccal segments

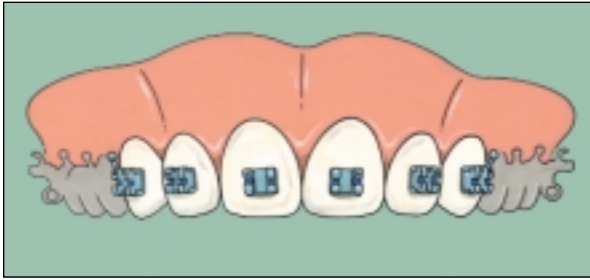


Fig 5 Idealized bracket placement on the maxillary anterior teeth.

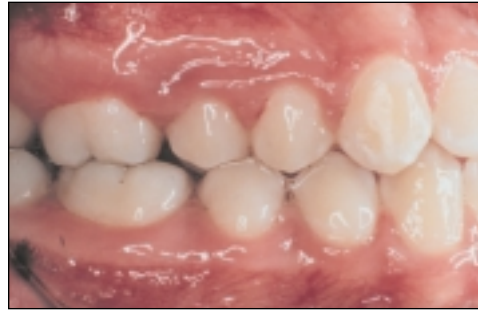

Fig 6 Intraoral photograph of a treated patient with incomplete correction of the sagittal malocclusion. The canines and first premolars are in a normal relationship; however, the maxillary second premolar is rotated to the mesial, due to improper bracket placement. Also, note the lack of contact of the distobuccal cusp of the maxillary first molar with the mesiobuccal cusp of the mandibular second molar, an indication that the maxillary first molar was not sufficiently rotated to the posterior around the palatal root.

(eg, posterior rotation of the buccal aspects of the crowns of the maxillary posterior teeth) leads to a slight, but predictable, correction in the occlusal relationship. These rotations are aided further fully activating the soldered transpalatal arch that is placed at the beginning of treatment. Further, overjet is corrected only after proper vertical clearance of the incisors has been achieved and after the anteroposterior relationship of the posterior teeth is satisfactory. These relatively minor movements of the teeth that are crucial for the efficient treatment of the malocclusion are facilitated by proper bracket placement, the specifics of which are described below.

Maxillary incisors

To facilitate slight bite opening, the brackets are placed on the maxillary incisors at 3.5 to 4.0 mm above the incisal edge, as measured from the center of the bracket slot (Fig 5). Each bracket is placed at the mesiodistal center of the crown of each incisor, and the wings of the bracket parallel the long axis of the crown. The incisal edge of the lateral incisors either can be maintained at the same level as the central incisor or can lie 0.5 mm gingival to the incisal edges of the central incisors and canines by placing the bracket slot 0.5 mm more incisally.

Maxillary canines and premolars

The bracket placement on maxillary canines is similar to that of the central incisors, in that the bracket

is placed in the mesiodistal center of the labial surface of the clinical crown about 3.5 to 4.0 mm from the incisal edge. An alternate position of the brackets on the maxillary premolars is recommended, however, particularly on the maxillary second premolars (Jensen JL, personal communication, 1976). Examination of finished orthodontic cases both in a university orthodontic clinic and as an examiner for the Edward H. Angle Society has revealed that a common malalignment present at the end of treatment is a lack of contact of the maxillary second premolar with the mandibular first molar (Fig 6). This lack of contact often is a result of inadequate posterior rotation of the premolar and, in great part, may be due to the initial bracket placement on that tooth. In addition, the retraction of anterior teeth with elastomeric chain often results in mesial rotation of the teeth in the buccal segments during treatment, especially if the maxillary molars are not supported by a transpalatal arch or facebow. Proper bracket position can help counteract this tendency.

When placing a bracket, particularly on the maxillary premolars, it is common to first determine the midline of the tooth by examining the buccal and lingual cusps (Fig 7a). Traditionally, the bracket is placed at the mesiodistal center of the buccal surface (Fig 7b). Placing the bracket in a slightly more anterior position on the buccal surface of the maxillary second premolar is recommended (Fig 7c). Such bracket positioning will result in a favorable slight distal rotation of the maxillary premolar when the archwire is ligated in place.

The example shown in Fig 7 is of a symmetrical premolar. In clinical practice, however, it is far more

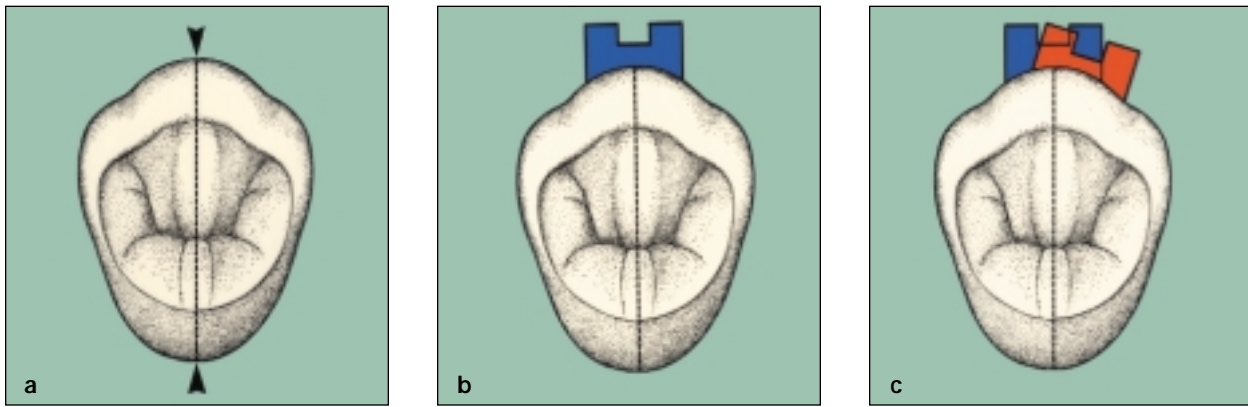


Fig 7 Placement of brackets on a symmetrical premolar. **(a)** The long axis of the tooth (*dashed line*) is determined by positions of the buccal and lingual cusps. **(b)** Typically, the bracket (*blue*) has been centered along the long axis. **(c)** Recommended mesial position of the bracket (*red*). Engaging the archwire into the bracket will produce a posterior (favorable) rotation of the crown. Anterior is to the right, posterior to the left.

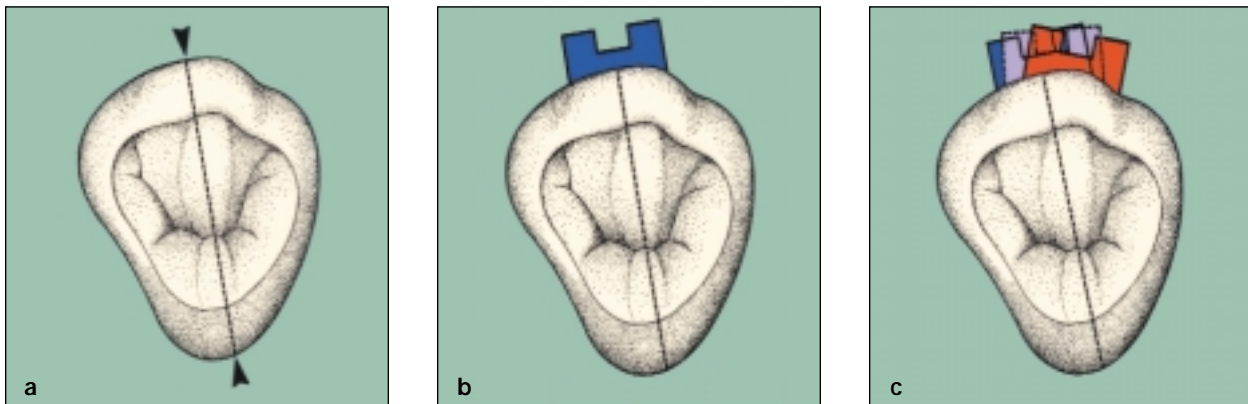


Fig 8 Placement of bracket on an asymmetrical premolar. **(a)** The lingual cusp is oriented toward the anterior, and thus the long axis of the tooth (*dashed line*) is positioned more posteriorly. **(b)** If the bracket is placed according to the long axis, the bracket (*blue*) will be located posteriorly, resulting in an unfavorable anterior rotation of the premolar. **(c)** In placing the bracket, the lingual cusp is ignored and only the buccal cusp is evaluated. The lavender bracket is centered on the actual midpoint of the buccal cusp. The red bracket is located anterior to the midpoint of the buccal cusp, as described in Fig 7c. Favorable posterior rotation of the premolar will occur after ligation of archwire into the bracket. Anterior is to the right, posterior to the left.

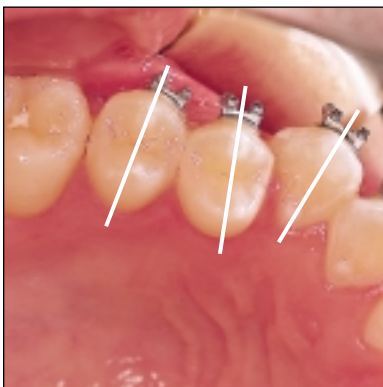


Fig 9 Occlusal view of proper bracket placement on the maxillary canine and premolars. The white lines indicate the long axes of the teeth. Note that the bracket on the second premolar is anterior to the midpoint of the buccal cusp. Modest adjustments have been made in the positions of the other 2 brackets.

common to encounter a maxillary premolar that is asymmetrical in shape, with the lingual cusp located more anteriorly (Fig 8). When the midline of the tooth, as determined by the buccal and lingual cusps, is identified (Fig 8a), and the bracket is placed according to the midline orientation, the bracket is bonded too distally (Fig 8b). This position will cause undesirable mesial rotation of the bracket following ligation of the archwire into the bracket. This type of rotation is unfavorable except in patients having a tendency toward Class III malocclusion. If the bracket is placed more anteriorly on the maxillary second premolar (Figs 8c and 9), automatic correction toward a Class I relationship will occur after the archwire is ligated in place.

More mistakes are made in the positioning of the bracket on the maxillary second premolar than on any other tooth. When a bracket is placed on a maxillary second premolar using a direct visualization technique, the clinician often will overcompensate for his or her inability to easily see the tooth by placing the bracket in a more distal position than that shown in Fig 8a. This overcompensated bracket position will result in an unfavorable mesial rotation of the premolar following archwire ligation (Fig 6).

Thus, when placing a bracket on maxillary premolars, it is prudent to ignore the lingual cusp of these teeth altogether. Instead, first evaluate the occlusion intraorally or by way of study casts, and then simply use the buccal cusp of the tooth as a guide, always remembering to place the bracket mesial to the center of the buccal cusp of the maxillary second premolar and according to the needs of the occlusion when bonding the maxillary canine or first premolar.

The proper positions of the maxillary posterior brackets also are shown in Figs 10 and 11. Note the very slight mesial positioning of the premolar and canine brackets in the occlusal view.

Mandibular incisors

Bracket positioning on the mandibular incisors is relatively straightforward. The brackets are placed at the mesiodistal center of the crowns (Fig 12). From an incisogingival perspective, the brackets are positioned toward the incisal edge (Fig 13). Only in patients with extreme deep bite are the brackets placed in a more gingival direction, an orientation that may tend to extrude these teeth, making overbite correction more difficult. In instances of excessive vertical overlap of the teeth, it is more common to place appliances on the upper arch initially and, using leveling and intrusive mechanics (eg, utility

arch, anterior bite plate, "turbo-tails"), open the bite anteriorly before lower bracket placement.

Mandibular canines and premolars

The placement of brackets on mandibular canines and premolars is also relatively straightforward (Fig 14). Every effort should be made to place the brackets gingivally, especially in the region of the mandibular second premolar, so that the brackets are out of occlusion. Placing the brackets gingivally also aids in the leveling process. Bracket failure is most frequently observed in this region. This failure may be due to a number of factors, including the presence of a pellicle on a recently erupted second premolar. In addition, this region is a site of frequent contamination during the bonding process. The bracket also may be dislodged due to the forces of mastication. If the mandibular premolar bond fails more than once, the placement of a band on the tooth may be indicated. Because of the frequency of loose brackets in this area, mandibular second premolars routinely are banded rather than bonded in the author's practice.

From a mesiodistal perspective, the brackets are placed in the center of the buccal cusp in Class I and Class II patients (Fig 12). In Class III patients, a more mesial placement of the bracket on the posterior mandibular teeth is indicated, as was described for Class II and Class I patients in the placement of maxillary brackets.

Overview of bracket placement

The placement of brackets in a patient in the early permanent dentition is shown in Fig 15. This clinical example illustrates the appliance system currently used in the author's practice, as well as the positioning of each bracket placed according to the morphology of each tooth regardless of the position of that tooth within the arch.

The position of the bracket on the maxillary left lateral incisor in Fig 15 is of interest. Note that the distance of the bracket from the incisal edge is slightly greater than that of the bracket on the lateral incisor on the opposite side. In this instance, the bracket on the left lateral was intentionally placed slightly more gingivally because of the morphology of the incisal edge of that tooth. The incisal edge of the left lateral was later modified to eliminate the small bump (mamelon). Judicious enamoplasty before bracket placement is recommended in instances of abnormal tooth morphology or wear.

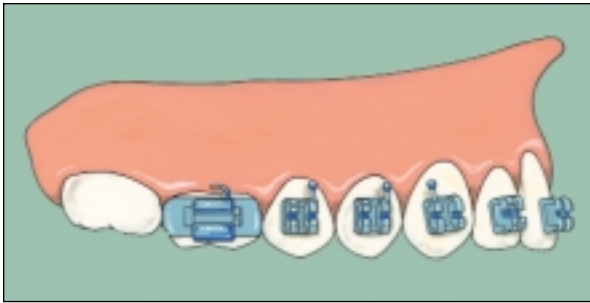


Fig 10 (Above) Lateral view of idealized maxillary bracket and band position.

Fig 11 (Right) Occlusal view of idealized maxillary bracket and band position.

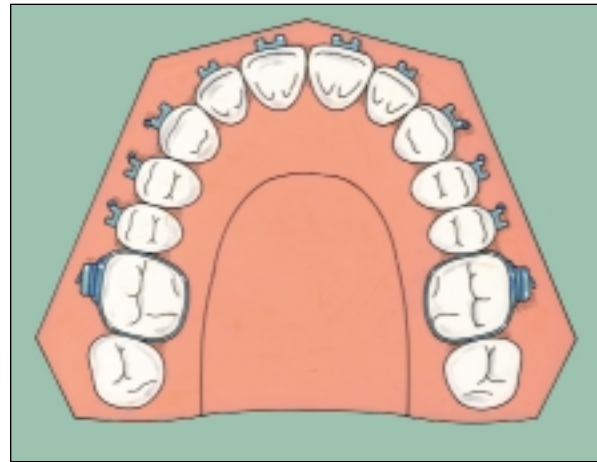


Fig 12 (Left) Occlusal view of idealized mandibular bracket and band position.

Fig 13 (Below) Frontal view of idealized mandibular bracket position.

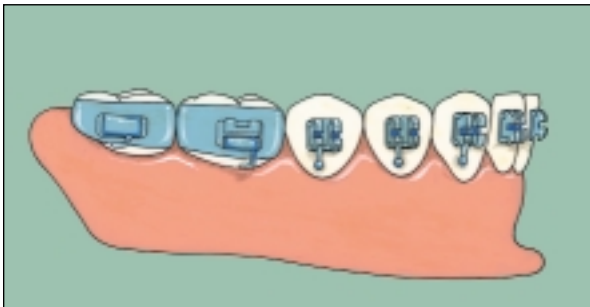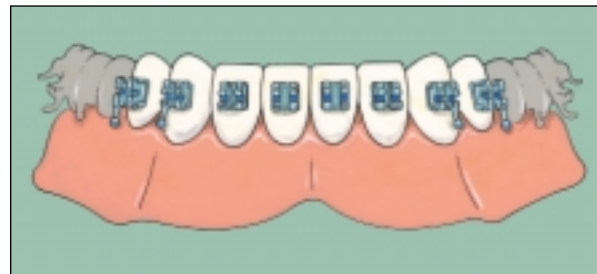
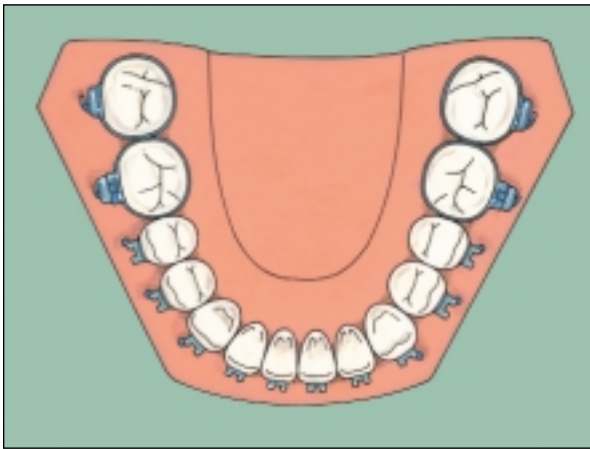


Fig 14 Lateral view of idealized mandibular bracket and band position.

BAND SELECTION

The placement of bands is considered “common knowledge” among orthodontists and thus will not be described in detail here. Only a few remarks concerning the placement of separators and the selection and cementation of bands are in order.

Separators

Although there is a wide variety of materials that have been used for the separation of teeth, including brass wire, 2 types of separators normally are used in the author’s practice: elastomeric separators and spring-type separators made from stainless steel wire.

Elastomeric separators. For most patients, particularly patients who began treatment in the mixed dentition, the clinician will experience little difficulty in placing separators. Routinely, a separating pliers can be used to stretch the separator and place it interproximally (Fig 16).

An alternative method (easily performed by a patient or parent) is the placement of the elastomeric separator using dental floss. Two pieces of dental floss are threaded through the center of the separator (Fig 17a). A hemostat and a piece of floss can also be used. The separator is stretched and placed through the contact point (Fig 17b). The

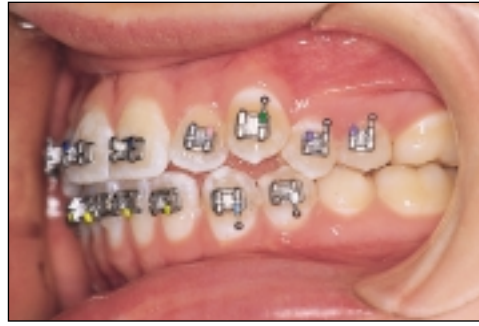
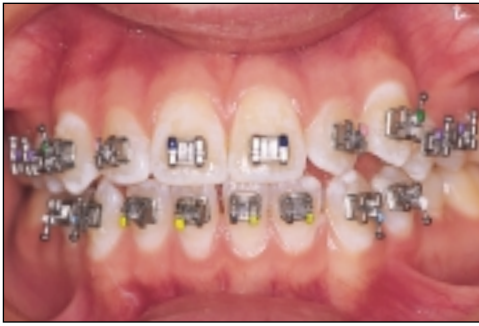
Fig 15 Intraoral views of a patient following bracket placement. Appliances shown are the midsize Tru-Straightwire brackets from Ormco, Glendora, CA (0.018-inch slot, non-extraction Roth prescription). See text for specific comments about bracket position. (*Left*) Frontal view. (*Right*) Left lateral view.

dental floss is then removed. If an elastomeric separator continues to break on tight contacts, a piece of floss can be snapped through the contact and the separator is pulled under the contact, stretched, and snapped through the contact superiorly.

As the loss of elastomeric separators is a common occurrence, the patient can be instructed on the proper method of replacement using dental floss if a separator is lost before the banding appointment.

Spring-type separators. The spring-type separator (TP Laboratories, LaPorte, IN) is used only in patients with extremely tight or gingivally positioned contacts (common in adult patients). A Weingart pliers is used to grasp the short arm of the separator. The long, hooked arm of the separator is placed under the contact point from the lingual aspect and the short arm pried open with the pliers. The separator is rotated into position with the short arm lying under the contact point and the long arm lying over the contact point.

The removal of the spring-type separator is accomplished most easily using 2 hooked scalers. The tip of 1 scaler is placed through the center of the spring, while the tip of another scaler is placed in the hooked portion of the long arm. The spring-type separator is then pulled laterally, dislodging it from the contact point.

Band placement

In the author's practice, bands are usually placed on both mandibular permanent molars and on the mandibular second premolars. As mentioned before, the latter teeth are banded rather than bonded because mastication forces tend to dislodge the brackets on the mandibular posterior teeth. Bands also are placed on the maxillary first permanent

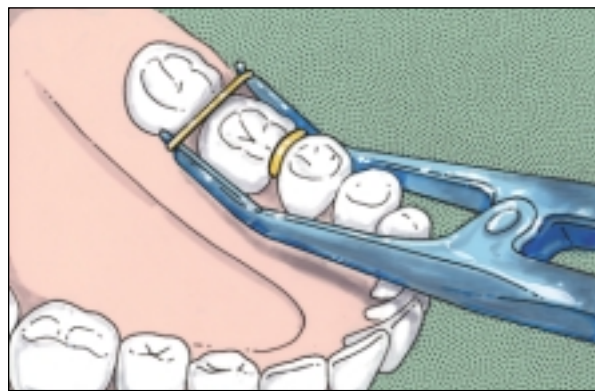


Fig 16 Placement of elastomeric separators using separating pliers.

molars, usually connected by a transpalatal arch. The maxillary second molars are banded only in instances in which there are obvious abnormalities in tooth position (eg, rotation, flaring, crossbite).

The bands are placed symmetrically on the teeth, particularly with respect to the contours of the marginal ridges. In addition, the bands should be large enough to fit teeth adequately. A band that is too small may appear to fit the tooth snugly but will result in a bracket or tube position that is too occlusal. On the other hand, a band that does not fit tightly will have more cement between the band and the tooth, a situation that leads to the increased probability of washed-out cement and subsequent decalcification of the tooth. In addition, loose-fitting bands obviously have to be recemented more frequently.

Bands are usually cemented using a resin cement (Bandlok, Reliance Orthodontics, Itasca, IL). Cement that is not tooth colored (as, for example, blue Bandlok) is preferred because it has been found to be much easier for the clinician to differentiate cement

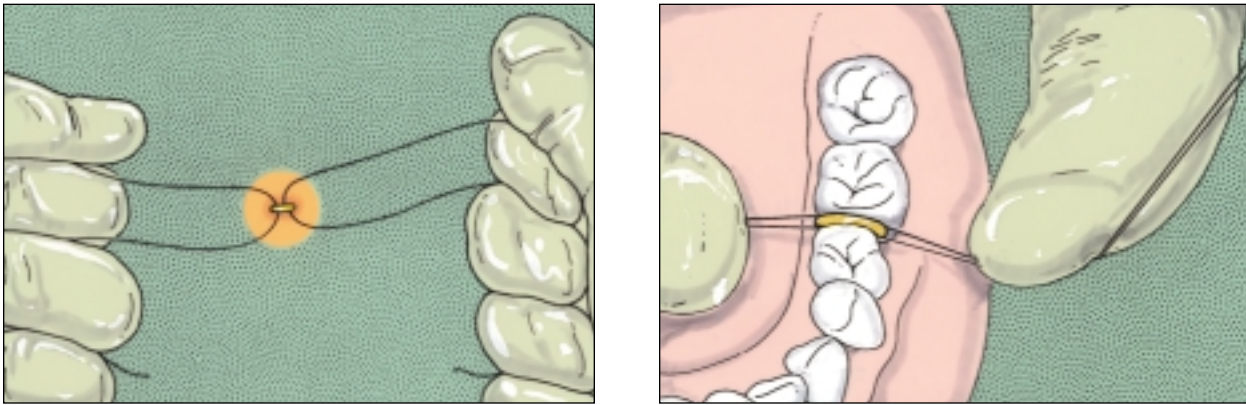


Fig 17 Placement of elastomeric separators using dental floss. **(a)** Two pieces of floss are placed through the hole in the center of the separator with 1 held in each hand. **(b)** The placement of the elastomeric separator through a contact point with dental floss.

from tooth material during cement cleanup and following band removal.

In instances in which bands are going to be intentionally recemented within a few weeks or months (eg, following further activation of the soldered transpalatal arch), the use of glass-ionomer resin cement is not recommended. Rather, a polycarboxylate cement such as Durelon (Premiere Company, Germany) is used. Due to the lower adhesion strength, this cement will not cause discomfort to the patient during band removal.

CONCLUSION

Someone once said, "The opportunity of greatness lies in doing ordinary things extraordinarily well." That anonymous quote summarizes the purpose of this article: To discuss some of the little things dealing with the management of routine orthodontic treatment that not only can affect the outcome of treatment, but also can make that treatment more efficient.

It is extremely important for the clinician to have a clear vision of the goals that he or she wants to reach at the end of routine orthodontic treatment. The importance of proper bracket position, as well as the use of the transpalatal arch and the utility arch as routine parts of orthodontic mechanics, has been emphasized. A logical progression of archwires, largely using "memory wires," has been presented. These archwires have a long period of activation while engendering minimal discomfort to the patient.

It is assumed that the reader is well versed in the various orthodontic treatment mechanics available today, and that he or she will make use of whatever techniques or protocols are appropriate for the given

patient. It is hoped that some of the details of what has been described as "ordinary orthodontics" will contribute to the improvement of fixed appliance therapy as practiced on a daily basis.

ACKNOWLEDGMENTS

The author wishes to acknowledge the superb artistic skills of Mr William L. Brudon, who created the illustrations for this article, and to Katherine Kelly and Laurie McNamara for their critical review of this manuscript.

REFERENCES

1. Covey SR. *The Seven Habits of Highly Effective People*. New York: Simon and Schuster, 1989.
2. McNamara JA, Jr. Utility arches. *J Clin Orthod* 1986;20:452-456.
3. Hilgers JJ. The pendulum appliance for Class II non-compliance therapy. *J Clin Orthod* 1992;26:706-714.
4. Pancherz H. The mechanism of Class II correction in Herbst appliance treatment. A cephalometric investigation. *Am J Orthod* 1982;82:104-113.
5. Clark WJ. The twin block traction technique. *Eur J Orthod* 1982;4:129-138.
6. Wilson RC, Wilson WL. *Enhanced Orthodontics*. Denver: Rocky Mountain Orthodontics, 1988.
7. McNamara JA, Jr. The role of the vertical dimension in orthodontic diagnosis and treatment in growth modification: What works, what does not and why. *Ann Arbor: Monograph No. 36, Craniofacial Growth Series, Center for Human Growth and Development, The University of Michigan*, 1999.
8. McNamara JA, Jr. Maxillary transverse deficiency. *Am J Orthod Dentofacial Orthop* 2000;117:567-570.
9. McNamara JA, Jr, Brudon WL. *Orthodontic and orthopedic treatment in the mixed dentition*. Ann Arbor: Needham Press, 1993.
10. Proffit WR. *Contemporary Orthodontics*. St Louis: Mosby, 1986.