

# Growth of the Maxillary Complex in the Rhesus Monkey (*Macaca mulatta*)<sup>1</sup>

JAMES A. McNAMARA, JR.,<sup>2</sup> MICHAEL L. RIOLO<sup>3</sup> AND DONALD H. ENLOW<sup>4</sup>

<sup>2</sup> Center for Human Growth and Development and Department of Anatomy, The University of Michigan, Ann Arbor, Michigan 48104; <sup>3</sup> Center for Human Growth and Development, The University of Michigan, Ann Arbor, Michigan 48104, and <sup>4</sup> Department of Anatomy, West Virginia University, Morgantown, West Virginia 26505

**KEY WORDS** Growth · Maxilla · *Macaca mulatta* · Cephalometrics · Implants · Bone markers.

**ABSTRACT** The growth of the maxillary complex of 36 rhesus monkeys (*Macaca mulatta*) was analyzed quantitatively and qualitatively during four defined stages of postnatal development (i.e., infant, juvenile, adolescent, young adult). At each stage, growth was observed during a 24 week period. Since some animals were observed during two successive stages of development, 47 periods of growth were studied. The incremental growth data were collected by superimposing serial cephalograms on cranial base implants and on maxillary implants.

The largest increments of growth were observed in the infant animals and were successively less during the other periods studied. The horizontal growth component was more prominent than the vertical component in all age groups. The contribution of sutural growth to the vertical displacement of the maxilla was greater posteriorly, leading to a rotation of the maxillary complex during growth. The occlusal relationship was maintained by selective bone remodeling in conjunction with dentitional migration.

Growth and remodeling patterns of the maxillary complex in man and in other primates are very complex. Differential growth in at least six sutural systems (zygomatico-temporal, zygomatico-maxillary, fronto-maxillary, fronto-zygomatic, ethmoid and premaxillary) precludes a satisfactory description of maxillary growth by analysis of changes in external configuration alone, a method usually used in studying mandibular growth. The effective growth of the middle face is the result of a passive displacement of the whole naso-maxillary complex associated with sutural growth as well as differential deposition and resorption on bony surfaces and the vertical and horizontal migration of the dentition (Enlow, '68; Duterloo and Enlow, '70).

Several studies of human maxillary growth have previously been published. Enlow and Bang ('65) and Enlow ('68) have reported histological studies of pat-

terns of bone growth and remodeling in the maxillary region. Björk ('55, '66) and Björk and Skieller ('72) reported cephalometric studies of maxillary growth based on implant superimposition in the maxillary complex.

Several studies of naso-maxillary growth in nonhuman primates have also been reported. Swindler et al. ('73) studied two genera (*Macaca nemestrina* and *Papio cynocephalus*) of animals of known age in a cephalometric study. Moore ('49) described remodeling patterns in the craniofacial complex of a juvenile rhesus monkey (*Macaca mulatta*), using a vital staining technique. Enlow ('66) compared facial growth in man and the rhesus monkey after a histologic study of 11 rapidly growing animals. He reported major differences in several regional growth patterns between these two primate forms, particu-

<sup>1</sup> This study was supported in part by United States Public Health Service Grants HD-02272 and DE-03610.

larly in the premaxillary and malar regions of the maxillary complex. A few cephalometric-implant studies of normal maxillary growth in *M. mulatta* have also been reported. Gans and Sarnat ('51) studied sutural growth in the upper face of four infant and four juvenile rhesus monkeys for seven to ten months. Erickson ('58) described craniofacial changes in three juvenile animals for a six month period and Pihl ('59) followed two of these animals for an additional 18 months. Elgoyhen et al. ('72) described and quantified maxillary and mandibular growth changes in 13 juvenile monkeys for a five month

period. Comparative data concerning maxillary growth of rhesus monkeys of varying age levels, however, are not presently available.

The purpose of this report is to provide quantitative and qualitative documentation of the growth and remodeling of the maxillary complex of the rhesus monkey. Four age levels are considered and the various rates, directions and growth processes of the maxillary region are compared. This information is important not only for a better understanding of the normal growth and development of the maxillary complex in the rhesus monkey but also can be

TABLE 1  
*Distribution of animals by periods studied*

ID <sup>1</sup>	Sex	Age or approximate age when study started (months)	Study periods				Total periods
			I	II	III	IV	
1	F	5½ <sup>2</sup>	X				1
2	F	5½ <sup>2</sup>	X	X			2
3	M	6 <sup>2</sup>	X				1
4	M	6 <sup>2</sup>	X	X			2
5	F	6 <sup>2</sup>	X	X			2
6	M	6½ <sup>2</sup>	X				1
7	M	7 <sup>2</sup>	X	X			2
8	M	7 <sup>2</sup>	X	X			2
9	F	7 <sup>2</sup>	X				1
10	M	19 <sup>2</sup>		X			1
12	M	22½ <sup>2</sup>		X			1
13	M	45-54			X	X	2
16	M	45-54			X		1
19	M	45-54			X	X	2
20	M	18-24		X			1
21	M	45-54			X	X	2
23	M	18-24		X			1
24	M	45-54			X		1
25	M	18-24		X			1
26	M	18-24		X	X		2
27	M	18-24		X			1
28	M	18-24		X			1
29	F	18-24		X			1
30	F	18-24		X			1
31	M	18-24		X			1
32	M	18-24		X			1
33	M	45-54			X	X	2
34	M	45-54			X		1
35	M	45-54			X	X	2
36	M	72+				X	1
37	M	72+				X	1
38	F	72+				X	1
39	F	72+				X	1
40	F	72+				X	1
41	F	72+				X	1
42	F	72+				X	1
			9	17	9	12	47

<sup>1</sup> The identification numbers correspond to those used in the study of mandibular growth in the rhesus monkey (McNamara, J. A., Jr., and L. W. Graber, *Am. J. Phys. Anthropol.*, 42: 15-24.

<sup>2</sup> Birth date known.

used as a baseline for the analysis and interpretation of experimental findings.

#### MATERIALS AND METHODS

**Animals.** The growth and remodeling of the maxillary complex was studied during four stages of postnatal development. As in the previous study of mandibular growth in the rhesus monkey (McNamara and Graber, '75) four groupings of animals were established on the basis of dental development to determine the relationship of age and maturational level to the growth and remodeling of the maxillary complex.

The *infant* animals (Group I studied during period I) possessed complete deciduous dentitions at the onset of the study. The birthdates of these animals were known and ranged from five and one-half to seven months of age at the time of the first cephalogram (table 1). The *juvenile* animals (Group II studied during period II) had complete deciduous dentitions and the first molars were fully in occlusion. The exact dates of birth of most animals in Groups II, III, and IV were not available. According to the tables of tooth eruption of Hurme and Van Wagenen ('53, '61) and Schultz ('69) the animals in Group II were approximately 18 to 24 months of age. The animals in the *adolescent* group (Group III studied during period III) possessed a full permanent dentition except for unerupted third molars and partially erupted cuspids. These animals were approximately four to four and one-half years old. The *young adult* animals (Group IV studied during period IV) were at least six to seven years of age and had complete permanent dentitions including fully erupted third molars.

Thirty-six *Macaca mulatta* from the primate colony at The Center for Human Growth and Development, The University of Michigan, were used. Each period of maxillary growth observed was 24 weeks in duration. Since 11 of the animals had been followed longitudinally for over three years, cephalograms of these animals could be placed in two of the groups (table I). The average time interval between the two initial radiographs of the one animal used in both Groups II and III was 22 months. The average interval between the two initial radiographs of the five animals

used in Groups III and IV was 22 months.

**Implant technique.** Twenty-nine tantalum implants (Björk, '55, '66, '68; McNamara, '72) were placed in each animal. Four pins were placed extraorally in the right side of the mandible (fig. 1). Five pairs of implants were inserted bilaterally in the maxillary region; one pin in the bone between the central and lateral incisors, one pin in the palate adjacent to the canine, one pin above the second deciduous molar or the first permanent molar, one pin below the orbit and one pin adjacent to the zygomatic arch.

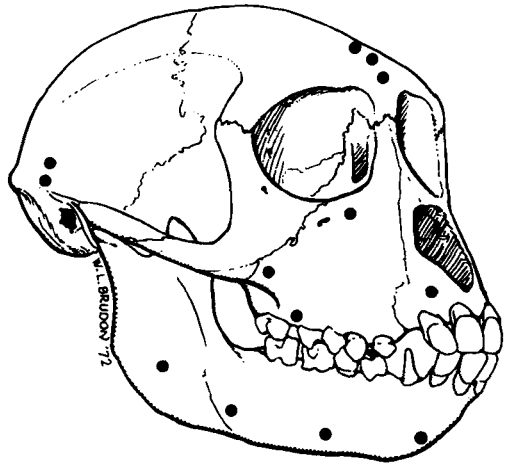


Fig. 1 Location of the tantalum implants. Pins in the occipital region and in the cranial base are not shown.

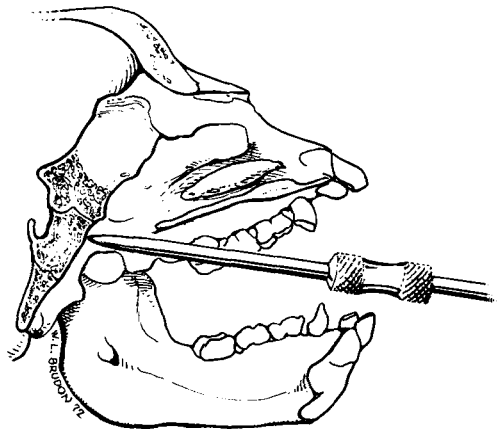


Fig. 2 Implant placement in the cranial base region.

Five implant pins were placed in the midline of the cranial base by penetrating the posterior pharyngeal wall (fig. 2). In most instances, a small incision was made in the soft palate to facilitate placement of the pins in the cranial base area. Pins were placed above and below the sphenoccipital synchondrosis. Ten pins were also inserted into the other parts of the cranium, but only the three pins in the frontal bone were used in this study.

*Cephalometric analysis.* Each animal was radiographed at the beginning and at the end of the 24-week period using a cephalostat especially designed for primates (Elgoyhen et al., '72). The fine grain of the Kodak type M industrial film used in this procedure allowed for precise definition of structures. Two lateral views were taken on each occasion, one with the teeth in occlusion and one with the mouth held open. For the purposes of this study, only the former film was used. Each radiograph was then copied on Kodak Translite film and enlarged three times the original size. This enlargement procedure allowed for tracing and direct quantification of various small changes in craniofacial dimensions which normally might be masked by tracing errors.

Growth changes were analyzed by two measuring procedures (McNamara and Graber, '75). First, a piece of 0.003 acetate tracing paper was placed on the initial cephalogram and the outlines of the cranial implants and of the inferior portion of the endocranial surface of the orbital roof were registered. Implants below the sphenoccipital synchondrosis were not usable because of the evident growth at this junction in the immature animals. A reference line was drawn along the functional occlusal plane (fig. 3), establishing the horizontal (and vertical) orientation for the measurements on each animal. This "template" provided a means of quantifying skeletal and dental changes in successive cephalograms *relative to the position of the implants in the anterior portion of the cranial base*. In most previous studies, only a "best fit" superimposition on cranial base structures was possible.

A similar tracing procedure was used to quantify changes within the maxillary complex. In this instance, superimposition

of successive tracings was on implants within the maxillary complex, including those implants above the first molar region and between the central and lateral incisors in the premaxilla. Changes were measured *relative to the position of the maxillary implants*. In both methods, tracings of the outline of the craniofacial complex were used only for descriptive purposes while distance and angular measurements were made directly on the cephalograms themselves.

In describing the changes in tooth position specific terms are used. *Eruption* refers to the movement of the tooth toward occlusion. *Migration* is used to describe movement of the tooth either vertically or anteroposteriorly after the tooth has occluded with its dental antagonist. As the tooth changes position, the exposed crown length of the tooth remains relatively stable in relation to its supporting alveolar bone (Enlow, '65; Enlow and McNamara, '73). *Movement* refers to any change in tooth position.

#### FINDINGS

Profile changes were observed in every animal but the nature of these changes varied with each successive age group. The outline of the infant face moved forward and downward (fig. 4a) and the development of the muzzle increased with maturation (figs. 5a, 6a, 7a). The largest increments of growth were observed in Group I and were successively less during the other periods studied (tables 2, 3). The horizontal growth component was more prominent than the vertical component in all age groups (table 2). While there was a reduction in anteroposterior growth during successive ages, vertical growth increments were larger than horizontal growth increments in only a few random animals throughout the total sample.

The maxillary alveolar ridge and palate moved in a forward and downward direction in conjunction with the associated dentition. The effective movement of the dentition caused by the processes of displacement and migration was also directed forward and downward although the horizontal component of movement was dominant in the measured teeth by a ratio of about 4:1 compared to the vertical compo-

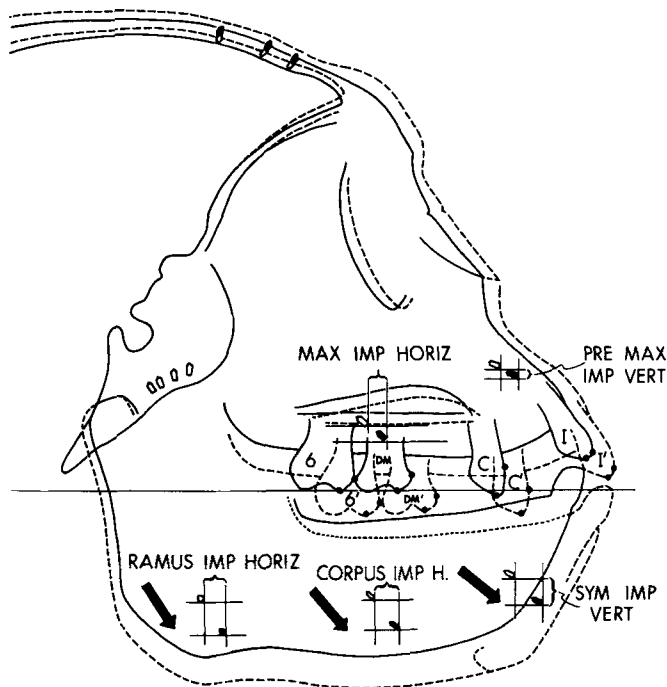


Fig. 3 Orientation line and points used in measuring maxillary growth. Superimposition is on the implants in the anterior portion of the cranial base and along the inferior portion of the endocranial surface of the orbital roof. In all tracings the solid line represents the outline of the initial cephalogram and the dashed line indicates the outline of the final cephalogram. The movement of each implant and tooth is measured in both the horizontal and vertical dimensions. Examples of such measurements are labeled in this figure.

The following measurements were taken from serial cephalograms of each animal (tables 2, 3, 5):

Premax. Imp. Horiz., Anteroposterior displacement of the premaxillary implant located between the central and lateral incisors.

Premax. Imp. Vert., Vertical displacement of the premaxillary implant.

Max. Imp. Horiz., Anteroposterior displacement of the maxillary implant located in the tuberosity above the second deciduous molar or the first permanent molar.

Max. Imp. Vert., Vertical displacement of the maxillary implant.

Palatal Descent, Vertical movement of the inferior border of the palatal outline.

I Horiz., Most anterior point on the central incisor.

I Vert., Most occlusal point on the incisal edge of the central incisor.

C Horiz., Most mesial point on the canine.

C Vert., Most occlusal point on the canine.

DM Horiz., Most mesial point on the second deciduous molar.

DM Vert., Most occlusal point on the mesial cusp of the second deciduous molar.

6 Horiz., Most mesial point on the first permanent molar.

6 Vert., Most occlusal point on the mesial cusp of the first permanent molar.

7 Horiz., Most mesial point on the second permanent molar.

7 Vert., Most occlusal point on the mesial cusp of the second permanent molar.

8 Horiz., Most mesial point on the third permanent molar.

8 Vert., Most occlusal point on the mesial cusp of the third permanent molar.

Ramus Imp. Horiz., Anteroposterior displacement of the implant located in the mandibular ramus.

Ramus Imp. Vert., Vertical displacement of the implant located in the mandibular ramus.

Corpus Imp. Horiz., Anteroposterior displacement of the implant located in the body of the mandible under the second deciduous molar or first permanent molar.

Corpus Imp. Vert., Vertical displacement of the implant located in the body of the mandible.

Symp. Imp. Horiz., Anteroposterior displacement of the implant located in the mandibular symphysis.

Sym. Imp. Vert., Vertical displacement of the implant located in the mandibular symphysis.

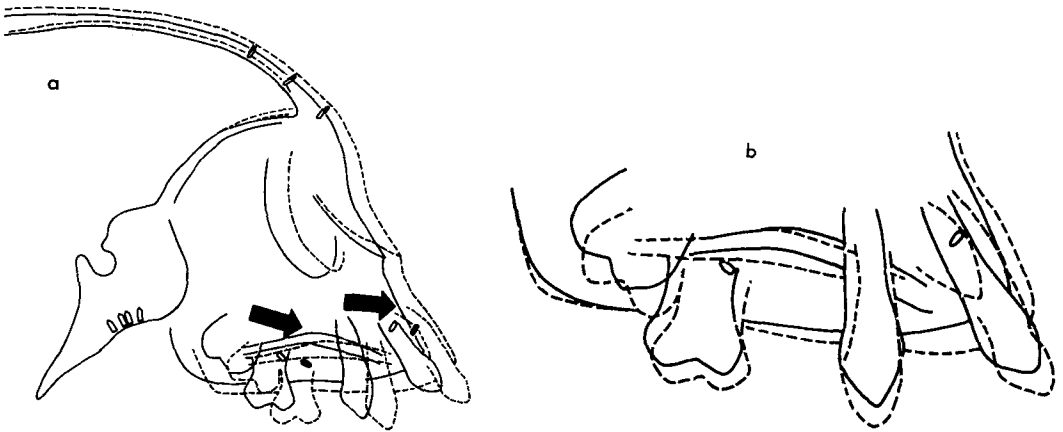


Fig. 4a Growth of the maxillary complex in the infant monkey during 24 weeks. Superimposition is upon the implants in the anterior cranial base and upon the outline of the inferior portion of the endocranial surface of the orbital roof. Note the forward and downward displacement of the premaxillary and maxillary implants. The hollow ovals indicate the first position and the solid ovals indicate the second position of the implants. The direction of movement is indicated by the arrows.

Fig. 4b Migration of the maxillary dentition in the same animal shown in figure 4a. Superimposition is on the maxillary implants. Other maxillary implants were also used for superimposition, but have not been indicated.

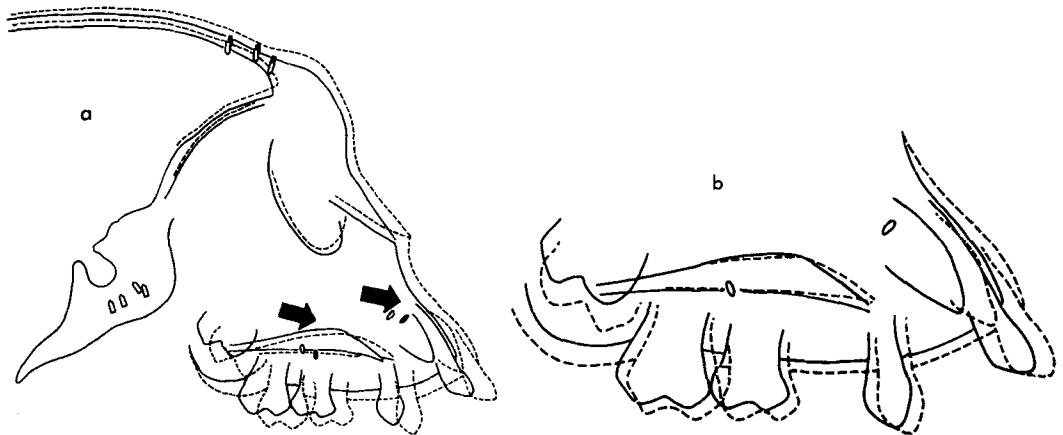


Fig. 5a Growth of the maxillary complex in a juvenile monkey. (Group II) Superimposition is on the cranial base implants, and the inferior portion of the orbital roof. Note the development of the permanent central incisor and the second permanent molar.

Fig. 5b Migration of the dentition of the juvenile animal shown in figure 5a. Superimposition is on the maxillary implants.

ment of movement (table 3). The extent of the forward movement was slightly higher in the anterior teeth.

*Processes of maxillary growth.* The role of displacement in maxillary growth was determined by measuring the changed positions of the maxillary implants relative to the implants in the anterior part of the cranial base. Forward and downward dis-

placement of the middle face was evident. Of particular significance was the counter-clockwise rotation of the maxillary complex. The vector of growth of the posterior part of the maxillary bony arch (as indicated by the displacement of the maxillary implant in the tuberosity over the first permanent molar) was forward and downward (figs. 4a, 5a, 6a, 7a, table 2). In

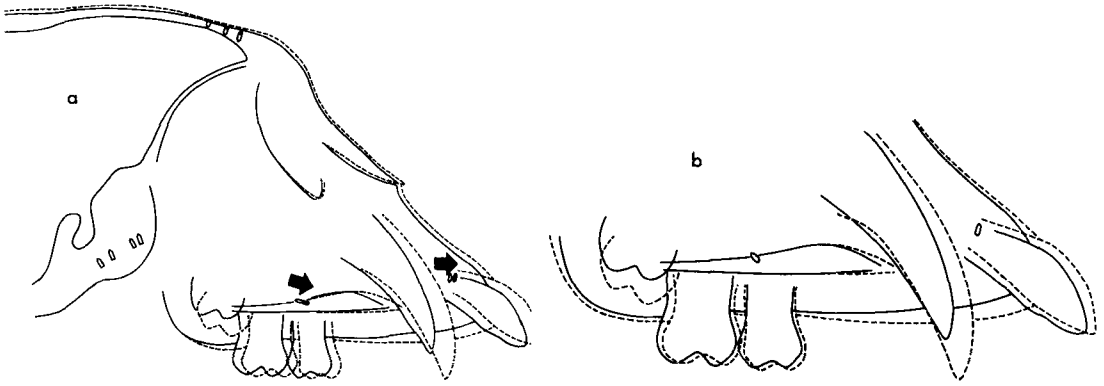


Fig. 6a Growth of the maxillary complex in an adolescent monkey (Group III). Superimposition is on the cranial base implants and the inferior portion of the orbital roof. Note the forward and downward displacement of the maxillary implant and the forward and slightly upward displacement of the premaxillary implant. The third permanent molar is developing.

Fig. 6b Migration and eruption of the maxillary dentition in the adolescent animal shown in figure 6a. Superimposition is on the implants in the maxillary complex. Note the forward migration of the central incisor and the eruption of the canine.

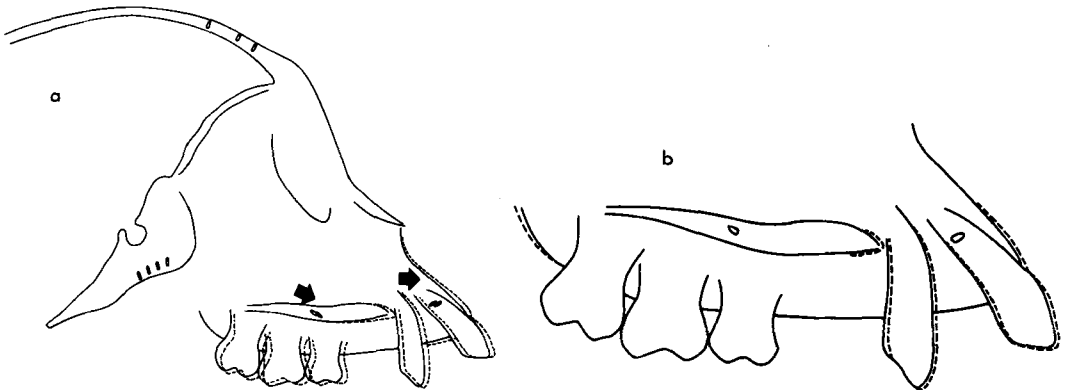


Fig. 7a Growth of the maxillary complex in a female adult animal (Group IV). Superimposition is on the cranial base implants and the inferior portion of the cranial floor. Note the slight displacement of the maxillary and premaxillary implants.

Fig. 7b Migration of the maxillary dentition in the adult female monkey shown in figure 7a. Superimposition is on the implants in the maxillary complex. Slight movement is observed in the anterior region. The posterior segments in this animal are stable.

contrast, the anterior portion of the maxillary arch (as indicated by the premaxillary implant above the central and lateral incisors) moved horizontally with minimal but variable vertical growth movement. It appeared that the contribution of the sutural systems to vertical growth was more significant in the posterior part of the maxillary complex where greater downward displacement occurred.

*Bone remodeling and dentitional migration.* During the growth periods studied, the angle of the occlusal plane remained

relatively constant to the cranial base in spite of the observed maxillary rotation. The occlusal relationship was maintained by selective bone remodeling in conjunction with dentitional migration.

By superimposing on the maxillary implants the effects of maxillary displacement were cancelled and the pattern of dentitional migration observed (figs. 4b, 5b, 6b, 7b). Vertical tooth migration (not eruption) was greater anteriorly than posteriorly (table 4). This was significant because these differential rates of vertical

TABLE 2

*Displacement of the maxillary complex relative to implants in the cranial base*

Measures (see fig. 3)	Groups							
	I (N=9)		II (N=17)		III (N=9)		IV (N=12)	
	Avg. mm	S.D. mm	Avg. mm	S.D. mm	Avg. mm	S.D. mm	Avg. mm	S.D. mm
Premax. implant horiz.	2.67	0.80	1.77	0.43	1.26	0.86	0.44	0.54
Premax. implant. vert.	0.97	0.82	0.42	0.59	0.07	0.41	-0.04	0.37
Max. implant horiz.	2.82	0.86	1.94	0.54	1.24	0.86	0.47	0.67
Max. implant vert.	1.43	0.58	1.00	0.45	0.28	0.28	0.19	0.03
Palatal descent	1.35	0.60	0.91	0.49	0.51	0.37	0.14	0.22

tooth migration tended to offset the rotation of maxillary bony arch, thereby sustaining a relatively constant occlusal plane.

A direct forward migration of the maxillary dentition was also observed. The horizontal component of migration was usually greater than the vertical even in the incisor region. The incisors drifted forward and downward at a ratio of about 2:1 except in the infant group in which an increase of vertical migration was observed (fig. 4b). The posterior dentitions of groups I, II, and III also migrated for-

TABLE 4

*Movement of the maxillary dentition — maxillary implant superimposition*

Measures	Groups			
	I (N=9)		II (N=17)	
	Avg. mm	S.D. mm	Avg. mm	S.D. mm
I Horiz.	1.45	0.39	0.99	0.40
I Vert.	0.91	0.42	0.57	0.54
C Horiz.	0.53	0.27	0.48	0.28
C Vert.	0.90	0.22	0.68	0.29
DM Horiz.	0.56	0.18	0.48	0.30
DM Vert.	0.99	0.37	0.59	0.35
6 Horiz.			0.47	0.30
6 Vert.			0.80	0.48

Measures (see fig. 3)	Groups			
	I (N=9)		II (N=17)	
	Avg. mm	S.D. mm	Avg. mm	S.D. mm
I Horiz.	4.30	1.18	3.04	0.53
I Vert.	1.86	1.44	1.14	0.82
C Horiz.	3.44	0.82	2.52	0.55
C Vert.	2.19	0.89	1.38	0.77
DM Horiz.	3.42	0.83	2.51	0.61
DM Vert.	2.47	0.58	1.30	0.75
6 Horiz.			2.53	0.59
6 Vert.			1.69	0.72

Measures	III (N=9)		IV (N=12)	
	Avg. mm	S.D. mm	Avg. mm	S.D. mm
	I Horiz.	0.91	0.26	0.27
I Vert.	0.58	0.30	0.22	0.34
C Horiz.	1.78	0.55	0.28	0.41
C Vert.	4.90	2.32	0.61	1.24
6 Horiz.	0.22	0.22	0.14	0.16
6 Vert.	0.37	0.26	0.16	0.27
7 Horiz.	0.27	0.24	0.15	0.16
7 Vert.	0.40	0.26	0.21	0.29
8 Horiz.			0.12	0.15
8 Vert.			0.25	0.34

*Movement of the maxillary dentition — cranial base implant superimposition*

ward and downward while the posterior dentition of the adult animals was generally stable (figs. 5b, 6b, 7b). The maxillary canines of the adolescent animals had the most pronounced downward and forward movement of any dental unit that was measured. However, this was true eruption rather than migration because occlusion of the canines with their dental antagonists had not yet occurred (fig. 6b).

*Sexual dimorphism.* Because of the distribution of male and female animals in Groups I, II, and IV (table 1), sexual dif-



ferences could be examined at these developmental stages. Each variable (the variables listed in tables 2, 3, 4) was studied marginally by performing a two sample t-test. In general, there were few statistically significant differences in the magnitude of the various maxillary growth increments. The only significant differences noted were found in the movement of the dentition and were restricted to the oldest age group. The sexual differences in the horizontal movement of the incisor and of the three molars relative to the cranial base implants in Group IV were statistically significant at the 0.05 level, the male monkeys exhibiting larger increments for each variable. No sexual dimorphism was evident in any of the other variables in Groups I, II, and IV. Since all of the monkeys in Group III were males, no analysis of sexual differences was possible in these animals.

*Long term serial changes in the maxillary complex.* The growth and development of the nasomaxillary complex from infancy to adulthood was reconstructed from tracings of those animals which had been followed for more than one growth period (fig. 8). By superimposing on the cranial base region, the forward and downward growth of the maxillary complex was observed. The muzzle area became more pronounced in each successive age group. The orbit was relocated in a forward and upward direction and there was continual development of the superorbital area. The palate appeared to undergo a slight counterclockwise rotation during its forward and downward movement away from the cranial base region. The paths of eruption of the first, second and third permanent molars were noted as were the paths of eruption of the permanent cuspids and central incisors.

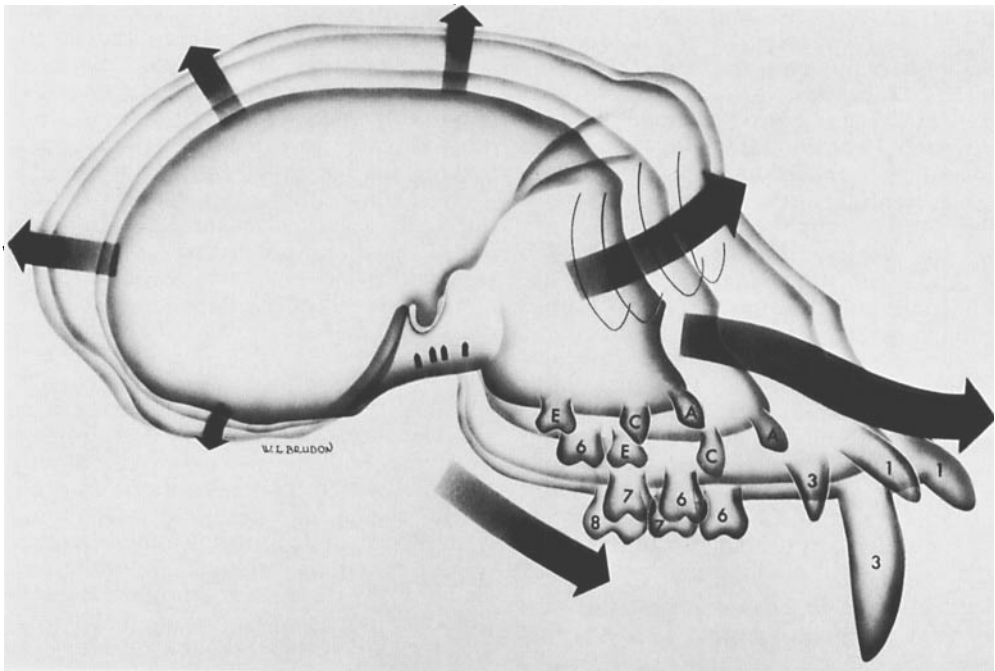


Fig. 8 Growth of the maxillary complex from infancy to adulthood. Superimposition is on the cranial base region. This composite drawing was constructed from serial tracings of those animals which were followed for more than one time interval and represents the growth of the midfacial region from approximately six months to six years of age. The time interval between the first (infant) tracing and the second (juvenile) tracing was 14 months, while the time interval between the juvenile-adolescent and adolescent-adult tracings are both approximately two years; (A) deciduous central incisor; (C) deciduous canine; (E) deciduous second molar; (1) permanent central incisor; (3) permanent canine; (6) permanent first molar; (7) permanent second molar; (8) permanent third molar.

TABLE 5

*Displacement of the mandible relative to implants in the cranial base*

Measures (see fig. 3)	Groups							
	I (N=9)		II (N=17)		III (N=9)		IV (N=12)	
	Avg. mm	S.D. mm	Avg. mm	S.D. mm	Avg. mm	S.D. mm	Avg. mm	S.D. mm
Ramus implant horiz.	3.39	1.51	2.47	0.90	2.27	0.94	0.86	0.82
Corpus implant horiz.	3.35	1.28	2.53	0.86	2.29	0.97	1.00	0.90
Sym. implant horiz.	3.35	1.18	2.54	0.87	2.23	1.04	0.87	0.78
Ramus implant vert.	4.46	1.34	3.82	3.44	2.10	0.89	1.01	1.11
Corpus implant vert.	3.55	1.01	2.43	1.15	1.39	0.65	0.75	0.75
Sym. implant vert.	2.79	1.01	1.97	1.23	0.86	0.62	0.60	0.57

*Mandibular displacement.* The translation of the mandible relative to the cranial base implants was also studied. Using the template orientation to the cranial base implants and the anterior cranial floor, the relative displacement of the mandible during growth was measured. The mandible was carried anteriorly and inferiorly with a greater vertical growth component in the posterior region (fig. 3, table 5). The downward and backward movement of the temporal bone during growth added to the vertical displacement of the mandible caused by condylar growth. Since the vertical growth component proceeded at a relatively slower rate anteriorly, the anterior portion of the mandible had less vertical translation. The mandible thus underwent a corresponding rotation during growth in the same counterclockwise manner and to the same approximate extent as did the maxillary complex. The rotation of the mandibular corpus was offset in part by increasing vertical drifting of the posterior teeth and by relatively greater bone apposition along the anterior part of the lower border of the mandibular corpus. The occlusal plane was thereby sustained in approximately the same alignment.

## DISCUSSION

Björk ('55, '66) and Björk and Skieller ('72) have shown that facial development in man is characterized by a rotation involving both jaws. Björk ('55, '66) has noted that in man the entire increase in length of the maxilla takes place posteriorly with little if any remodeling occurring on the anterior surface. Development in

height takes place by growth at adjacent sutures and by appositional growth of the alveolar process in combination with a resorptive lowering of the nasal floor. The remodeling of the maxilla is greatest either anteriorly or posteriorly depending upon whether the rotation of the face during growth is forward or backward. Björk states that this type of bony remodeling is compensatory in nature. Björk and Skieller ('72) also state that in man there is normally a forward rotation of the mandible during growth although in certain instances a backward rotation is observed. They also note that compensatory remodeling again takes place along the lower border of the mandible, primarily in the symphyseal region and the anterior portion of the lower border of the mandible, thus masking one-half of the mandibular rotation.

The results of this study indicate that craniofacial development in the rhesus monkey is also characterized by rotations involving both jaws. However, the direction of these rotations is more consistent in the rhesus monkey than it is in man. A forward or counterclockwise rotation of the maxillary complex is observed in each of the four age groups considered. This rotation is produced by a downward and forward displacement of the posterior maxilla and a more forward displacement of the anterior maxilla with variable vertical movement. Compensatory bony remodeling and tooth migration is more apparent in the anterior region of the maxilla, in which forward and downward migration of the anterior teeth and associated dentoalveolar process is observed.

Likewise, a forward rotation of the mandible relative to the anterior cranial base is a consistent finding in all age groups. McNamara and Graber ('75) in a study of rhesus mandibular growth report that appositional bone growth and remodeling occurs to a greater extent along the anterior border and symphyseal region of the mandible than along the posterior border. Likewise, vertical migration of teeth is greater posteriorly than anteriorly. Both these growth mechanisms tend to mask the rotation of the body of the mandible during growth and make such a rotation difficult to discern in serial cephalograms without the aid of metallic implants for reference.

The current study allows for an evaluation of the relative roles of displacement and regional bone growth and remodeling in the development of the maxillary complex of the rhesus monkey. Forward displacement of the middle face accounts for the major portion of the overall increase in size of the nasomaxillary complex during the growth periods studied. For example, about 80% of the overall horizontal movement of the first permanent molar in the juvenile group is due to maxillary translation (tables 3, 4). Similarly, about 60% of the forward incisor movement in the adolescent animals is due to displacement of the maxillary complex. Vertical growth, however, is not as dependent upon septal and sutural growth especially in the anterior region. In this area, localized bone remodeling and migration of the dentition compensates in part for the observed rotation of the maxillary region and helps maintain the existing occlusal relationship.

Gans and Sarnat ('51) report that the anteroposterior component of growth is most active in the infant monkeys, while the vertical component of growth is most active in the juvenile and young adolescent monkeys. In the current study, the horizontal growth component is more prominent than the vertical component of growth in all age groups although there is a reduction in the anteroposterior growth during successive ages. Vertical growth is dominant only in a few random animals throughout the whole sample. The conflict in these findings may be based on sample size or on cranial base superimposition. The use of implants, as described in the

current study, reveals remodeling activity in the superior position of the orbital roof, an area often used for superimposition.

An analysis of the growth and remodeling of the maxillary complex demonstrates that age and level of maturation are important when considering the normal parameters of craniofacial growth in the rhesus monkey. The largest increments of growth are observed in the infant animals and are successively less in subsequent age groups. However, sexual differences were not evident in the growth rate of the younger animals. Only in adult monkeys (Group IV) did any statistically significant differences in growth rate between the sexes exist. Swindler et al. ('73) similarly have reported that there were no significant sexual differences in craniofacial dimensions in either *Papio cynocephalus* and *Macaca nemestrina*. Also Snow and Vice ('67) state that the allometric growth patterns of various viscera in *Papio anubis* are identical for both sexes, despite the disparity in ultimate total body size. Snow and Vice ('67) and Swindler et al. ('73) postulate that the relative growth rates among primates are constant while the time of growth is variable. This observation may also be applicable to *Macaca mulatta*, since in this study sexual dimorphism was evident only in the adult monkeys and resulted from a comparison between growing male and non-growing female animals. A lack of sexual dimorphism in rates of growth may be a characteristic of nonhuman primates in general.

#### ACKNOWLEDGMENTS

The authors thank M. C. McBride and Jody Ungerleider for technical assistance. Illustrations by William L. Brudon. Editorial assistance by Barbara Nesbitt.

#### LITERATURE CITED

- Björk, A. 1955 Facial growth in man, studied with the aid of metallic implants. *Acta odont. Scand.*, 13: 9-34.
- 1966 Sutural growth of the upper face studied by the metallic implant method. *Acta odont. Scand.*, 24: 109-129.
- 1968 The use of metallic implants in the study of facial growth in children: method and application. *Amer. J. Phys. Anthrop.*, 29: 243-254.
- Björk, A., and V. Skieller 1972 Facial development and tooth eruption. *Amer. J. Orthodont.*, 62: 339-383.

- Duterloo, H. S., and D. H. Enlow 1970 A comparative study of cranial growth in *Homo* and *Macaca*. *Am. J. Anat.*, 127: 357-368.
- Elgoyhen, J. C., M. L. Riolo, L. W. Graber, R. E. Moyers and J. A. McNamara, Jr. 1972 Craniofacial growth in juvenile *Macaca mulatta*: a cephalometric study. *Amer. J. Phys. Anthropol.*, 36: 369-376.
- Enlow, D. H. 1965 Mesial drift as a function of growth. *Symp. on Growth, Univ. West Indies, West Indian Med. J.*, 14: 124.
- 1966 A comparative study of facial growth in *Homo* and *Macaca*. *Amer. J. Phys. Anthropol.*, 24: 293-307.
- 1968 *The Human Face*. Harper and Row, New York, New York.
- Enlow, D. H., and S. Bang 1965 Growth and remodeling of the human maxilla. *Amer. J. Orthodont.*, 51: 446-464.
- Enlow, D. H., and J. A. McNamara, Jr. 1973 Varieties of *in vivo* tooth movements. *Angle Orthodont.*, 43: 216-217.
- Erickson, L. C. 1958 Facial growth in the Macaque monkey: a longitudinal cephalometric roentgenographic study using metallic implants. M. S. Thesis, University of Washington, Seattle, Washington.
- Gans, B. J., and B. G. Sarnat 1951 Sutural facial growth of the *Macaca rhesus* monkey: a gross and serial roentgenographic study by means of metallic implants. *Amer. J. Orthodont.*, 37: 827-841.
- Hurme, V., and G. Van Wagenen 1953 Basic data on the emergence of permanent teeth in the rhesus monkey (*Macaca mulatta*). *Proc. Amer. Philo. Soc.*, 97: 291-315.
- 1961 Basic data on the emergence of permanent teeth in the rhesus monkey (*Macaca mulatta*). *Proc. Amer. Philo. Soc.*, 105: 105-140.
- McNamara, J. A., Jr. 1972 Neuromuscular and skeletal adaptations to altered orofacial function. Monograph No. 1, Craniofacial Growth Series, Center for Human Growth and Development, The University of Michigan, Ann Arbor, Michigan.
- McNamara, J. A., Jr., and L. W. Graber 1975 Mandibular growth in the rhesus monkey (*Macaca mulatta*). *Amer. J. Phys. Anthropol.*, 42: 15-24.
- Moore, A. W. 1949 Head growth of the Macaque monkey as revealed by vital staining, embedding, and undecalcified sectioning. *Amer. J. Orthodont.*, 35: 654-671.
- Pihl, E. B. 1959 A serial study of the growth of various cranial and facial bones in the macaque monkey. M. S. Thesis, University of Washington, Seattle, Washington.
- Schultz, A. H. 1969 Growth and development. In: *The Anatomy of the Rhesus Monkey*. C. G. Hartman and W. L. Straus, Jr., eds. Hafner Publishing Company, New York, pp. 10-27.
- Snow, C. C., and T. Vice 1967 Organ weight allometry and sexual dimorphism in the olive baboon, *papio anubis*. In: *The Baboon in Medical Research*. H. Vagtborg, ed. University of Texas Press, Austin.
- Swindler, D. R., J. E. Sirianni and L. H. Tarrant 1973 A longitudinal study of cephalofacial growth in *Papio cynocephalus* and *Macaca nemestrina* from three months to three years. *Symp. IVth Int. Cong. Premat.*, Vol. 3: Craniofacial Biology of Primates. Karger, Basel, pp. 227-240.