



# Finite-element morphometry of soft tissues in prepubertal Korean and European–Americans with Class III malocclusions

G.D. Singh<sup>a,\*</sup>, J.A. McNamara Jr<sup>b</sup>, S. Lozanoff<sup>c</sup>

<sup>a</sup>*Dundee Dental Hospital and School, University of Dundee, Park Place, Dundee, DD1 4HR, Scotland, UK*

<sup>b</sup>*Department of Orthodontics and Pediatric Dentistry, School of Dentistry and Center for Human Growth and Development, University of Michigan, Ann Arbor, MI 48109-1078, USA*

<sup>c</sup>*Departments of Anatomy, Reproductive Biology and Surgery, John A. Burns School of Medicine, University of Hawaii, 1960 East-West Road, HI 96822, USA*

Accepted 5 January 1999

## Abstract

The purpose was to test the hypothesis that soft-tissue morphology differs consistently in people of diverse ethnic origin exhibiting Class III malocclusions. Lateral cephalographs of 70 Korean and 71 European–American children aged between 5 and 11 years were traced and 12 homologous, soft-tissue landmarks digitized. The total sample was subdivided into seven age- and sex-matched groups, and Procrustes superimposition was used to generate average geometries scaled to an equivalent size. Statistical differences were tested by ANOVA. Graphical analysis using a colour-coded finite-element (FEM) program was used to localize differences in morphology. Procrustes' results indicated that the overall mean Korean and European–American soft-tissue configurations differed statistically ( $p < 0.001$ ), and this difference was also true in all seven age groups tested ( $p < 0.001$ ). On comparing mean Korean and European–American Class III soft-tissue configurations for local size change, FEM analysis revealed that whereas the Korean mental regions generally were smaller (approx. 43% on average), local increases in size were apparent for the lower lip (approx. 29% on average). For shape change, the mean Korean and European–American soft-tissue configurations were fairly isotropic except in the region of the columella, lower lip and the anterior part of the mental region. Features of the soft-tissue integument in individuals of diverse ethnic origins appear to be associated with the underlying skeletal Class III morphology. © 1999 Elsevier Science Ltd. All rights reserved.

*Keywords:* Cephalometric; Class III; Craniofacial; Korean; Finite-element morphometry; Soft tissue

## 1. Introduction

Although Class III malocclusions show a relatively low prevalence of approx. 1–4% in European–American populations (Kelly et al., 1973; Kelly and Harvey, 1977; Van Vuuren, 1991), their prevalence is apparently higher in South-East Asian populations. For example, Yang (1990) discovered that approx.

*Abbreviations:* FEM, finite-element morphometry.

\* Corresponding author. Tel: + 44 (0) 138 263 5989; Fax: + 44 (0) 138 263 5998.

*E-mail address:* g.d.singh@dundee.ac.uk (G.D. Singh)

50% of orthodontic patients in Korea sought treatment for Class III malocclusions. Similarly, Kameda (1982) noted mandibular protrusion in about 50% of orthodontic patients in Japan. Mak (1969) found a Class III prevalence of approx. 20% in Hong Kong Cantonese children, while Tang (1994) reported that some 15% of male Hong Kong Chinese exhibited Class III malocclusions. In an earlier study, Johnson et al. (1978) discovered that 23% of Chinese children had Angle's Class III malocclusions. Therefore, it appears that Class III malocclusions are prevalent to a greater degree in South-East Asian populations. The increased prevalence in those populations is likely to be genetically determined but the skeletal features of South-East Asian children with Class III malocclusions have not been considered extensively in the English-language literature. Nevertheless, analysis of craniofacial morphology is essential in orthodontic evaluation and clinical treatments, and this is hindered as the role of craniofacial components in the aetiology of the South-East Asian Class III profile has not been fully investigated. For example, Hoffman et al. (1994) indicate that surgeons subjectively assess facial aesthetics and devise soft-tissue treatment objectives, but as there is limited information in the English-language orthodontic literature on the morphology of Korean individuals with Class III malocclusions, the effect of ethnic variations could make this task more difficult.

One way of investigating the putative association between the circumoral soft tissues and the development of Class III malocclusion would be to compare the soft-tissue matrices that might be associated with the development of the Class III condition. In a previous analysis (Singh et al. 1998a), the skeletal components of prepubertal Korean and European-American children with Class III malocclusions were contrasted. The Korean children appeared to develop Class III malocclusions because of their smaller skeletal anterior cranial base and midfacial dimensions, and a large and less favourable mandibular morphology than those of their European-American counterparts (Singh et al., 1998a). Therefore, our aim now was to investigate whether the cutaneous soft tissues reflect the underlying skeletal morphology. Rejection of the null hypothesis, that there is no difference in soft-tissue morphology in children of diverse ethnic origin with Class III malocclusions, might provide support for the view of an active role of the soft-tissue complex in the determination of final facial form. As well, the study could provide some further generic insights into the orthodontic management of the prepubertal South-East Asian child presenting for treatment of a Class III malocclusion.

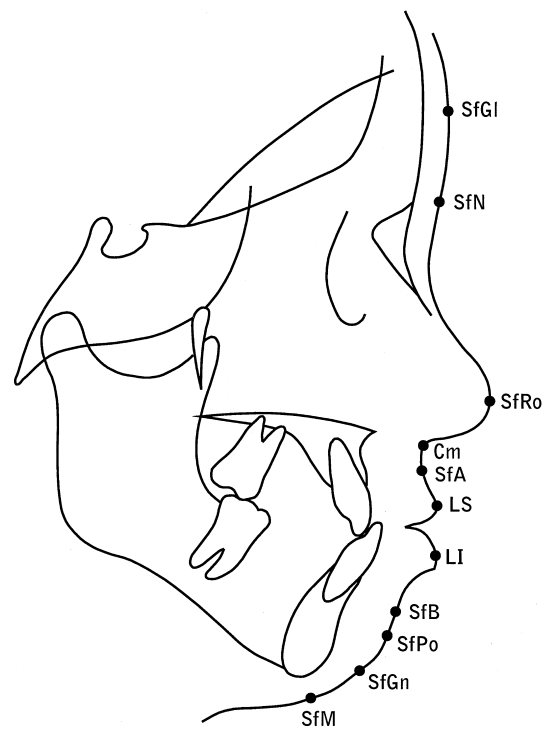


Fig. 1. Homologous soft-tissue landmarks employed in this study superimposed on a tracing of a lateral cephalograph of a Korean child with a Class III malocclusion. SfGl, soft glabella (most prominent mid-sagittal point on the forehead); SfN, soft nasion (maximum concavity overlying the frontonasal suture); SfRo, soft rhinion (most prominent point on anterior tip of the nose); Cm, columella (point of intersection of nose with philtrum of upper lip); SfA, soft sub-spinale (maximum concavity of the upper lip below the anterior nasal spine corresponding to point A); LS, labial superioris (maximum mid-sagittal convexity on the upper lip); LI, labial inferioris (maximum mid-sagittal convexity on the lower lip); SfB, soft suprmentale (maximum concavity of the lower lip above menton corresponding to point B); SfPo, soft pogonion (most anterior point directly opposite pogonion); SfGn, soft gnathion (most anterior-inferior point directly opposite gnathion); SfM, soft menton (inferior-most point directly opposite menton).

## 2. Materials and methods

After obtaining appropriate consent, pretreatment lateral cephalographs of 71 European-American subjects aged between 5 to 11 years with Angle's Class III molar malocclusion were retrieved (Guyer et al., 1986). A further 70 cephalographs of untreated Koreans with a similar Class III molar relation were also obtained from a Korean orthodontic practice. The total sample included an approximately equal number of age-matched males and females with no history of airway problems and no obvious vertical skeletal problems. It

Table 1  
Procrustes analysis of mean soft-tissue configurations of Korean and European–American Class III children

Age (years)	5	6	7	8	9	10	11	TS <sup>a</sup>
Residual	0.0035	0.0032	0.0041	0.0033	0.0039	0.0037	0.0033	0.0031
F-value	2.4509	4.0427	6.0126	6.4712	5.3563	4.0018	2.2781	25.7667
p-value	<0.001	<0.001	<0.001	<0.001	<0.001	<0.001	<0.001	<0.001

<sup>a</sup> TS is the total combined soft-tissue comparison that is significantly different at  $p < 0.001$ ; the total sample is decomposed into age groups, all age groups maintain statistical difference at  $p < 0.001$ .

was assumed that all radiographs were taken from individuals exhibiting left–right symmetry and that the central X-ray beam passed along the transmeatal axis while the teeth were in occlusion. The magnification of each film was standardized to 8%. The chronological age was assumed to match the developmental age in this study as carpal ages were unavailable.

Each lateral cephalograph was traced onto frosted acetate film (0.03" thick) and checked by one investigator (GDS). Landmark coordinates from cephalographs taped to a light box of uniform brightness were digitized using appropriate software and a digitizing tablet (Numonics Inc., Montgomeryville, PA). Twelve homologous soft-tissue landmarks were identified and digitized (Fig. 1). These landmarks encompassed the lateral facial profile and permitted the construction of the soft-tissue configurations to be studied. All films were digitized twice, and any landmarks that showed a discrepancy of >1% on duplicate digitization were deemed to be identified unreliably and were excluded from the final analyses.

Procrustes analysis was used to determine the variance around each landmark and express it as a root mean square. Each total sample was subjected to Procrustes superimposition and each group was represented as a mean and variance. The Procrustes routine was implemented on an Amiga 3000 computer, and an average 12-noded geometry for each age group was determined using a generalized orthogonal Procrustes analysis (Gower, 1975). Following this

method, every object's coordinates were translated, rotated and scaled iteratively until the least-squares fit of all configurations was no longer improved. Therefore, all configurations were registered with respect to one another, and as a result of this procedure the geometric configurations of soft-tissue landmarks were scaled to equivalent areas, avoiding problems introduced by differences in size. To determine whether soft-tissue landmark configurations differed between ethnic types and at each age interval, each European–American group mean geometry was compared statistically to the age-matched Korean group mean geometry by ANOVA (Gower, 1975). In each instance, the null hypothesis was that the European–American mean was not significantly different from the Korean. Residuals and corresponding *F*-values were computed, tabulated and compared.

In order to visualize sources of heterogeneous soft-tissue morphology, FEM analysis was undertaken (Singh et al., 1997a,b; 1998b) incorporating a spline interpolation function (Bookstein, 1991). Based on this approach, differences can be described graphically as a size and/or shape change (e.g., Singh et al., 1997a,b; 1998b, inter alia). The FEM software was written in "C" and implemented on an Amiga 3000 computer. The overall mean European–American configuration was taken as the initial geometry, and this was compared to the overall Korean mean. The mean geometries at each age interval were also compared (approx. 10 individuals per group; 5 males, 5 females).

Table 2  
FEM analysis comparing Korean and European–American Class III soft-tissue nodal values for size and shape change<sup>a</sup>

SGI	SfN	SfRo	Cm	SfA	LS	LI	SfB	SfPo	SfGn	Sfm
<i>Size</i>										
0.9582	1.0252	0.9851	0.9387	0.9151	0.8013	1.1877	1.2127	0.6342	0.6253	0.5908
<i>Shape</i>										
1.0124	1.0082	1.0016	1.0086	1.0310	1.0014	1.0415	1.0632	1.0472	1.0096	1.0001

<sup>a</sup> Size-change variables indicate little change for the upper two-third of the face (SGI–SfA), slight diminution of the upper lip (LS) with increased values for the lower lip (LI–SfB) but marked decreases in size for the Korean soft-tissue chin region (SfPo–Sfm). Shape-change variables indicate little heterogeneity. Note that internodal values were calculated for at least 2000 points per geometry.

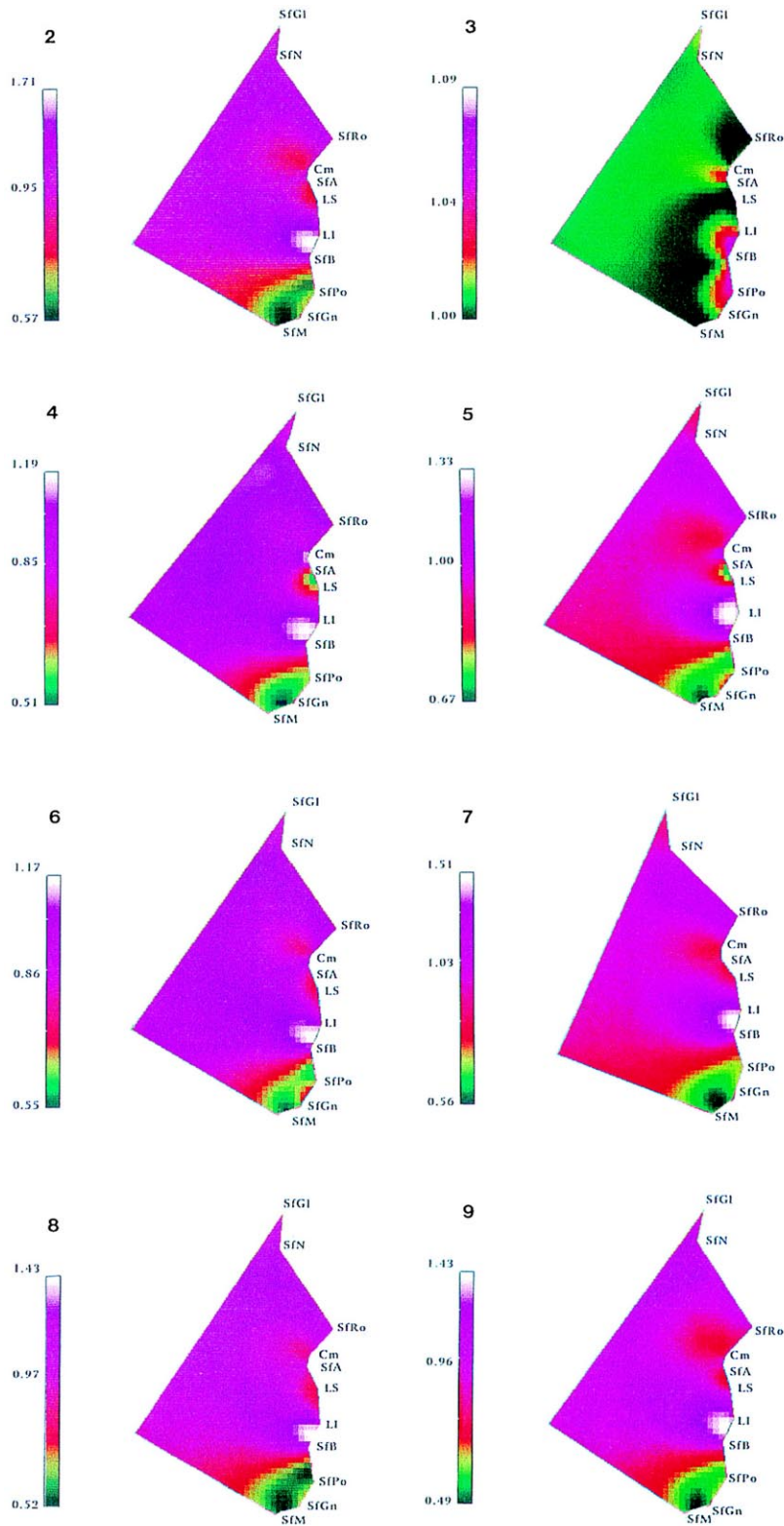


Fig. 2. Size change using FEM to compare mean overall Class III soft-tissue configurations: Korean mental region is approx. 40% smaller but lower lip is approx. 29% larger than mean European–American configuration.

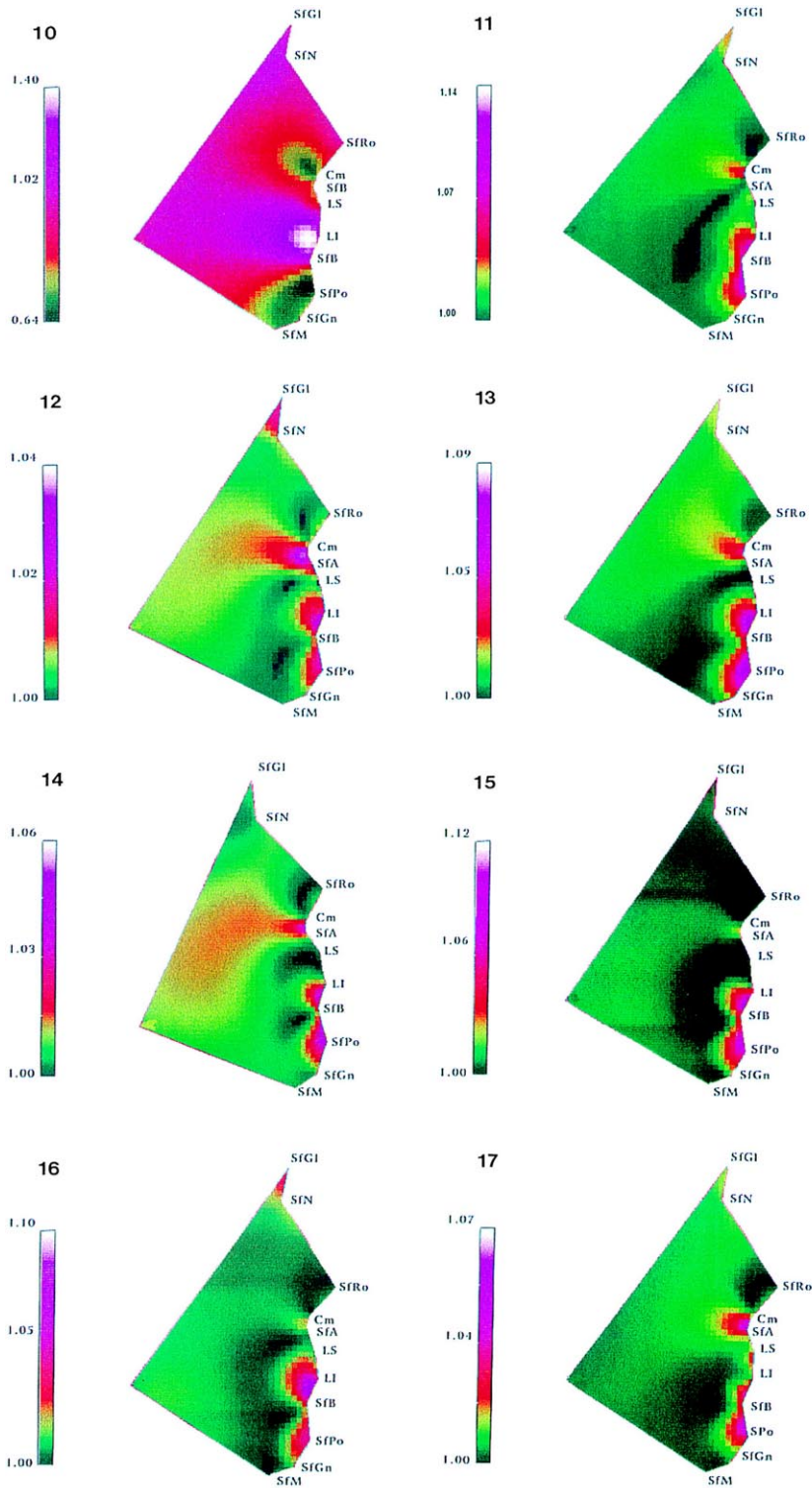


Fig. 3. For shape change, mean Korean and European–American soft-tissue comparison is predominantly isotropic. Minor degrees of anisotropy (approx. 5%) are localized in the lower lip, columella, and anterior part of the mental region.

Table 3  
FEM analysis comparing Korean and European–American Class III soft-tissue nodal values for size differences

Age (years)	Mental region % decrease	Lower lip % increase
5	50	20
6	30	30
7	50	15
8	45	50
9	50	40
10	50	40
11	35	40

Therefore, eight comparisons were generated in total, and deformation values were computed for at least 2000 points per geometry for graphical display. A log-linear interpolation of the size and shape values was used to generate a colour map. These form-change measures were then colour-mapped into each European–American configuration to provide graphical displays of geometrical change for the overall and each age-wise comparison.

### 3. Results

ANOVA demonstrated no statistical differences for sex, so the males and females were combined into a single group. Residuals from the overall Procrustes analysis and those at each age are shown in Table 1. Statistically significant differences between the mean Korean and European–American Class III soft-tissue configurations occurred at  $p < 0.001$  for the total sample. When the total sample was decomposed over the seven age intervals, the comparisons maintained statistical significance at  $p < 0.001$  for all age groups tested.

Fig. 2 demonstrates size change using FEM to compare mean overall Korean and European–American Class III soft-tissue configurations. Size-change variables for the overall comparison (Table 2) indicated that the Korean mental region generally was smaller (approx. 40%), but increases in size were apparent for the lower lip (approx. 29%). For shape change (Table 2 and Fig. 3), the Korean and European–American soft-tissue configurations were fairly isotropic (invariant with respect to direction, i.e., uniformity in the nature of the shape change) with minor degrees of anisotropy (nonhomogeneity with respect to direction, i.e., directionality evident in the nature of the shape change) localized in the regions of the columella, lower lip and the anterior part of the mental region. Decomposition of the sample into the seven age- and sex-matched groups revealed that a similar pattern of size change emerged for the Korean children (Table 3).

For shape change, the overall mean comparison and the 5 to 11-year-old age groups were similar (Fig. 3). The majority of the soft-tissue configurations were isotropic, with evidence of anisotropy restricted to the columella, lower labial and soft mental regions in the Korean configurations. For the age groups compared, although the range of anisotropy differed in various regions of the facial mesh in these configurations, the degree of anisotropy was remarkably similar over the age range studied. Therefore, it appears that a combination of reduced soft tissue in the mandibular symphyseal region allied with lower-lip protrusion distinguishes the Korean Class III soft-tissue lateral profile from the European–American Class III facial nodal mesh.

### 4. Discussion

In the assessment of facial form and form change, modern geometric morphometrics are appropriate techniques as they permit a more rigorous analysis of shape and size change. For example, Richtsmeier and Cheverud (1986) and Lozanoff and Diewert (1989) noted that decomposition of morphological integration is possible using FEM. Therefore, the application of FEM is warranted in the analysis of craniofacial growth (Motoyoshi et al., 1989). But Ferrario et al. (1995a) noted that shape similarities largely can be overwhelmed by size differences, and Lele (1993) has highlighted the problems of using Procrustes analysis as a statistical tool. In a previous study, Procrustes' results were corroborated through other statistical tests including linear measures and Euclidean distance matrix analysis (Singh et al., 1998a). It was, therefore, essential to scale the configurations to equivalent size before investigating local shape and size changes to derive meaningful comparisons.

In this study, the sexes were combined as the sample was relatively small. That this appears to be permissible is gleaned from the three-dimensional morphometry of adult cutaneous facial landmarks. Ferrario et al. (1996a) employed two infrared camera-coupled devices to reconstruct the facial soft-tissue complex, noting no significant sex differences. Thus, combining sexes in the 5 to 11-year age range generally is satisfactory because of the only modest sexual dimorphism of craniofacial structures present at these prepubertal ages (Riolo et al., 1974). Therefore, morphological differences detectable by FEM with the use of combined samples consisting of prepubertal boys and girls appears to depict ethnic, presumably genetic, craniofacial heterogeneity. Despite these findings, neither automated landmark detection nor study of experimental error was possible here, even though FEM is sensitive to small changes in landmark location (Ayoub and Stirrups, 1993).

Variation in soft-tissue facial form in association with ethnicity is expected a priori. Given the underlying skeletal morphologies of the Class III Korean and European–American child (Guyer et al., 1986; Singh et al., 1998a), it appears that midfacial retrusion may or may not be associated with soft-tissue dynamics when change in form from the Class I to the Class III condition is investigated. Korean children appear to develop Class III malocclusions because of their smaller skeletal anterior cranial base and midfacial dimensions than those of their Class III European–American counterparts (Singh et al., 1998a). But form differences in midfacial soft tissues do not appear to be evident when diverse ethnic groups with Class III morphologies are compared (Figs. 2 and 3). We therefore suggest a passive role for the circumoral soft tissues in the aetiology of Class III malocclusion.

Ngan et al. (1997) compared Chinese and Caucasian Class III patients and noted ethnic differences: for example, the soft-tissue mandibular prognathism and lower-lip protrusion reflected the more severe underlying skeletal disharmony in the Chinese sample. Singh et al. (1998a) reported that Korean children appear to develop Class III malocclusions because of a large and less favourable mandibular morphology than that of their Class III European–American counterparts. But, in the current study, the Korean Class III children appear to have smaller symphyseal soft tissues than their American Class III counterparts. Given the underlying Korean Class III skeletal mandibular morphology (Singh et al., 1998a), it appears that the symphyseal soft tissues do not reflect skeletal configuration equally when ethnicity is taken into account, in contrast with some of the findings of Ngan et al. (1997). The concept of a passive role or hypofunction of the mental soft tissues (Seren, 1990) is, however, supported by our FEM analysis.

Further analysis revealed that lower-lip protrusion was detectable in the Korean Class III children, and this feature may reflect the anterior crossbite indicative of Class III malocclusion in South-East Asian children, in support of some of the findings of Ngan et al. (1997). Miyajima et al. (1997) have catalogued differences in soft-tissue lip profile in untreated Class III Japanese females with anterior crossbites. But Bittner and Pancherz (1990) report that while a large overjet (Class II malocclusion) was most often reflected in the face, a Class III incisor relation was difficult to detect. It also is likely that tongue shape, size and/or protrusion will affect the labial position of the lower incisors (visualized as lower-lip protrusion for the Class III Korean child), but this feature was not investigated here. Another feature of the Class III condition is a diminished convexity of the profile of the soft tissues (Rak, 1989). This flattening of the facial profile may be

enhanced in the Korean child, bearing in mind the form of the lower lip, the reduced size of the mental region, and an obtuse (skeletal) frontonasal angle (Singh et al., 1998a). Therefore, Miyajima et al. (1996) correctly predicted that a single standard of facial aesthetics is not appropriate for application to diverse ethnic groups.

Zeng (1992) suggests that the rate of developing a skeletal Class III malocclusion for Japanese patients with a positive family background is not higher than for those with a negative one. This finding implies that the epigenetic influence of the soft-tissue matrix could have a bearing upon the final facial form. Indeed, facial soft-tissue size and shape is influenced by factors such as age, sex and skeletal classification to a lesser extent. Using soft-tissue landmarks, noted that the upper third of the face had the largest variability and that the sexual dimorphism largely was explained by the lower third of the face. In our current, limited, cross-sectional study, it appears that the soft-tissue matrices are established at an early postnatal age and that the developmental pattern does not change significantly when prepubertal Class III Korean children and their European–American counterparts are compared. Discrepancies in the mental and lower-lip regions might become more evident in the postpubertal stage but this hypothesis requires further study. Morphofunctional re-equilibration of skeletal Class III malocclusions is, however, implied as one of the keys to the resolution of this complex condition (Nidoli et al., 1990). proposed a computerized mesh-diagram analysis to assess modifications in facial form after orthodontic interventions. In future studies the outcome of orthodontic interventions will be assessed by FEM to determine whether Korean and European–American children have similar soft-tissue morphologies after orthodontic correction of Class III malocclusions.

### Acknowledgements

This study was supported by the Wellcome Trust (UK), the Queens Medical Research Foundation and the Medical Research Council (Canada). We would like to thank Dr Y.G. Choi for supplying the lateral cephalographs of Korean children.

### References

- Ayoub, A.F., Stirrups, D.R., 1993. The practicability of finite-element analysis for assessing changes in human craniofacial morphology from cephalographs. *Archs Oral Biol* 38 (8), 679–683.
- Bittner, C., Pancherz, H., 1990. Facial morphology and mal-

- occlusions. *Am. J. Orthod. Dentofac. Orthop* 97 (4), 308–315.
- Bookstein, F.L., 1991. *Morphometric tools for landmark data*. Cambridge University Press, Cambridge.
- Ferrario, V.F., Sforza, C., Schmitz, J.H., Miani Jr, A., Taroni, G., 1995. Fourier analysis of human soft tissue facial shape: sex differences in normal adults. *J. Anat* 187 (3), 593–602.
- Ferrario, V.F., Sforza, C., Poggio, C.E., Serrao, G., 1996. Facial three-dimensional morphometry. *Am. J. Orthod. Dentofac. Orthop* 109 (1), 86–93.
- Gower, J.C., 1975. Generalised Procrustes analysis. *Psychometrika* 40, 33–51.
- Guyer, E.C., Ellis, E., McNamara Jr, J.A., Behrents, R.G., 1986. Components of Class III malocclusion in juveniles and adolescents. *Angle Orthod* 56, 7–30.
- Hoffman, G.R., Staples, G., Moloney, F.B., 1994. Cephalometric alterations following facial advancement surgery. 2. Clinical and computerised evaluation. *J. Craniomaxillofac. Surg* 22 (6), 371–375.
- Johnson, J.S., Soetamat, A., Winoto, N.S., 1978. A comparison of some features of the Indonesian occlusion with those of two other ethnic groups. *Brit. J. Orthod* 5, 183–188.
- Kameda, A., 1982. The Begg technique in Japan. *Am. J. Orthod* 81, 209–227.
- Kelly, J.E., Sanchez, M., Van Kirk, L.E., 1973. An assessment of the occlusion of the teeth of children, DHEW Publication No (HRA) 74-1612 National Center for Health Statistics, Washington, DC.
- Kelly, J.E., Harvey, C., 1977. An assessment of the teeth of youths 12–17 years, DHEW Publication No (HRA) 77-1644 National Center for Health Statistics, Washington, DC.
- Lele, S., 1993. Euclidean distance matrix analysis (EDMA): estimation of mean form and mean difference. *Math. Geol* 25, 573–602.
- Lozanoff, S., Diewert, V.M., 1989. A computer graphics program for measuring two and three-dimensional form change in developing craniofacial cartilages using finite elements. *Comp. Biomed. Res* 22, 63–82.
- Mak, K.L., 1969. An analysis of treated orthodontic patients in Hong Kong. *Dent. Mag* 86, 258–259.
- Miyajima, K., McNamara Jr, J.A., Kimura, T., Murata, S., Iizuka, T., 1996. Craniofacial structure of Japanese and European–American adults with normal occlusions and well-balanced faces. *Am. J. Orthod. Dentofac. Orthop* 110, 431–438.
- Miyajima, K., McNamara Jr, J.A., Sana, M., Murata, S., 1997. An estimation of craniofacial growth in the untreated Class III female with anterior crossbite. *Am. J. Orthod. Dentofac. Orthop* 112 (4), 425–434.
- Motoyoshi, M., Yamazaki, T., Inoue, K., Akano, Y., Lin, M., Namura, S., 1989. Application of the finite element method to craniofacial growth analysis. 4. Three-dimensional application of tensor analysis. *Nippon Kyosei Shika Gakkai Zasshi* 48 (5), 521–534.
- Ngan, P.W., Hagg, U., Yiu, C., Merwin, D., Wei, S.H., 1997. Cephalometric comparisons of Chinese and Caucasian surgical Class III patients. *Int. J. Adult Orthod. Orthog. Surg* 12 (3), 177–188.
- Nidoli, A., Lazzati, L., Macchi, A., 1990. Interceptive therapy of Class III. *Riv. Ital. Odontoiatr. Infant* 1 (2), 37–45.
- Rak, D., 1989. Cephalometric analysis in cases with Class III malocclusions. *Stomatol. Glas. Srb* 36 (4), 277–287.
- Richtsmeyer, J.T., Cheverud, J.M., 1986. Finite element scaling analysis of human craniofacial growth. *J. Craniofac. Genet. Dev. Biol* 6, 289–323.
- Riolo, M.L., Moyers, R.E., McNamara, J.A., Hunter, W.S., 1974. An atlas of craniofacial growth. In: *Monograph no 2 Craniofacial growth series Center for Human Growth and Development*. University of Michigan, Ann Arbor.
- Seren, E., 1990. EMG investigation on mentalis, masseter and OOS muscles of adults with Class III malocclusion. *Turk. Ortodonti Derg* 3 (1), 85–93 (in Turkish).
- Singh, G.D., McNamara Jr, J.A., Lozanoff, S., 1997a. Finite element analysis of the cranial base in subjects with Class III malocclusion. *Brit. J. Orthod* 24, 103–112.
- Singh, G.D., McNamara Jr, J.A., Lozanoff, S., 1997b. Finite element morphometry of the midfacial complex in subjects with Angle's Class III malocclusions. *J. Craniofac. Genet. Devel. Biol* 17 (3), 112–120.
- Singh, G.D., McNamara Jr, J.A., Lozanoff, S., 1998a. Craniofacial heterogeneity of prepubertal Korean and European–American subjects with Class III malocclusions: Procrustes, EDMA and cephalometric analyses. *Int. J. Adult Orthod. Orthog. Surg* 13 (3), 227–240.
- Singh, G.D., McNamara Jr, J.A., Lozanoff, S., 1998b. Mandibular morphology in subjects with Angle's Class III malocclusion: finite-element morphometry. *Angle Orthod* 68 (5), 409–418.
- Tang, E.L., 1994. The prevalence of malocclusion amongst Hong Kong male dental students. *Brit. J. Orthod* 21, 57–63.
- Van Vuuren, C., 1991. A review of the literature on the prevalence of Class III malocclusion and mandibular prognathic growth hypotheses. *Aust. Orthod. J* 12, 23–28.
- Yang, W.S., 1990. The study on the orthodontic patients who visited department of orthodontics, Seoul National University Hospital. *Taehan Chikkwa Uisa Hyophoe Chi* 28, 811–821.
- Zeng, X.L., 1992. The relationship between family background and craniofacial morphology in Class III malocclusions. *Chung Hua Kou Chiang Hsueh Tsa Chih* 27 (2), 77–80.