

Finite-element morphometry of soft tissue morphology in subjects with untreated Class III malocclusions

G. D. Singh, BDS, PhD; J. A. McNamara Jr, DDS, PhD; S. Lozanoff, PhD

Abstract: Soft tissue dynamics may contribute to maxillomandibular allometry (size-related changes in shape) associated with the development of Class III malocclusions. Lateral cephalographs of 124 prepubertal European American children were traced and 12 soft tissue landmarks were digitized. Resultant geometries were normalized, and Procrustes analysis established the statistical difference ($p < 0.001$) between mean Class III and Class I configurations. Comparing the Class III configurations with normals for size-change, color-coded finite element analysis revealed a superoinferior gradient of positive allometry of the Class III facial nodal mesh. A conspicuous area of negative allometry ($\approx 40\%$) was localized near soft subspinale, with a $\approx 70\%$ increase in size in the mental region. For shape-change, the Class III facial mesh was isotropic, except in the anisotropic circumoral regions. Conventional cephalometry revealed that about 50% of linear and 75% of angular parameters differed statistically ($p < 0.001$). Soft tissue dynamics during early postnatal development may contribute to the development of Class III malocclusions.

Key Words: Class III, Finite-element, Soft tissues, Morphology, Morphometry

One of the most important aspects of orthodontic treatment planning is an evaluation of the soft tissue profile.^{1,2} The interdependence of muscle activity and craniofacial morphology suggests a contribution from the musculature to the development of occlusion.³ Although muscle tonicity may differ between surgical and non-surgical patients,⁴ it is conceivable that true (skeletal) and acquired (surgically induced) Class III malocclusions may result from the activity of the circumoral musculature. For example, Bardach et al.⁵ tested the hypothesis that cleft lip repair contributes to maxillofacial growth aberrations. They found that undermining the soft tissue of the upper lip on the surface of the maxilla was detrimental to maxillofacial growth in beagles. Similarly, Kapucu et al.⁶ studied the effect of cleft lip repair on maxillary morphology in patients with unilateral complete cleft lip and palate and noted significant degrees of maxillary retrusion (acquired Class III malocclusion) compared with normal individuals. Earlier, for Class III orthodontic patients,

Fränkel^{7,8} suggested that vestibular shields and labial pads counteract the surrounding muscle forces that restrict anterior maxillary skeletal development. Indeed, relapse of an anterior crossbite following dental arch expansion in the treatment of skeletal Class III malocclusions may be due to an increase in labial soft tissue pressure, resulting in postoperative instability. Therefore, it is conceivable that circumoral soft tissue pressure could act as a factor in anteroposterior maxillomandibular allometry (size-related shape-change).

One of the goals in treating Class III malocclusion is to improve the dentofacial profile.⁹ In the study of the interrelationships of the soft tissue and dentoskeletal profiles, size plays a distorting role because it can mask shape-change.¹⁰ Geometric morphometrics, such as finite element morphometry (FEM), allow a more rigorous analysis of allometry and anisotropy. (Anisotropy describes nonhomogeneity with respect to directionality of shape-change, e.g., a circle transforming into an ellipse.) In previous studies of the skeletal etiology of Class III

Author Address

G. D. Singh, BDS, Ph,D
Dundee Dental Hospital and School
University of Dundee
Park Place, Dundee DD1 4HR
Scotland, UK

E-mail: g.d.singh@dundee.ac.uk

G. D. Singh, Dundee Dental Hospital and School, University of Dundee, Park Place, Dundee, Scotland, UK

J. A. McNamara Jr., Dept. of Orthodontics and Pediatric Dentistry, School of Dentistry, and Center for Human Growth and Development, The University of Michigan, Ann Arbor.

S. Lozanoff, Depts. of Anatomy, Reproductive Biology and Surgery, John A. Burns School of Medicine, University of Hawaii, Honolulu.

Submitted: December 1997, **Revised and accepted:** August 1998

Angle Orthod 1999;69(3):215-224.

malocclusions, FEM has been employed to demonstrate allometry and anisotropy of the cranial base,¹¹ the midface,¹² and the mandible.¹³ Recently, there has been renewed interest in facial soft tissue harmony¹⁴ and the psychological aspects of dentofacial attractiveness.¹⁵⁻¹⁷ Rak¹⁸

described a diminished convexity of the soft tissue profile in boys and girls with Class III malocclusions, but account should be taken of sexual dimorphism as this feature is evident for soft tissue measurements.¹⁹ Such discrepancies may be age-related phenomena; during the pubertal growth spurt, soft tissue changes emphasize the nose and chin more prominently.²⁰ Nevertheless, the soft tissue profile may simply reflect the underlying hard tissues. A close correlation is thought to exist between soft tissue landmarks and the underlying skeletal and dental structures.²¹

In an extensive study of Japanese females, Miyajima et al.²² reported that, in Class III patients, the underlying skeletal and dentoalveolar imbalances were reflected in the soft tissue profile, and the average value for the nasolabial angle remained similar across developmental stages. Indeed, when the relative movement of the soft and hard tissues are assessed after mandibular surgery for the correction of Class III malocclusion, the soft tissues are found to consistently move slightly less than the underlying hard tissues.²³ Similarly, in the evaluation of postoperative stability of combined surgical-orthodontic procedures, mandibular soft tissue points followed relapse of the chin to the same extent.²⁴ Therefore, the perioral soft tissue pattern might follow the skeletal morphology, regardless of other dimorphic parameters. The aim of the current study was to employ geometric morphometrics and conventional cephalometry to compare the facial soft tissue profiles between Class I and Class III malocclusion. By examining the patterns of deformation of

the soft tissue facial nodal mesh of normal and maloccluded children, we might be able to demonstrate changes in soft tissue morphology discernible for the two groups of children and indicate graphically the soft tissue dimorphism of the Class III condition.

Materials and methods

The total sample employed in this study comprised 124 children of European American descent between the ages of 5 and 11 years. Seventy-one subjects with untreated Class III molar occlusion²⁵ were compared with 53 children with normal, Class I molar relationship over seven age intervals. The total cross-sectional sample included an approximately equal number of males and females, each with a negative history of airway problems and no obvious vertical skeletal discrepancies. Chronological ages were assumed to match developmental ages in this study, as carpal radiographs were unavailable. Therefore, the total sample consisted of seven age- (5, 6, 7, 8, 9, 10, 11 years) and sex-matched groups for each occlusal type (Class I, Class III), consisting of ≈10 Class III individuals and ≈7 Class I individuals per group, respectively.

The magnification of each lateral cephalograph was standardized to an 8% enlargement factor. It was presumed that all radiographs were taken from patients exhibiting left-right symmetry and that the central X-ray passed along the transmeatal axis while the teeth were in occlusion. Each lateral cephalograph was traced on frosted acetate film (0.03" thick) by one investigator (GDS). To increase the reliability of the soft tissue landmarks selected, cephalographs were taped to a light box of uniform brightness in a darkened room and digitization was achieved using a cross-wires cursor. Twelve homologous soft tissue landmarks on the lateral profile of the face were identified and digitized (Figure 1),

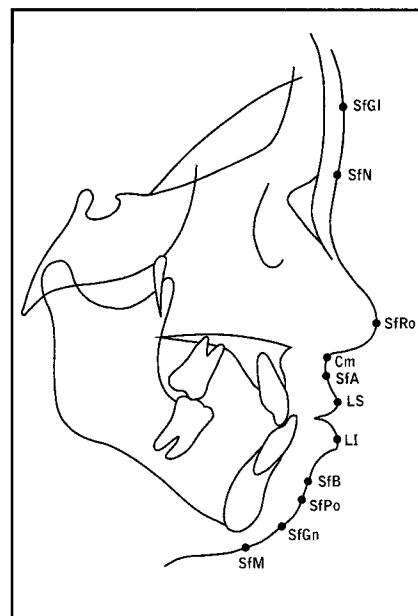


Figure 1
Homologous soft tissue landmarks employed in this study superimposed on a tracing of a lateral cephalograph of a subject with a Class III malocclusion

- SfGl Soft glabella (most prominent midsagittal point on the forehead)
- SfN Soft nasion (maximum concavity overlying the frontonasal suture)
- SfRo Soft rhinion (most prominent point on anterior tip of the nose)
- Cm Columella (point of intersection of nose with the philtrum of the upper lip)
- SfA Soft subspinale (maximum concavity of the upper lip below the anterior nasal spine corresponding to A-point)
- LS Labrale superius (maximum midsagittal convexity on the upper lip)
- LI Labrale inferius (maximum midsagittal convexity on the lower lip)
- SfB Soft supramentale (maximum concavity of the lower lip above menton corresponding to B-point)
- SfPo Soft pogonion (most anterior point directly opposite pogonion)
- SfGn Soft gnathion (most anteroinferior point directly opposite gnathion)
- SfM Soft menton (most inferior point directly opposite menton)

employing appropriate software and a digitizing tablet (Numonics Inc, Montgomeryville, Pa). These landmarks showed a discrepancy of <1% on duplicate digitization and were deemed to be identified reliably, but neither landmark reidentification nor automated landmark detection were employed.

Procrustes superimposition (the construction of a two-form superimposition by a least-squares method) was employed to determine whether soft tissue landmark configurations differed between occlusal types at each age interval. The Procrustes routine was implemented on an Amiga 3000 computer and an average 12-noded geometry for each age group was determined using a generalized orthogonal Procrustes analysis.²⁶⁻²⁸ Following this method, every object's coordinates were translated, rotated, and scaled iteratively until the least-squares fit of all configurations was no longer improved. Therefore, all configurations were registered with respect to one another, and as a result, geometric configurations of soft tissue landmarks were scaled to equivalent areas, avoiding problems introduced by differences in size. Each Class I group mean geometry was compared statistically with the age-matched Class III group average geometry using an analysis of variance.^{26,28} In each instance, the null hypothesis was that the Class I mean was not significantly different from the Class III average. Residuals and corresponding *F*-values were computed, tabulated, and compared.

In order to validate the source(s) of heterogeneous soft tissue morphology, FEM analysis that incorporated a spline interpolation function³⁰ was undertaken.^{11,12,13,29} The method employed is briefly summarized here. An anatomical structure is defined as a structural continuum bounded by homologous landmarks or nodes. Change in form is viewed as a continuous deformation of an initial ref-

Soft tissue linear variables (mm)	Soft tissue angular variables (o)
SfN-SfRo	SfN-SfRo-Cm
SfRo-Cm	SfRo-Cm-SfA
Cm-SfA	Cm-SfA-LI
SfA-LI	LI-SfB-SfPo
LI-SfB	
SfB-SfPo	
SfGn-SfM	

erence geometry into a final configuration. The magnitude and direction of strain is calculated based on this deformation and provides a simple numeric description of change in form. Any two-dimensional deformation can be quantified as a major and a minor strain (principal strains). If the two strains are equal, the form change is characterized by a simple increase or decrease in size. For example, if a circle enlarges, then the diameter of the circle increases by a constant amount but the geometry remains unchanged, i.e., it remains a circle. If, however, only one of the principal strains changes, then the circle deforms into an ellipse, changing in both size and shape. Therefore, form change can be characterized as a size and/or shape change by examining the principal strains.

As the product of the strains indicates a change in size, a product not equal to 1 represents a size change equal to the remainder, e.g., 1.60 represents a 60% increase in size (positive allometry), whereas 0.90 represents a 10% decrease in size. Similarly, a shape change is determined by the ratio of the principal extensions, with a value different from 1 representing observable shape change. The ratio of the diameter change represents a change in anisotropy (nonuniform shape change), e.g., 1.60 deforms a circle into an ellipse. The products and ratios can be determined at individual points within a geometry, linearized, and color-coded to provide a graphic display of size- and shape-change for geometrical deformation. In order to

perform FEM on a sample of subjects, landmark configurations must be processed to achieve a mean form representing a group. Procrustes analysis is one technique based on minimizing the distances between homologous landmarks for a sample of geometries. The variance around each landmark is determined and expressed as a root-mean square (RMS). Therefore, statistical analyses can be performed on the overall geometries, as each group is represented as a mean and variance. Based on this approach, groups can be determined to be statistically different from one another using Procrustes analysis. This difference can be described graphically as a size- and/or shape-change using FEM.

The total Class I configuration was taken as the initial geometry, and this configuration was compared with the Class III mean. The geometries for each age group were also compared. Eight comparisons were generated in total, and deformation values were computed for at least 2000 points per geometry for graphical display. A log-linear interpolation of the size- and shape-values was used to generate a color map. These form-change measures then were color-mapped into each Class I midfacial configuration to provide graphical displays of geometric change for the total and each age-wise comparison. The choice of interpolation³⁰ was arbitrary as there is no biologic justification for the deployment of a spline function; because of this, conventional cephalometry was included in the study. Therefore,

Table 2
Procrustes analysis of mean soft tissue configurations of Class I (normal) and Class III subjects. TS represents the total combined Class I and Class III comparison that is significantly different at the $p < 0.001$ level. When the total sample is decomposed into age subgroups, all age groups maintain statistical difference at the $p < 0.001$ level.

Age (yrs)	5	6	7	8	9	10	11	TS
Residual	0.0023	0.0023	0.0016	0.0016	0.0012	0.0025	0.0019	0.0015
F-value	1.7703	1.7857	1.5655	2.2512	1.4649	2.3014	1.7916	8.2585
p-value	<0.001	<0.001	<0.001	<0.001	<0.001	<0.001	<0.001	<0.001

seven linear distances (mm) between coordinates were calculated (Table 1), as well as four soft tissue angles ($^{\circ}$). By employing bivariate statistical analysis (paired *t*-tests), the battery of linear and angular parameters delineated was analyzed. This part of the study would enable comparison of the baseline data with respect to previous studies that are restricted to conventional cephalometric analysis alone.

Results

Residuals from the overall Procrustes analysis and those at each age were tabulated and compared using an *F*-distribution (Table 2). Statistically significant differences between the normal and Class III soft tissue landmark configurations occurred at $p < 0.001$ for the total sample. When the total sample was decomposed over seven age intervals, the comparisons maintained statistical significance at $p < 0.001$ for all age groups tested.

Table 3 summarizes nodal values for size- and shape-changes, using FEM to compare Class I and Class III soft tissue configurations. Size-change variables indicated little change at the nodes in the upper third of the facial drape (e.g., SfGl-SfRo) and diminution at the nodes of the midface (e.g., Cm-SfA), with increased values for nodes of the lower third of the facial profile (e.g., SfB-SfM). Shape-change variables, however, indicated little heterogeneity except for the lips (e.g., LS and LI; Table 3). Comparing the total Class III soft tissue and normal configurations for size-change graphically,

FEM revealed an overall superoinferior gradient of positive allometry of the Class III soft tissue facial nodal mesh (Fig. 2viii). Conspicuously, there was a localized area of negative allometry between the columella and labrale superius, with an epicenter based on the soft subspinale region (Fig. 2viii; $\approx 40\%$ decrease in size). In contrast, between soft supramentale and soft gnathion, an increase in size of approximately 70% was evident (Fig. 2viii). For shape-change, the Class III soft tissue facial nodal mesh was predominantly isotropic (Fig. 3viii), except for the anisotropic circumoral and labial regions, including the soft subspinale region (Fig. 3viii).

Decomposition of the sample into the seven age- and sex-matched groups revealed that at age 5 years a similar pattern of size-change emerged (Fig. 2i: $\approx 50\%$ decrease at SfA; $\approx 75\%$ increase at SfPo). Similarly, the 6-year old group (Fig. 2ii) exhibited soft subspinale diminution ($\approx 55\%$), with positive allometry ($\approx 65\%$) visible in the soft symphyseal region. The 7-year-old group (Fig. 2iii) demonstrated an almost identical pattern of soft subspinale shortening ($\approx 50\%$) and positive symphyseal allometry ($\approx 60\%$). In contrast, the 8-year-old group (Fig. 2iv) showed some nasomaxillary diminution, but negative allometry was maintained in the soft subspinale region ($\approx 25\%$) allied with positive allometry ($\approx 85\%$) in the symphyseal region, as in the other age groups.

The 9-year-old group (Fig. 2v) exhibited negative allometry ($\approx 50\%$) in

the soft subspinale region and an increase in size-change in the symphyseal region ($\approx 55\%$), similar to other age groups. The 10-year-old group (Fig. 2vi) showed a smaller negative allometry for the subspinale region (a diminution in size by some $\approx 40\%$), but the symphyseal increase in size ($\approx 75\%$) was similar to that of other age groups. Finally, the 11-year-old group (Fig. 2vii) demonstrated midfacial soft tissue foreshortening ($\approx 25\%$) and symphyseal increases ($\approx 70\%$) comparable to most other age groups.

For shape-change, the 5- to 7-year-old subgroups were similar (Figs. 3i-3iii). The majority of the soft tissue configurations were isotropic (invariant with respect to direction), with evidence of anisotropy restricted to the soft subspinale and labial regions. However, while the 8-year-old group (Fig. 3iv) exhibited anisotropic circumoral and symphyseal regions, the 9-year-old group (Fig. 3v) displayed isotropy in the symphyseal region similar to the 5- to 7-year-olds. The 10-year-old group (Fig. 3vi) was the most isotropic (uniformity of shape-change), exhibiting anisotropy of $\approx 5\%$ to 15%, confined to the labia. Finally, the 11-year-old subgroup (Fig. 3vii) demonstrated homogeneity in soft tissue shape-change, with anisotropy restricted to the labial and soft-tissue menton regions.

Table 4 shows the results of conventional cephalometry. Only three of the seven linear measurements returned statistical significance. The Class III group showed a decrease in length between columella to soft subspinale, and labrale inferius to

Table 3

FEM analysis comparing Class I and Class III soft tissue nodal values for size- and shape-change. Size-change variables indicate little change for the upper third of the face (SfGI-SfRo), diminution of the midface (Cm-SfA), and increased values for the lower third of the facial profile (SfB-SfM). Shape-change variables indicate little heterogeneity except for the lips (LS and LI). Note that internodal values were calculated for at least 2000 points per geometry

SfGI	SfN	SfRo	Cm	SfA	LS	LI	SfB	SfPo	SfGn	SfM
Size-change										
1.0406	1.0136	1.0128	0.7190	0.6106	0.9085	0.8608	1.1963	1.6660	1.4398	1.1464
Shape-change										
1.0001	1.0001	1.0008	1.0095	1.0191	1.0773	1.0745	1.0161	1.0060	1.0021	1.0047

Table 4

Summary of mean craniofacial distance (mm \pm s.d.) and angular ($^{\circ}$ \pm s.d.) measurements. Note that 3 out of 7 linear distances and 3 out of 4 angular parameters returned statistical significance. Refer to Table 1 for key.

Class I Age (yrs)	Linear measures (mm)							Angular measures ($^{\circ}$)			
	SfN-SfRo	SfRo-Cm	Cm-SfA	SfA-LI	LI-SfB	SfB-SPo	SfGn-SfM	SfN-SfRo- Cm	SfRo- Cm-SfA	Cm-SfA-LI	LI-SfB- SfPo
5	42.7	16.5	6.5	24	12.4	10.5	10.3	111	134	177	140
6	42.7	15	7	24.1	12.1	9.3	9.8	113	136	177	137
7	40.4	16	6.9	25	13.6	10.5	10.9	107	132	177	136
8	42.2	17.7	5.4	23.6	13.2	11.9	10.1	104	141	177	140
9	39.7	16.9	7.1	23.9	13.7	10.4	10.4	103	142	173	138
10	41.3	17.2	5.7	24.1	12.5	10.8	9.8	103	147	169	138
11	41.8	16.6	6.8	23.3	14.7	9.6	12.5	101	142	174	142
Mean	41.6	16.6	6.5	23.9	13.2	10.4	10.5	106	139	175	139
Std	1.1	0.9	0.7	0.5	0.9	0.9	0.9	4.3	4.9	3.1	2.1
5	39	16	3.2	26.9	10.7	15.4	11.1	106	148	159	141
6	38.7	16.6	3.6	24.7	11.1	14.8	10.4	111	148	161	148
7	41.5	16.2	4.2	25.3	11.5	14.4	10.3	102	148	156	148
8	40.7	15.5	4.5	23.8	10.8	14.3	10.4	107	151	159	147
9	41.5	15.8	4	25.3	11.1	15.5	9.7	105	149	156	145
10	44	16.8	4.1	23.1	11	15.7	10.9	105	154	151	150
11	43.8	17.2	5.4	20.7	11.4	14.2	10	106	160	152	147
Mean	41.3	16.3	4.1	24.2	11.1	14.9	10.4	106	151	156	146
Std	2.1	0.6	0.7	2	0.3	0.6	0.5	2.7	4.5	3.7	2.9
Sig.	N.S.	N.S.	$p < 0.001$	N.S.	$p < 0.001$	$p < 0.001$	N.S.	N.S.	$p < 0.001$	$p < 0.001$	$p < 0.001$

soft supramentale; but an increase in soft supramentale to soft pogonion length. In contrast, 75% of soft tissue angles were statistically different. The Class III mean values showed obtuse angulation between the tip of the nose-columella-soft subspinale, and columella-soft subspinale-labrale inferius angulation, but acute angulation between labrale inferius-soft supramentale-soft pogonion, reaching statistical difference at $p < 0.001$ when Class III and Class I forms were compared (Table 4). These findings are in accord with the geometric morphometric findings reported above.

Therefore, it appears that a combination of reduced soft tissue in the subspinale region, allied with increases in the mandibular symphyseal region, distinguish the Class III lateral profile from the normal facial nodal mesh. That these morphological differences are localized predominantly in specific maxillomandibular regions may have a bearing on the anteroposterior jaw relations associated with Class III malocclusions. Moreover, the early pattern of facial deformation was maintained up to the later postnatal stages (Table 4), suggesting that the foundation for Class III malocclusions is laid down

in early childhood and maintained in the untreated, prepubertal child.

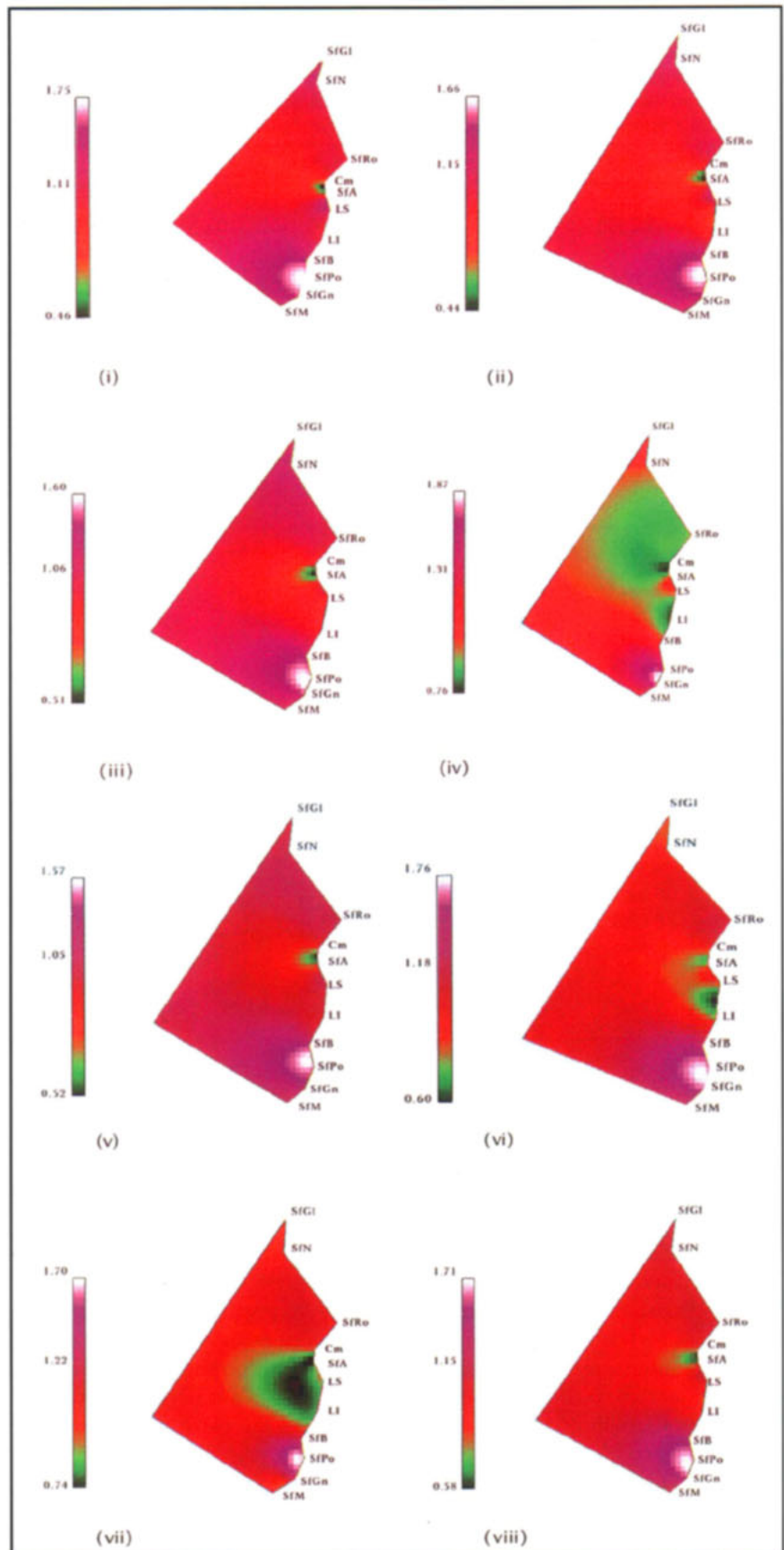
Discussion

A knowledge of normal growth will help predict soft tissue changes produced by orthodontic interventions,³² while the prediction of abnormal growth in Class III malocclusions is desirable³³ to aid orthodontic treatment planning and prevent unwanted relapse. McCance et al.³⁴ employed a color-coded method of quantifying postoperative 3-D facial bone and soft tissue movement. Their methodology, however, relied upon ratios, as the subjects were not cor-

rected for size. In view of the heterogeneity of this class of malocclusion, we based the Class III occlusal type on the molar relationship,²⁵ although other studies have adopted classifications based on cephalometric analysis,³⁵ ANB angle,³⁶ incisor relationships,³⁷ or deciduous canine relationships.³⁸ The selection criterion employed in the current study, however, was supported when tested in-

Figure 2
Size-change color maps transforming the mean soft tissue Class I geometry into the mean Class III configuration.

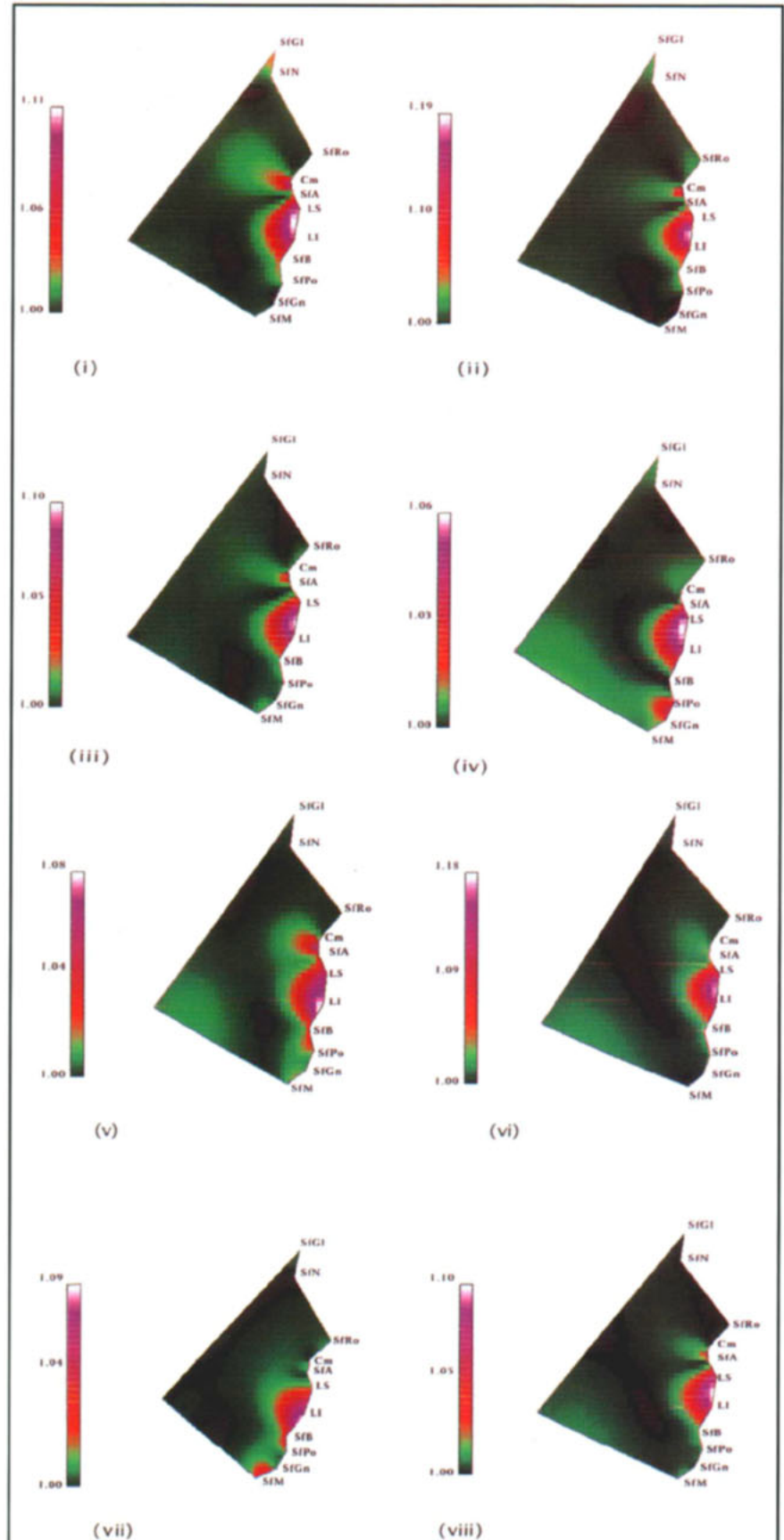
- (i) At age 5 years a $\approx 50\%$ decrease in size at SfA is conspicuous with a $\approx 75\%$ increase in size at SFPo.
- (ii) The 6-year-old comparison exhibits soft subspinale size diminution ($\approx 55\%$) with positive allometry ($\approx 65\%$) visible in the soft symphyseal region.
- (iii) The 7-year-old group demonstrates soft subspinale shortening ($\approx 50\%$) and positive symphyseal allometry ($\approx 60\%$).
- (iv) The 8-year-old group shows nasomaxillary diminution, but negative allometry is maintained in the soft subspinale region ($\approx 25\%$) allied with positive allometry ($\approx 85\%$) in the symphyseal region.
- (v) The 9-year-old group exhibits negative allometry ($\approx 50\%$) in the soft subspinale region and an increase in size-change in the symphyseal region ($\approx 55\%$).
- (vi) The 10-year-old group shows negative allometry for the subspinale region ($\approx 40\%$) but a symphyseal increase in size ($\approx 75\%$).
- (vii) The 11-year-old group demonstrates midfacial soft-tissue foreshortening ($\approx 25\%$) and symphyseal increases ($\approx 70\%$).
- (viii) Graphically comparing the total Class III soft tissue and normal configurations for size-change, FEM reveals an overall superoinferior gradient of positive allometry of the Class III soft tissue facial nodal mesh. There is a localized area of negative allometry between the columella and labrale superius, with an epicenter based upon the soft subspinale region ($\approx 40\%$ decrease in size). In contrast, between soft suprmentale and soft gnathion, an increase in size of $\approx 70\%$ is evident.



dependently of the clinical diagnosis; soft tissue landmark configurations determined by Procrustes analysis differed between the two occlusal types independently of the clinical diagnosis. One limitation of the Procrustes analysis is that, although variance at landmarks is depicted, no interlandmark information is available. For this reason, FEM analyses also were employed. Bookstein,²⁴ however, raised concerns regarding the use of FEM for configurations of more than three landmarks, one of the problems being the choice of triangles. Others,^{9,39,40} however, have shown that the reliability of pooled data is satisfactory for intergroup FEM comparisons. Indeed, using FEM for graphical analysis avoids

Figure 3
Shape-change color maps transforming the mean soft tissue Class I geometry into the mean Class III configuration.

- (i) For shape-change, the 5-year-old soft tissue configuration is isotropic, with evidence of anisotropy restricted to the soft subspinale, perioral, and labial regions.
- (ii) The 6-year-old group is similar to Fig. 3i. The majority of the soft tissue configuration is isotropic, with anisotropy restricted to the soft subspinale and labial regions.
- (iii) The 7-year-old group shows that the majority of the soft tissue configuration is isotropic, with anisotropic soft subspinale and labial regions.
- (iv) The 8-year-old group exhibits anisotropy in the circumoral and symphyseal regions.
- (v) The 9-year-old group displays anisotropy in the soft subspinale and labial regions similar to the 5- to 7-year-olds.
- (vi) The 10-year-old group shows the most isotropic soft tissue configuration, exhibiting anisotropy of $\approx 5\%$ to 15% , confined to the labia.
- (vii) The 11-year-old group demonstrates homogeneity in soft tissue shape-change, with anisotropy restricted to the labial and soft tissue menton regions.
- (viii) For overall shape-change, the Class III soft tissue facial nodal mesh is predominantly isotropic, except for the anisotropic circumoral and labial regions, including the soft subspinale region.



registration on any individual node, thus obviating misleading conclusions due to relative changes in position for any landmark used as a registration point.

In terms of localization, one might expect differences in regional morphology within the soft tissues of Class III individuals compared with Class I subjects. Results from the graphical analysis indicated that decreases in local size occurred predominantly in the soft subspinale region, whereas large increases in size were seen particularly in the soft mandibular mental area. These results support the view that the midface is either displaced posteriorly or is restrained from growing anteriorly relative to the mandible. The putative ontogenetic hindrance would have the effect of decreasing the anteroposterior midfacial length during morphogenesis and simultaneously leading to mandibular prognathism. In an earlier study, Singh et al.¹³ noted that the Class III skeletal midface is reduced by $\approx 10\%$ in anteroposterior dimension when analyzed using FEM. In another FEM study,¹² the Class III skeletal mandibular corpus was increased in size by $\approx 12\%$. In view of the $\approx 40\%$ soft midface reduction in size relative to the Class I sample, allied with the $\approx 70\%$ soft mandibular increase in size noted in the present study, it would appear that the soft tissues may play a more active role than supposed in the development of the imbalance between maxillary and mandibular growth characteristics of subjects with Class III malocclusion. That such findings have been reported for patients with Class III malocclusion supports the hypothesis of an altered soft tissue activity component in the etiology of Class III malocclusions. For example, Seren⁴¹ reported that hypofunction of the mentalis muscle is related to mandibular protrusion; more recently, Trotman et al.⁴² suggested that soft tissue parameters such as lip posture,

airway size, and tonsil size may be associated with differences in craniofacial morphology. Fränkel^{7,43,44} recognized the role of the soft tissue in the development of Class III malocclusion, as can be seen in the design of his appliance system. The vestibular shields and upper labial pads of the FR-III appliance function to counteract the forces of the surrounding musculature that, according to Fränkel, restrict forward maxillary skeletal development and cause a retrusion in maxillary tooth position.

It appears also that the early pattern of facial deformation is maintained in the later postnatal stages in the untreated Class III child, supporting the view that the foundations for Class III malocclusion are established in the early postnatal period.^{38,45} In the present study, however, no account was taken of sexual dimorphism, even though this feature is evident for soft tissue measurements.⁴⁶ Nevertheless, perioral soft tissues follow a pattern similar to that of the mean group,⁴⁶ and this principle was upheld in our study. In addition, in the development of malocclusions, Buschang et al.⁴⁶ considered that size differences are established before 11 years of age, and that boys with normal occlusion and untreated Class III malocclusion are comparable in growth velocity and acceleration. Indeed, in a cross-sectional study of 1376 Japanese females, Miyajima et al.²² reported that for Class III patients the underlying skeletal and dentoalveolar imbalances were reflected in the soft tissue profile. Therefore, the perioral soft tissue pattern might simply follow the skeletal morphology, regardless of other dimorphic parameters.

In the treatment of Class III malocclusions, Ngan et al.⁷, using 6 months treatment with maxillary expansion and protraction, found that forward movement of the maxilla was accompanied by 50% to 70% forward movement of the soft tissue profile. Similarly, in the mandible, down-

ward and backward movements of the soft tissues were 71% to 81% of the corresponding hard tissue movement. Those values are in agreement with the magnitude of values reported here, using a different analytical technique. Similarly, Ingervall et al.⁴⁷ reported that, on average, the labial fold and chin moved 6% more than the hard structures while the lower lip moved 12% less than the mandibular incisors in patients treated with mandibular setback for the surgical management of Class III malocclusions. Therefore, as the aim of orthodontic treatment is to correct Class III malocclusions to Class I, the soft tissue differences described for untreated Class III subjects mirror the putative changes required in the treatment of Class III patients to attain a normal lateral facial profile. Simply stated, the $\approx 40\%$ reduction in size noted at soft-subspinale localizes the region and degree of correction required for the Class III child. Nevertheless, the limitations of generic data are that they cannot be used for individual patient prediction, and the problem of individual patient treatment planning still needs to be addressed.

As well, relapse following dental arch expansion may be due to an increase in labial soft tissue pressure resulting in postoperative instability. Shellhart et al.⁴⁸ suggested, however, that labial adaptation occurs following an initial increase in pressure. This supposition is supported by our current findings, as the upper nasolabial fold appears to be associated more closely with the maxillary supra-alveolar process. Miyajima et al.²² reported that in the Japanese female the average value for the nasolabial angle remains similar across developmental stages. Indeed, the soft tissues may serve to camouflage the hard tissue morphology. These views are in accord with our present findings using a different technique; anisotropy of the labial structures was evident.

Ultimately, any morphometric technique simply provides a description that may be used to hypothesize a developmental mechanism; the decomposition of cause versus effect remains elusive. The negative allometry localized near soft subspinale may simply reflect the underlying hard tissues. Therefore, the biological mechanism that Class III malocclusions may result from either early overactive maxillary musculature or hypofunction of mandibular musculature must be tested further; it highlights the multi-faceted nature of this particular maxillomandibular disharmony. Although mathematical techniques such as faciometrics⁴⁹ and Fourier analysis may allow quantitative analysis of shape and its change⁸ in the search for a definitive parameter that can be deployed to characterize the development of Class III malocclusions, graphical color-coded displays may be of more practical use to the clinician. As well, the value of electromyographic assessment in Class III malocclusions has been shown.⁵⁰ Further work will be directed at determining the functional and physiological effects of different treatment modalities on the soft tissue profile of the Class III patient.

Acknowledgments

Supported by the Wellcome Trust, UK (GDS) and University of Hawaii Seed Money Grant 96-017 (SL).

References

- Fränkel R, Fränkel C. Orthodontics in orofacial region with help of function regulators. *Inf Orthod Kieferorthop* 1988; 20(3): 277-309.
- McNamara JA Jr, Brust EW, Riolo ML. Soft tissue evaluation of individuals with an ideal occlusion and a well-balanced face. In: McNamara JA Jr, ed. *Esthetics and the treatment of facial form*. Monograph 28, Craniofacial Growth Series. Ann Arbor: Center for Human Growth and Development, University of Michigan. 1993:115-146.
- Lowe AA, Takada K, Taylor LM. Muscle activity during function and its correlation with craniofacial morphology in a sample of subjects with Class II Division 1 malocclusions. *Am J Orthod* 1983; 84(3): 204-211.
- Bailey LJ, Collie FM, White RP. Long-term soft tissue changes after orthognathic surgery. *Int J Adult Orthod Orthognath Surg* 1996; 11(1): 7-18.
- Bardach J, Kelly KM, Salyer KE. The effects of lip repair with and without soft-tissue undermining and delayed palate repair on maxillary growth: An experimental study in beagles. *Plast Reconstr Surg* 1994; 94(2): 343-351.
- Kapucu MR, Gursu KG, Enacar A, Aras S. The effect of cleft lip repair on maxillary morphology in patients with unilateral complete cleft lip and palate. *Plast Reconstr Surg* 1996; 97(7): 1371-1375.
- Fränkel R. Maxillary retrusion in Class III and treatment with function corrector III. *Trans Eur Orthod Soc* 1970;46: 249-259.
- Frankel R. Biomechanical aspects of the form/function relationship in craniofacial morphogenesis: A clinician's approach. In: McNamara JA Jr, Ribbens KA, Howe RP, eds. *Clinical alterations of the growing face*. Monograph 14, Craniofacial Growth Series. Ann Arbor: Center for Human Growth and Development, University of Michigan, 1983.
- Ngan P, Hagg U, Yiu C, Merwin D, Wei SH. Soft tissue and dentoskeletal profile changes associated with maxillary expansion and protraction headgear treatment. *Am J Orthod Dentofac Orthop* 1996; 109(1): 38-49.
- Ferrario VF, Sforza C, Guazzi M, Montorsi F, Taroni A. Effect of growth and development on human soft tissue facial shape: Fourier analysis. *Int J Adult Orthod Orthognath Surg* 1996; 11(2): 155-163.
- Singh GD, McNamara JA Jr, Lozanoff S. Finite element analysis of the cranial base in subjects with Class III malocclusion. *Brit J Orthod* 1997; 24: 103-112.
- Singh GD, McNamara JA, Lozanoff S. Mandibular morphology in subjects with Class III malocclusions: Finite-element morphometry. *Angle Orthod* 1998;68(5):409-418.
- Singh GD, McNamara JA Jr, Lozanoff S. Finite element morphometry of the midfacial complex in subjects with Angle's Class III malocclusions. *J Craniofac Genet Dev Biol* 1997; 17(3): 112-120.
- Nanda RS, Ghosh J. Facial soft tissue harmony and growth in orthodontic treatment. *Semin Orthod* 1995; 1(2): 67-81.
- Giddon DB, Bernier DL, Evans CA, Kinchen JA. Comparison of two computer-animated imaging programs for quantifying facial profile preference. *Perceptual and Motor Skills* 1996; 82: 1251-1264.
- Giddon DB, Sconzo R, Kinchen JA, Evans CA. Quantitative comparison of computerized discrete and animated profile preferences. *Angle Orthod* 1996; 66(6): 441-448.
- Mack MR. Perspective of facial esthetics in dental treatment planning. *J Prosthet Dent* 1996; 75(2): 169-176.
- Rak D. Cephalometric analysis in cases with Class III malocclusions. *Stomatol Glas Srb* 1989; 36: 277-287.
- Blanchette ME, Nanda RS, Currier GF, Ghosh J, Nanda SK. A longitudinal cephalometric study of the soft tissue profile of short- and long-face syndromes from 7 to 17 years. *Am J Orthod Dentofac Orthop* 1996; 109(2): 116-131.
- Kess K. Age-dependent soft-tissue changes in the face. *Fortschr Kieferorthop* 1990; 51(6): 373-377. [Article in German].
- Kajikawa Y. Changes in soft tissue profile after surgical correction of skeletal Class III malocclusion. *J Oral Surg* 1979; 37(3): 167-174.
- Miyajima K, McNamara JA Jr, Sana M, Murata SK. An estimation of craniofacial growth in the untreated Class III female with anterior crossbite. *Am J Orthod Dentofac Orthop* 1997; (in press).
- Willmot DR. Soft tissue profile changes following correction of Class III malocclusions by mandibular surgery. *Br J Orthod* 1981; 8(4): 175-181.
- Schatz JP, Tsimas P. Cephalometric evaluation of surgical-orthodontic treatment of skeletal Class III malocclusion. *Int J Adult Orthod Orthognath Surg* 1995; 10: 173-180.
- Guyer EC, Ellis E, McNamara JA Jr, Behrents RG. Components of Class III malocclusion in juveniles and adolescents. *Angle Orthod* 1986; 56: 7-30.
- Gower JC. Generalized Procrustes analysis. *Psychometrika* 1975; 40: 33-51.
- Rohlf FJ, Slice D. Extensions of the Procrustes method for the optimal superimposition of landmarks. *Syst Zool* 1990; 39: 40-59.
- Singh GD, McNamara JA Jr, Lozanoff S. Morphometry of the cranial base in subjects with Class III malocclusion. *J Dent Res* 1997; 76(2): 694-703.

29. Lozanoff S, Diewert VM. A computer graphics program for measuring two- and three-dimensional form change in developing craniofacial cartilages using finite elements. *Comp Biomed Res* 1989; 22: 63-82.
30. Bookstein FL. *Morphometric tools for landmark data*. Cambridge: Cambridge University Press, 1991.
31. Lozanoff S, Diewert VM. Measuring histological form change with finite element methods. *Am J Anat* 1986; 177:187-201.
32. Burke PH, Hughes-Lawson CA. The growth and development of the soft tissues of the human face. *J Anat* 1988; 158: 115-120.
33. Schulhof RJ, Nakamura S, William WV. Prediction of abnormal growth in Class III malocclusion. *Am J Orthod* 71(4): 421-430, 1977.
34. McCance AM, Moss JP, Fright WR, Linney AD. Three dimensional analysis techniques. Part 3. Color-coded system for measurement of bone and ratio of soft tissue to bone: The analysis. *Cleft Palate-Craniofac J* 1997; 34(1): 52-57.
35. Enlow DH, Moyers RE, Hunter WS, McNamara JA Jr. A procedure for the analysis of intrinsic facial form and growth. *Am J Orthod* 1969; 56: 6-23.
36. Hashim HA, Sarhan OA. Dentoskeletal components of Class III malocclusions for children with normal and protruded mandibles. *J Clin Pediatr Dent* 1993; 18: 6-12.
37. Battagel JM. Predictors of relapse in orthodontically-treated Class III malocclusions. *Br J Orthod* 1994; 21: 1-13.
38. Tollaro I, Baccetti T, Franchi L. Class III malocclusion in the deciduous dentition: A morphological and correlation study. *Eur J Orthod* 1994; 16: 401-408.
39. Ayoub AF, Stirrups DR. The practicability of finite-element analysis for assessing changes in human craniofacial morphology from cephalographs. *Arch Oral Biol* 1993; 38: 679-683.
40. Sameshima GT, Melnick M. Finite element-based cephalometric analysis. *Angle Orthod* 1994; 64: 343-350.
41. Seren E. EMG investigation on mentalis, masseter and OOS muscles of adults with Class III malocclusion. *Turk Ortodonti Derg* 3(1): 85-93, 1990.
42. Trotman CA, McNamara JA Jr, Dibbets JM, van der Weele LT. Association of lip posture and the dimensions of the tonsils and sagittal airway with facial morphology. *Angle Orthod* 67(6): 425-432, 1997.
43. Fränkel R. *Technik und Hadhabung der Funktionsregler*. VEB Verlag, Volk, and Gesundheit, Berlin, 1976.
44. Fränkel R, Fränkel C. *Orofacial orthopedics with the function regulator*. S. Karger, Pub, Munich, 1989.
45. Tollaro I, Baccetti T, Franchi L. Craniofacial changes induced by early functional treatment of Class III malocclusion. *Am J Orthod Dentofac Orthop* 1996; 109: 310-318.
46. Buschang PH, Tanguay R, Turkewicz, Demirjian A, LaPalme L. A polynomial approach to craniofacial growth: Description and comparison of adolescent males with normal occlusion and those with untreated Class II malocclusion. *Am J Orthod Dentofac Orthop* 1986; 90(5): 437-442.
47. Ingervall B, Thuer U, Vuillemin T. Stability and effect on the soft tissue profile of mandibular setback with sagittal split osteotomy and rigid fixation. *Int J Adult Orthod Orthognath Surg* 1995; 10(1): 15-25.
48. Shellhart WC, Moawad MI, Matheny J, Paterson RL, Hicks EP. A prospective study of lip adaptation during six months of simulated mandibular dental arch expansion. *Angle Orthod* 1997; 67(1): 47-54.
49. El-Mangoury NH, Mostafa YA, Rasmy EM, Salah A. *Faciometrics: A new syntax for facial feature analysis*. *Int J Adult Orthod Orthognath Surg* 1996; 11(1): 71-82.
50. Moss JP. The problem of the Class III malocclusion. *Proc Royal Soc Med* 1976; 69(12): 913-922.