

Craniofacial Growth in Juvenile *Macaca mulatta*: A Cephalometric Study¹

JOSE C. ELGOYHEN,^{2,3} MICHAEL L. RIOLO,³ LEE W. GRABER,³
ROBERT E. MOYERS⁴ AND JAMES A. McNAMARA, JR.⁵

³ Center for Human Growth and Development, The University of Michigan, Ann Arbor, Michigan, ⁴ Center for Human Growth and Development, and School of Dentistry, The University of Michigan, Ann Arbor, Michigan and ⁵ Center for Human Growth and Development, and Department of Anatomy, The University of Michigan, Ann Arbor, Michigan

KEY WORDS Growth · *Macaca mulatta* · Monkey · Cephalometrics · Implants · Dentition · Variability.

ABSTRACT This paper describes a study of normal craniofacial growth of the juvenile rhesus monkey (*Macaca mulatta*). Serial data of 13 young monkeys of specific dental age were studied for a five month period by cephalometric radiography and the metallic implant technique. Growth patterns were described and localized growth changes quantified to determine the range of variability. Variability was found within areas of specific bones, e.g., the gonial region of the mandible, and in the relative degree of change of interbony relationships, e.g., maxillo-mandibular. There was generally less variability for most measures in this study than usually found in man.

Compensatory factors, such as the adaptability of the dentition and the selective apposition and resorption of osseous surfaces minimized the occlusion expression of this observed variation, for all animals maintained a constant Class I molar relationship during the period studied.

The rhesus monkey (*Macaca mulatta*) has been used in many experimental studies of craniofacial morphology and growth (Breitner, '40; Baume and Derichsweiler, '61; Moyers et al., '70), yet normal variability in this species has not been widely studied. There have been a number of histologic studies of craniofacial bone growth in both *Homo* (Enlow and Harris, '64; Enlow, '68) and *M. mulatta* (Turpin, '68; Duterloo and Enlow, '70) and numerous cephalometric studies in man. However, few serial cephalometric studies of the monkey have been reported (Gans and Sarnat, '51; Pihl, '59), especially studies in which metallic implants were employed. In this present report, the first in a series of papers on normal craniofacial growth in the rhesus monkey, the cephalometric implant method has been utilized in obtaining longitudinal growth data from a group of young *M. mulatta* monkeys. These metallic implants, as seen in radiographs, acted as landmarks pro-

viding a means of analyzing the relative contributions of different growth areas to the morphogenesis of individual bones. Also the relative displacement of the various bones of the craniofacial complex could be determined. The purposes of this study were to describe the normal osseous relationships of the craniofacial complex during growth and to quantify these growth changes, showing their normal variability during the age period studied.

MATERIALS AND METHODS

Thirteen male monkeys, serving as a control group for a series of studies on the role of neuromuscular function in craniofacial growth, were used in the present study. Six series of radiographs, taken monthly on each animal, were traced and analyzed. The time interval covered was analogous to 15–18 months

¹ This study was supported, in part, by United States Public Health Service grants DE-02272 and DE-43120.

² Present address: Buenos Aires, Argentina.

of human mixed dentition growth (Tanner, '55; Haigh and Scott, '65). The first radiographic series was taken when the first permanent molars of the monkey met in complete occlusion. According to available tables of tooth eruption (Hurme and Van Wagenen, '53, '61), the animals were approximately 20–29 months of age.

Tantalum implants were placed using the technique first described by Björk ('55, '63). Three implants were inserted by extraoral incision in the right side of the mandible; one in the chin and two in the lower border of the mandibular body. A fourth implant was inserted through the fibers of the masseter muscle into the lower third of the ramus. In the upper face two tantalum pins were implanted on each side of the zygomatico-maxillary su-

ture and similarly two on each side of the midpalatal suture.

Lateral, posteroanterior, and inferosuperior cephalometric views were taken under general anesthesia, utilizing two different cephalostats specifically designed for primate experimentation (Moyers et al., '70). Kodak Industrial Type M film was used to enhance visualization of detail. In order to reduce the relative magnitude of any tracing error, the lateral films (both closed and open mouth) were enlarged three times on Kodak Translite film before tracing on .003" acetate.

FINDINGS

Mandible. The superimposition of the implants in successive tracings of the mandible permitted a study of localized

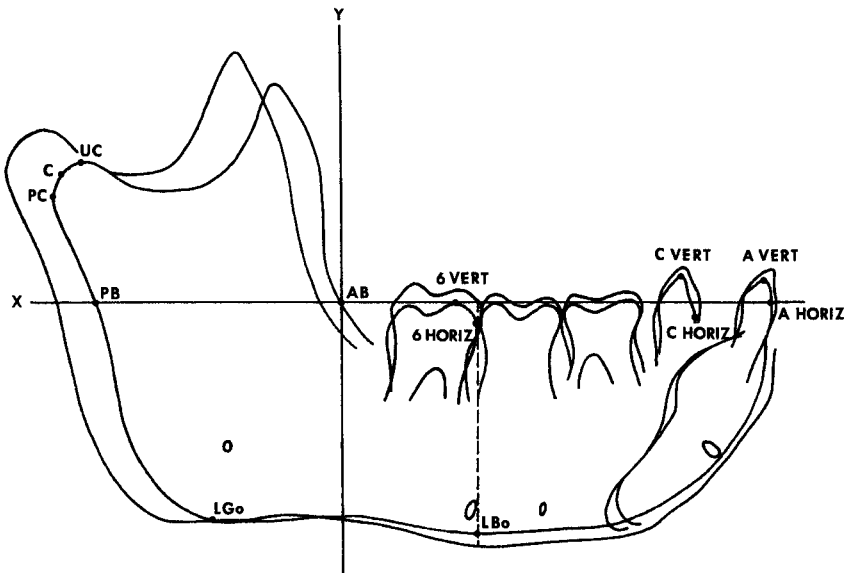


Fig. 1 A composite tracing of the mandible illustrating the changes during the five month period studied. The following points were used as a basis of measurement:

UC, Uppermost portion of the condyle outline determined by a tangent perpendicular to "Y."
 PC, Most posterior point of the condyle outline determined by the tangent perpendicular to "X."

C, Condylion, the most posterior and superior point on the condyle.

PB, Intersection of the extended occlusal plane "X" with the posterior border of the ramus.

AB, Intersection of this same line with the anterior border of the ramus.

LGo, Lowermost point on the gonial region determined by a tangent perpendicular to "Y."

LBo, Intersection of a perpendicular to the occlusal plane through the mesial contact point of the first molar and with the lower border of the mandibular body.

6 Horiz, Mesial point of the outline of the first permanent molar.

6 Vert, Most occlusal point of the mesial buccal cusp of the first permanent molar.

C Horiz, Mesial point of the outline of the deciduous cuspid.

C Vert, Most incisal point of the deciduous cuspid.

A Horiz, Anterior point of the labial surface of the deciduous central incisor.

A Vert, Incisal edge of deciduous central incisor.

growth changes. On the initial tracing of each animal a line "X" was traced along the occlusal plane intersected by a perpendicular "Y" at the junction of the anterior border of the ramus (fig. 1). Dental and skeletal changes were quantified relative to these lines in successive tracings. The growth of the mandible tended to follow an even pattern of remodeling (fig. 1). The posterior borders of the ramus and condyle showed much bony apposition, surpassing even the vertical growth of the ramus (table 1). Resorption at the anterior border of the mandible was about half the amount of the apposition on the posterior border. Thus, the ramus became wider as it was relocated posteriorly.

The contour of the chin was appositional and, as had been documented previously (Enlow, '66; Turpin, '68), the remodeling pattern of this region in *M. mulatta* was quite different from that described in man. The lingual aspect of the symphysis was also appositional in its inferior portion and the lower border of the body was decreasingly appositional posteriorly. While the entire lower border of the mandibular corpus was found to be appositional in all instances, the region of the gonial angle was variable. A constant backward relocation was observed in some cases, and in others a backward and upward relocation was noted (figs. 2A,B).

Figures 3A and B show the posteroanterior and inferosuperior superimpositions of the two animals showing the extremes in transverse growth of the condyles and coronoid processes. The constant inward and vertical relocation of these areas maintained the transverse dimensions during backward growth in accordance with the "V" principle described by Enlow ('68). The lower half of the lateral surface of the ramus was appositional while the upper half reversed to a resorptive pattern.

The development of the mandibular occlusion demonstrated little variability among the animals studied. The occlusion was characterized primarily by vertical development, especially in the more distal portions of the lower arch. Mesial migration of the buccal segments was minimal in these animals (figs. 1, 2A,B).

Maxilla. Maxillary growth measurements were derived in a manner similar

TABLE 1
Mandibular growth during five months (N = 13)

Measures (see fig. 1)	\bar{X}	S.D.	Range
	mm	mm	mm
PC	3.37	± 1.01	2.1-5.0
UC	2.97	± 0.60	1.8-4.1
C	3.98	± 0.80	3.1-5.5
PB	3.28	± 0.79	1.6-4.1
AB	-1.81	± 0.48	-1.3-2.8
LGo	0.12	± 0.62	-2.6-1.5
LBo	0.63	± 0.32	0.2-1.2
6 Horiz	0.22	± 0.31	0 -0.9
6 Vert	0.96	± 0.04	0.5-1.9
C Horiz	0.20	± 0.24	-0.5-0.5
C Vert	0.68	± 0.45	0.2-1.4
A Horiz	0.24	± 0.35	-0.3-0.7
A Vert	0.75	± 0.42	0.2-1.4

to that of the mandible. The growth pattern of the maxilla (fig. 4, table 2) included apposition on the tuberosity, the muzzle, and the floor of the orbit. Apposition in the latter region increased progressively posteroanteriorly. The increase in bone deposition occurring on the whole muzzle areas was in marked contrast to the corresponding area in man, a region not only of apposition but of resorption and vertical growth as well (Enlow and Harris, '64; Enlow, '66). Apposition of bone in the palatal region was relatively low during the period studied.

The eruption and vertical growth of the maxillary dentition contributed significantly to the vertical development of the face, and there was a noticeable forward migration of the entire maxillary dental arch, a finding to be contrasted with the rather stable mandibular arch (figs. 1, 4). The forward migration of the maxillary incisors may have been due to migration of teeth within the bone or growth at the maxillary-premaxillary suture. The rela-

TABLE 2
Maxillary growth during five months (N = 13)

Measures	\bar{X}	S.D.	Range
	mm	mm	mm
Tuberosity	1.41	± 0.65	0.47-2.07
Palate	0.43	± 0.23	0 -1.03
6 Horiz	1.05	± 0.35	0.70-1.97
6 Vert	0.74	± 0.34	0.43-1.47
C Horiz	1.06	± 0.24	0.63-1.40
C Vert	0.54	± 0.47	0 -1.51
A Horiz	1.13	± 0.35	0.80-1.77
A Vert	0.40	± 0.36	0 -1.37

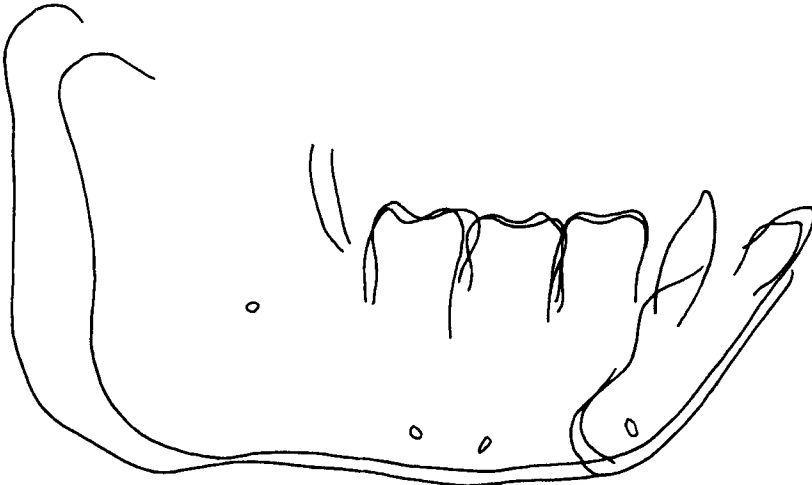

Figure 2A

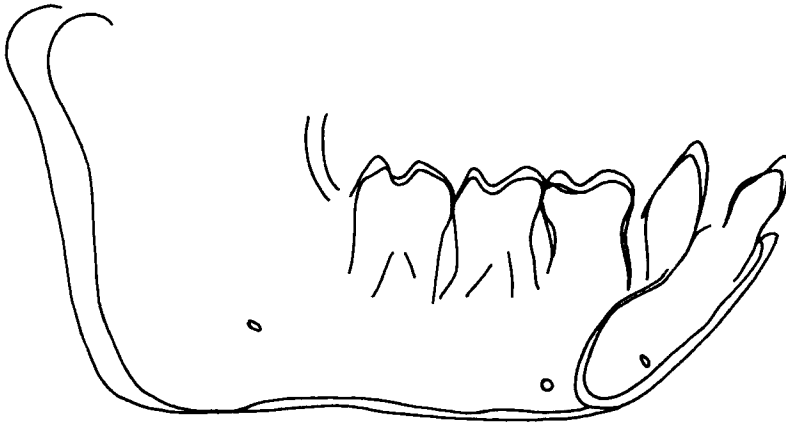


Figure 2B

Fig. 2A Mandibular tracing of animal 216 which showed the greatest tendency for closure of the gonial angle and upward condylar growth.

Fig. 2B Tracing of monkey 212 which demonstrated the greatest tendency toward an opening of the gonial angle and posterior condylar growth.

tive roles of each could not be detected from the radiographs.

Maxillo-mandibular relationships. Changes in maxillo-mandibular relationships during growth were studied by superimposing on the maxillary implants and measuring the displacement of the mandibular implants (fig. 5, table 3). During the period studied, the mandible was displaced anteriorly relative to the maxilla. There was a forward displacement of the entire mandible and rotation of the mandible during growth. This counter-clockwise rotation was more pronounced

TABLE 3

Maxillo-mandibular relations: changes in mandibular implant position during five months (N = 13)

	\bar{X}	S.D.	Range
	mm	mm	mm
Horizontal changes			
Ramus implant	1.59	± 1.09	0.3-3.5
Body implant	1.62	± 0.95	0.4-3.3
Chin implant	1.57	± 0.88	0.4-3.0
Vertical changes			
Ramus implant	1.90	± 0.81	0.4-3.2
Body implant	1.22	± 0.89	0 -2.9
Chin implant	0.99	± 0.93	-1.3-2.8

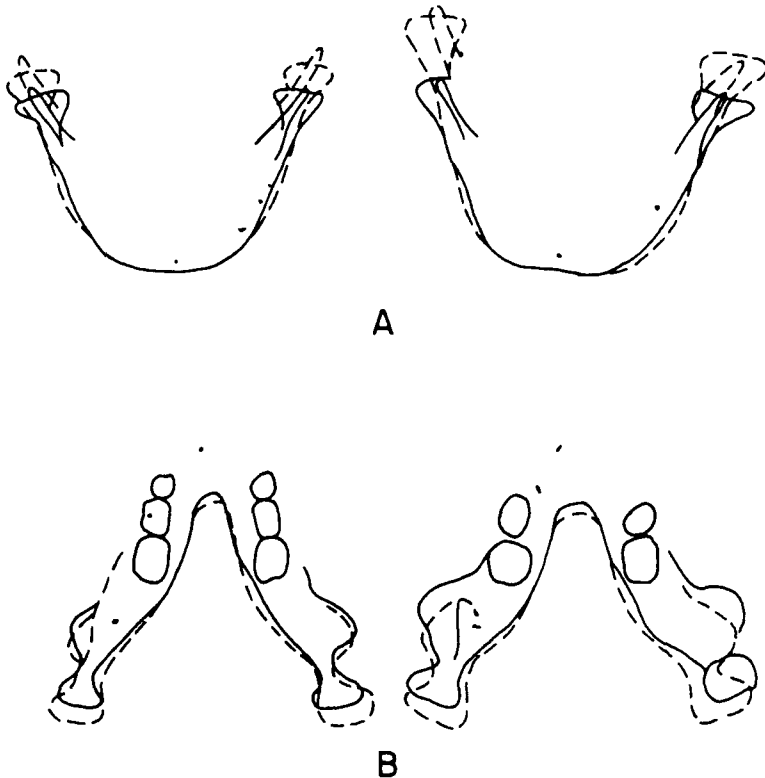


Fig. 3A Tracings from posteroanterior view of the two monkeys found to represent extremes in growth. The same upward relocation of the condyle and coronoid process was seen in each animal, but the amount of displacement was variable.

Fig. 3B Inferosuperior tracings superimposed on the implants, showing the behavior of the posteriorly growing mandibular "V." Note the apposition on the posterior contour of the symphysis and the depository nature of the internal and posterior retromolar zone.

in the region of the ramus (fig. 5). As already mentioned, the apposition on the lower border of the mandible was greater in the anterior portion than in the gonial region, which compensated for the relatively greater downward displacement of the posterior region during growth.

Superimposition on the maxillary implants also provided a means of studying the mechanisms which maintained occlusal relationships during growth. The first permanent molars in all animals erupted into a full Class I relationship without the typical transitional end-to-end occlusion found in humans during the mixed dentition period. Direct observation of 30 dry skulls of *M. mulatta* and over 100 live monkeys of all ages revealed a Class I molar relationship to be a constant finding. Thus, there was much less variability in occlusal relationships than had been

noted in human samples. No naturally occurring Class II or Class III molar relationships have yet been observed in our study, although some younger animals may exhibit a slight tendency toward a Class III molar relationship.

The relative lack of mesial migration of teeth in the mandibular buccal segments during eruption and the relatively strong mesial displacement of the maxillary dentition maintained occlusal relationships despite the non-equivalent maxillo-mandibular growth. This enables the occlusion to remain relatively constant in all animals throughout this period, despite varying amounts of mandibular and maxillary growth (fig. 6). Perhaps the steeply inclined cuspal planes found in the dentition of *M. mulatta* were a contributing factor to the observed occlusal homeostasis.

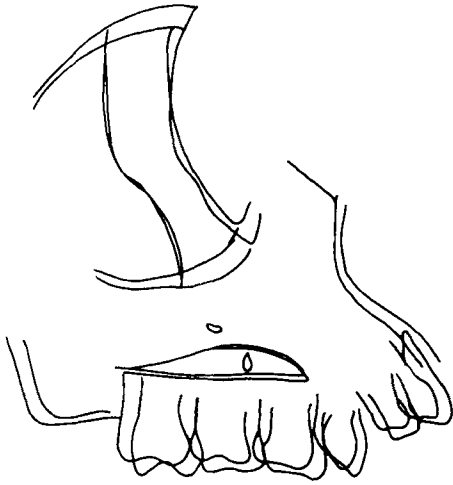


Fig. 4 Composite tracing of the maxilla superimposed on the maxillary implants showing changes within the bone. Note the mesial migration of the dental arch and the deposition of bone occurring on the muzzle, tuberosity, and on the floor of the orbit. The amount of deposition on the roof of the palate was minimal.

Cranial base superimposition. The cranial base region was used for orientation to determine the amount and direction of displacement of the maxillary and mandibular implants during the period of growth studied (table 4). Cranial base superimposition demonstrated that in the craniofacial complex of the monkey the horizontal growth component was stronger

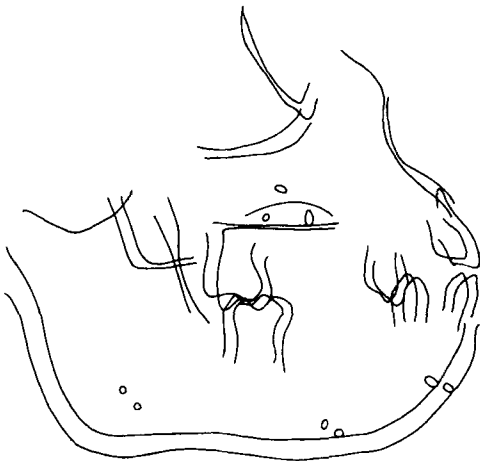


Fig. 5 Composite tracings demonstrating the average displacement of mandibular implants with the maxilla superimposed on maxillary implants.

TABLE 4

Cranial base superimposition: changes in mandibular and maxillary implant position during five months (N = 13)

	\bar{X}	S.D.	Range
	mm	mm	mm
Mandible			
Horizontal changes			
Ramus implant	2.89	± 1.30	1.1-4.3
Body implant	3.03	± 1.29	1.5-5.0
Chin implant	3.08	± 1.22	1.7-5.0
Vertical changes			
Ramus implant	3.18	± 0.85	1.9-4.8
Body implant	2.60	± 0.84	1.1-4.0
Chin implant	2.35	± 1.01	0.5-4.1
Maxilla			
Horizontal changes	1.60	± 0.63	0.9-2.9
Vertical changes	1.03	± 2.87	0 -1.6

than the vertical component. This pattern seemed to be accentuated by more anteriorly directed sutural growth, relatively less vertical occlusal development, low vertical to horizontal condylar growth ratios, and the appositional nature of the chin and the muzzle.

DISCUSSION

Björk ('60, '63) has described a tendency in man for increasing relative mandibular prognathism with age. He called attention to "compensatory factors" that tend to maintain the occlusion in humans in cases of unequal prognathic development between the maxilla and mandible. He also has demonstrated this effect in the vertical dimension and has described different patterns of rotations of the mandible and to a lesser degree of the maxilla, due to differential vertical growth. More recently, Enlow and co-workers ('69) have described areas of "equivalent" and "non-equivalent" growth of the face and have developed a concept of balanced and imbalanced compensatory growth.

From our present study it seems that such compensatory factors are also important in the normal craniofacial growth of the monkey. Many instances of variability among animals were observed in the growth of specific bones, for example, in the region of the gonial angle of the mandible (figs. 2A,B). Variability was also noted in osseous relationships during growth, for in all animals the mandible

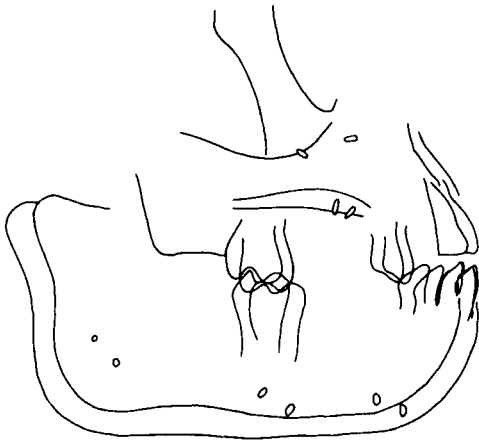


Figure 6A

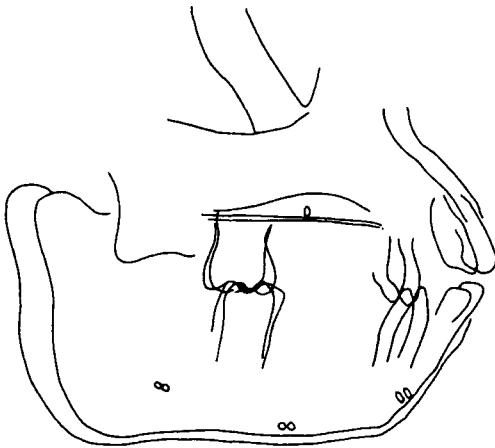


Figure 6B

Fig. 6 Tracings of two animals demonstrating variations in maxillo-mandibular relationships, as shown by the amount and direction of displacement of the mandibular implants with the tracings superimposed on maxillary implants. Note that, nevertheless, the occlusion was similar in both animals. The teeth migrated to compensate for the different prognathic development of both jaws. Note in the upper tracing (animal 221) the tendency toward increased mandibular prognathism and extreme vertical movement on the ramus implants, as opposed to the small changes in the mandibular implants in the second monkey (animal 214). It should also be noted that even in the latter animal, there was still a tendency for the mandibular implants to be displaced forward during growth relative to the maxillary implants, and that occlusal relationships were similar in both animals. The dentition appeared to compensate for the differences in mandibular-maxillary displacement.

demonstrated a rotational displacement and at the same time a greater forward displacement than the maxilla; however, the relative amount of this displacement varied from animal to animal. These changing maxillo-mandibular relationships were balanced, to varying degrees, by a higher rate of deposition on the muzzle than on the chin and by a forward migration of the upper dental arch with a rather stable anteroposterior location of the lower dental arch. The premaxillary suture has been shown to be an active growth site at this developmental stage (Moore, '49).

For the period studied, the variability in direction and amount of growth seemed to be quite low when compared to human material. Particularly, we did not detect the wide range of variability in condylar growth direction usually found in man (Björk, '63). Apposition on the palate seemed to be minimal, though displacement was consistently observed (table 4). This was in contrast to the findings of Björk ('60, '64), who has reported variability in the mechanisms of vertical palatal growth in man. However, a longer period of observations will be necessary to compare these findings more completely with human studies.

ACKNOWLEDGMENT

Editorial assistance was provided by Mrs. Ruth Bigio.

LITERATURE CITED

- Baume, L., and H. Derichsweiler 1961 Is the condylar growth center responsive to orthodontic therapy? An experimental study in *Macaca mulatta*. *Oral Surg., Oral Med., and Oral Path.*, 14: 347-362.
- Björk, A. 1955 Facial growth in man, studied with the aid of metallic implants. *Acta Odont. Scand.*, 13: 9-34.
- 1960 The relationship of the jaws to the cranium. In: *Introduction to Orthodontics*. A. Lundström, ed. McGraw-Hill Book Co., New York.
- 1963 Variations in the growth pattern of the human mandible; longitudinal radiographic study by the implant method. *J. Dent. Res.*, 42: 400-411.
- 1964 Sutural growth of the upper face studied by the implant method. *Trans. Europ. Orthod. Soc.*, 40: 49-55.
- Breitner, C. 1940 Bone changes resulting from experimental orthodontic treatment. *Amer. J. Orthodont. and Oral Surg.*, 26: 521-547.

- Duterloo, H. S., and D. H. Enlow 1970 A comparative study of cranial growth in *Homo* and *Macaca*. *Am. J. Anat.*, 127: 357-368.
- Enlow, D. H. 1966 A comparative study of facial growth in *Homo* and *Macaca*. *Am. J. Phys. Anthropol.*, 24: 293-308.
- 1968 *The Human Face*. Harper and Row, Publishers, New York.
- Enlow, D. H., and D. B. Harris 1964 A study of the postnatal growth of the human mandible. *Amer. J. Orthodont.*, 50: 25-50.
- Enlow, D. H., R. E. Moyers, W. S. Hunter and J. A. McNamara, Jr. 1969 A procedure for the analysis of intrinsic facial form and growth. *Amer. J. Orthodont.*, 56: 6-24.
- Gans, B. J., and B. G. Sarnat 1951 Sutural facial growth of the *Macaca rhesus* monkey: A gross and serial roentgenographic study by means of metallic implants. *Amer. J. Orthodont.*, 37: 827-841.
- Haigh, M. V., and A. Scott 1965 Age determination in the rhesus monkey. *Lab. Animal Care*, 15: 57-73.
- Hurme, V., and G. Van Wagenen 1953 Basic data on the emergence of deciduous teeth in the monkey (*Macaca mulatta*). *Proc. Amer. Philo. Soc.*, 97: 291-315.
- 1961 Basic data on the emergence of permanent teeth in the rhesus monkey (*Macaca mulatta*). *Proc. Amer. Philo. Soc.*, 105: 105-140.
- Moore, A. W. 1969 Head growth of the Macaque monkey as revealed by vital staining, embedding, and undecalcified sectioning. *Amer. J. Orthodont.*, 35: 654-671.
- Moyers, R. E., J. C. Elgoyhen, M. L. Riolo, J. A. McNamara, Jr. and T. Kuroda 1970 Experimental production of Class III in rhesus monkeys. *Trans. Europ. Orthod. Soc.*, 46: 1-15.
- Pihl, E. B. 1959 A serial study of the growth of various cranial and facial bones in the *Macaca* monkey. Master's thesis. University of Washington.
- Tanner, J. M. 1955 *Growth at Adolescence*. Charles C Thomas, Publishers, Springfield, Illinois.
- Turpin, D. L. 1968 Growth and remodeling of the mandible in the *Macaca mulatta* monkey. *Amer. J. Orthodont.*, 54: 251-271.