



Dr. Ellis

Components of adult Class III open-bite malocclusion

Edward Ellis III, D.D.S., M.S.,* and James A. McNamara, Jr., D.D.S., Ph.D.**

Ann Arbor, Mich.

In an effort to identify the frequency and differences in the dental and skeletal components of a large sample of adults with Class III malocclusion, with and without open bite, 176 subjects, one half of whom had an anterior open bite, were evaluated. These subjects were chosen by looking at the lateral cephalometric radiographs that were taken of 302 adults (128 men and 174 women) who exhibited at least an end-to-end Class III molar and canine relationship. The dental overbite was calculated for all subjects, and those with a negative overbite were placed in the open-bite (OB) group. Those with a positive overbite were placed in the non-open-bite (non-OB) group. The dental overbite was the only criterion used to define the open-bite and non-open-bite groups. The open-bite subjects were paired with a non-open-bite subject by sex, presence of presurgical orthodontic treatment, and anterior cranial base length. Eighty-eight subjects in each group (43 men and 45 women) were obtained. Various measures of craniofacial structure were calculated and analyzed by comparing the OB and non-OB groups with the paired t test. The areas that showed significant differences ($p < 0.05$) between the OB and non-OB groups were as follows: (1) the posterior maxilla exhibited vertical excess in the OB group; (2) the maxillary occlusal plane was less steep in the OB group; (3) the mandibular occlusal plane was more steep in the OB group; (4) the gonial angle was higher in the OB group; (5) the mandibular plane angle was higher in the OB group; (6) the mandibular ramus was positioned in a more downward and backward location in the OB group; (7) the total anterior facial height and lower facial height were increased in the OB group; (8) the vertical height of the anterior maxilla was increased in the OB group; and (9) the mandible was less protrusive in the OB group. No significant intergroup differences were noted in the cranial base, the anteroposterior position of the maxilla or the upper and lower incisors, the palatal plane, posterior facial height, mandibular ramus height, or mandibular body height. The results of this analysis indicate that the average Class III open-bite malocclusion is characterized by aberrations in both the maxilla and the mandible. Surgical therapy may, therefore, require intervention in both jaws to correct this deformity successfully.

Key words: Class III, open bite, cephalometrics, orthognathic surgery

The diagnosis and planning of treatment for patients with maxillofacial deformities can be complex and challenging. A particularly frustrating deformity is one in which an open bite is superimposed on an anteroposterior malrelationship of the teeth and jaws. The open-bite component compounds the deformity, and frequently more extensive intervention is required to ensure a satisfactory result. In the past, neither orthodontic nor surgical treatment of skeletal open-bite deformities was very successful, even when used in combination. However, the results of combined surgical and orthodontic treatment have improved consid-

erably in the past 10 years as a result of increased diagnostic capabilities, a better understanding of the interaction between the neuromuscular components of the masticatory system with the craniofacial skeleton, and the ability to tailor treatment to the individual patient.¹⁻⁷

The management of adult patients with an open-bite component to their Class III malocclusion remains a controversial issue. Anterior maxillary and mandibular surgery,^{1,2,8-13} mandibular ramus surgery,¹⁴⁻¹⁸ surgery on the mandibular body,¹⁻⁴ posterior maxillary surgery,^{8,19-22} total maxillary surgery,²³⁻²⁵ and various combinations of these are used in the treatment of skeletal open bite. In general, a basic therapeutic principle which should be kept in mind when treating patients with maxillofacial deformities is that one should correct rather than camouflage the existing deformity (that is, the aberrant structures). Since a proper diagnosis is paramount to the implementation of successful

This research was supported in part by United States Public Health Service Grant DE-03610.

*Assistant Professor, Department of Oral and Maxillofacial Surgery, Co-Director, Dentofacial Program, and Research Investigator, Center for Human Growth and Development, The University of Michigan.

**Professor of Orthodontics, Professor of Anatomy and Cell Biology, and Research Scientist, Center for Human Growth and Development, The University of Michigan.

treatment, it is essential that the aberrations that exist within a given population of patients who exhibit maxillofacial deformities be identified.

There are several studies that compare components of a Class III malocclusion with those of Class I normal samples.²⁶⁻³³ Similarly, several studies have compared open-bite subjects with normal samples.^{7,34-39} This allows identification of the aberrant components of the craniofacial complex so that correction can be accomplished at the site of the aberration if technically feasible. There is available, however, very little information which identifies the differences in the dental and skeletal components of patients with Class III open-bite malocclusion versus those with Class III non-open-bite malocclusion. When a vertical aberration compounds an anteroposterior malrelationship, as in the present Class III open-bite sample, orthodontic or surgical correction must address both problems.

REVIEW OF THE LITERATURE

Although patients with skeletal open-bite deformities exhibit a spectrum of skeletal, dental, neuromuscular, and esthetic abnormalities, this review will cover only those cephalometric analyses that deal with skeletal and dental components of the open-bite deformity. Since very little literature is available concerning the Class III open-bite malocclusion, and since skeletal open bite may exist with any form of anteroposterior malocclusion, the vertical relationships will be most thoroughly examined.

Cranial relationships

Most analyses comparing control samples to subjects with skeletal open bite exhibit no significant difference in the anterior cranial base as measured from sella to nasion,^{7,35,37} in the cranial base angle (N-S-Ba),^{7,34} or in the angle between the Frankfort horizontal plane and the S-N plane.^{7,34} However, Subtelny and Sakuda³⁵ did find that the distance between sella and nasion was less in their open-bite sample, indicating a shortened posterior cranial base. These findings seem to indicate that the cranial base is not greatly affected in skeletal open-bite cases.

Cranio-maxillary relationships

Sassouni and Nanda³⁴ and Hahoum³⁶ found that the angle between the sella-nasion plane and the palatal plane was significantly less in their open-bite samples, indicating that in skeletal open-bite cases the anterior nasal spine is located more superiorly, that the posterior nasal spine is located more inferiorly, or that there is a combination of the two. Conversely, Subtelny and Sakuda,³⁵ Enunlu,³⁸ Frost and co-workers,⁷ and Lowe³⁹ found no significant difference in this angle, which in-

dicates that the open-bite deformity arises inferior to the palatal plane. Similarly, Subtelny and Sakuda³⁵ and Frost and co-workers⁷ found no significant difference in the angle between the palatal plane and the Frankfort plane in their open-bite and normal samples. Thus, the relationship between the palatal plane and the anterior cranial base in open-bite patients versus non-open-bite patients is unclear.

Cranio-occlusal relationships

Many investigators have found a statistically significant increase in the angle between the sella-nasion plane and the occlusal plane.^{7,34,35,38-40} Other investigators^{37,38} have constructed two occlusal planes (mandibular and maxillary) in the belief that using one occlusal plane drawn midway between the incisors to the mesial cusps of the first molar teeth is inadequate when analyzing cases of skeletal open-bite malocclusion. Their studies showed no significant difference in the maxillary occlusal plane angle; however, the mandibular occlusal plane angle was significantly greater in all open-bite cases than in controls. This finding suggests that the open-bite deformity arises below the maxillary dentition.

Cranio-mandibular relationships

A strong point of agreement among the many investigators who have studied skeletal open bite is that the mandibular plane angle is consistently larger in the skeletal open-bite patients than in controls.^{7,34-39,41-47} Is this increase in mandibular plane angle an expression of a backward rotation of the mandible or of a different shape of the mandible? Richardson⁴⁸ found an increased S-Art-Go angle in his open-bite sample, indicating that the larger mandibular plane angle was due to a downward and backward position of the mandibular ramus. Sassouni and Nanda³⁴ found that the mandibular condyle was located in a superior position, thereby indirectly decreasing effective ramus height and thus producing a larger mandibular plane angle. These findings suggest that the high mandibular plane angle consistently found in open-bite patients is due to an effectively shorter mandibular ramus and an opening rotation of the mandibular ramus.

Mandibular morphology

The gonial angle in skeletal open-bite cases is significantly larger than that in controls,^{34,35,37,38,48} and this variation in mandibular morphology might be one reason for the associated large mandibular plane angles in these patients. There is general agreement that the posterior facial height of patients with an open bite is shorter than that of normal patients.^{7,34,35,37,38} Even with a normal gonial angle, a shortened ascending

ramus would tend to produce a larger mandibular plane angle. Thus, there are three factors that are additive in the production of the high mandibular plane angle in an open-bite population: an increased gonial angle, a downward and backward position of the mandibular ramus, and a shortened posterior facial height.

Another factor that could contribute to an open bite is overeruption of the mandibular molar teeth, which could cause an opening rotation of the mandible. However, Subtelny and Sakuda³⁵ noted no significant difference between open-bite and control samples, and Sassouni and Nanda³⁴ and Nahoum and co-workers³⁷ noted a decrease in the distance between the mandibular molars and the mandibular plane.

Maxillary morphology

Although traditional orthodontic treatment has been directed at extrusion of the incisor teeth, many investigations have proved the inappropriateness of this mode of therapy. Nahoum and co-workers³⁷ found that the maxillary dentoalveolus was not underdeveloped in their open-bite population, and Sassouni and Nanda³⁴ and Subtelny and Sakuda³⁵ found that it may even be overdeveloped. These findings do not incriminate undereruption of the anterior teeth as a cause of the open-bite deformity.

An increase in maxillary posterior dentoalveolar height is another commonly cited factor in open-bite cases.^{7,34,35,43,45} However, Nahoum and co-workers³⁷ did not find any significant difference in posterior maxillary dentoalveolar height between their open-bite and normal samples. Therefore, no consensus exists as to the relationship of posterior dentoalveolar hyperplasia to open bite.

Vertical relationships

One of the most distinguishing features of the skeletal open-bite population is that the total anterior facial height is greater than that in a normal population.^{7,34,35,41,48-52} Most studies show that this increase occurs primarily in the lower anterior facial height or in the area below the anterior nasal spine^{7,34,36,37,41,42,44,47,48,53} rather than in the upper anterior facial height, which remains normal^{34,35,41} or is shorter in open-bite patients.^{36,38,39} This indicates that most of the deformity occurs below the level of the palate. The posterior facial height, the distance between sella and gonion, is usually shorter in open-bite patients than in normal subjects.^{7,34,35,37,38,45}

Summary

The review of the literature on open-bite deformity reveals contradictory descriptions as to the nature of the skeletal and dental aberrations present in this popula-

tion of patients. The cranial base, maxilla, mandible, and dentoalveolar region have all been cited as differing from populations of patients with normal dentofacial characteristics. The purpose of this article is threefold: (1) to present results of a cephalometric investigation into the frequency of an open-bite component in a large sample of adults with Class III malocclusion, (2) to present the differences in the dental and skeletal components of a large sample of adults with Class III malocclusion with and without open bite, and (3) to discuss the clinical implications of the results of the cephalometric study. Our analysis of the anteroposterior components of this sample of adult Class III patients has been published previously³³ and will not be extensively dealt with here.

MATERIALS AND METHODS

One hundred seventy-six patients with Class III malocclusion, 88 with and 88 without open bite, were evaluated in this study to determine the differences in the skeletal and dental components of their malocclusion. They were selected from a larger sample of Class III adult patients as described below.

Lateral cephalometric radiographs of 302 adults (128 males and 174 females) aged 17 years or older were evaluated. Cephalograms of Class III persons were excluded from the study only if the quality of the radiographs precluded identification of the necessary landmarks. All films were taken with teeth together in centric occlusion and not centric relation unless coincidental.

Ninety-four patients had already undergone pre-surgical orthodontic treatment; the remaining 208 had not. The cephalograms were obtained from two private orthodontic offices, a private oral and maxillofacial surgery office, and the University of Michigan Department of Oral and Maxillofacial Surgery. The selection of the radiographs was made by obtaining *all* those lateral cephalometric radiographs available at four practices.

The criterion for inclusion of a subject was the presence of at least an end-to-end Class III molar and canine relationship as determined from the lateral cephalogram. No skeletal criteria were used. No cases of cleft palate or craniofacial syndromes were included in this study.

Each film was traced by one investigator and checked by a second investigator to verify the accuracy of the tracing. The tracings were then digitized at the Center for Human Growth and Development, where the landmark points were translated into an X-Y coordinate system. The enlargement factor of the tracing of each head film was corrected by computer to 8%.

The dental overbite was calculated for each lateral

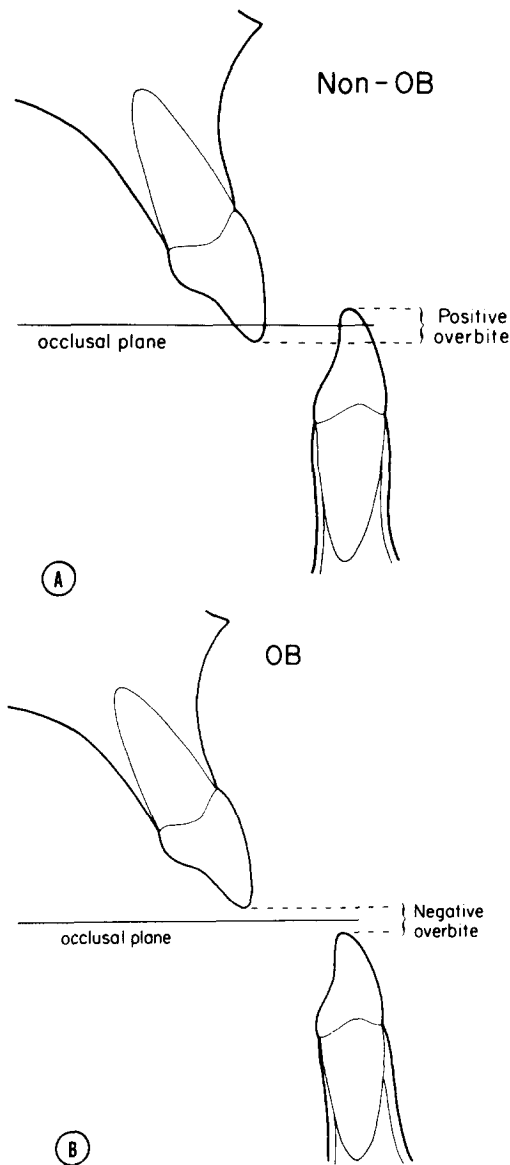


Fig. 1. The method used for calculation of the dental overbite for the non-OB, (A) and OB (B) groups. All measures were made by the computer, with the bisected occlusal plane for orientation. A negative incisal overbite was defined as an open bite.

cephalogram by measuring the vertical distance between the incisal edges of the maxillary and mandibular incisors parallel to the bisected occlusal plane (Fig. 1). Any case that demonstrated a negative overbite was placed into the open-bite (OB) group. Those with a positive overbite were placed into the non-open-bite (non-OB) group. There were 81 men and 129 women (total, 210) in the non-OB group and 47 men and 45 women (total, 92) in the OB group. Dental overbite was the only criterion used to define the open-bite and

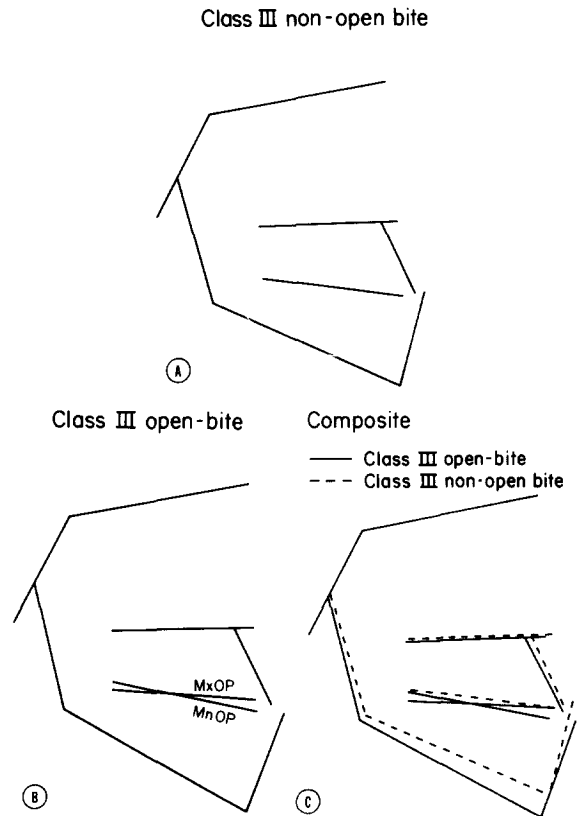


Fig. 2. Mean facial polygons for the non-OB (A) and OB (B) groups. The composite polygons (C) demonstrate the major skeletal and occlusal differences in these groups. Note: A maxillary and a mandibular occlusal plane are drawn for the OB group.

non-open-bite groups. No skeletal criteria were used. We then analyzed the *other* skeletal and dental factors to determine how they differed in the patients with and without an open bite.

The anterior cranial base (S-N) lengths for males and females were determined for the entire sample. One standard deviation above and below the mean was used to define a neutral range for anterior cranial base length. Any case whose S-N distance was below this neutral range was considered low, and any case whose S-N distance was above it, was considered high. Each OB case was randomly paired with a non-OB case by sex, orthodontic treatment, and anterior cranial base length (low, neutral, high). With the use of these criteria, 88 of the 92 OB cases were paired with a non-OB case. There were 43 men and 45 women in each group. Forty subjects had undergone orthodontic treatment and 48 had not. The mean overbite was 1.51 mm in the non-OB group (range, 0.08 to 6.73 mm). The mean overbite was -3.20 mm in the OB group (range, -9.98 to -0.15 mm).

Table I. Cranial base relationships

Craniofacial variable	Non-OB (n = 88)		OB (n = 88)		Significance
	\bar{x}	SD	\bar{x}	SD	
S-N (mm)	75.71	4.63	75.56	4.98	NS
S-Ba (mm)	49.05	3.89	49.08	3.97	NS
N-S-Ba (°)	127.07	5.02	128.34	5.91	NS
SN-FH (°)	9.19	2.58	9.35	3.23	NS

NS = Not significant.

Table II. Maxillary skeletal relationships

Craniofacial variable	Non-OB (n = 88)		OB (n = 88)		Significance
	\bar{x}	SD	\bar{x}	SD	
<i>Anteroposterior maxillary skeletal position</i>					
S-N-A (°)	79.88	3.23	80.15	4.37	NS
A pt. to Na ⊥ (mm)	-1.07	3.47	-0.69	4.41	NS
<i>Vertical maxillary skeletal relationships</i>					
SN-PP (°)	9.13	3.52	9.00	3.93	NS
FH-PP (°)	-0.06	3.49	-0.35	3.79	NS
S-PNS (mm)	51.41	3.73	51.73	4.49	NS
ERP-PNS (mm)	51.99	4.19	52.46	4.44	NS
Ptm-PNS (mm)	30.63	2.96	31.53	3.16	NS
PNS-SN ⊥ (mm)	48.94	3.54	49.38	4.10	NS
PNS-FH ⊥ (mm)	26.46	2.95	26.87	2.73	NS

NS = Not significant.

Several measures of anteroposterior and vertical relationships were analyzed for the two groups. These are found in Tables I to VI and are common measures adopted from the analyses of Downs,⁵⁴ Riedel,⁵⁵ Steiner,⁵⁶ Jacobson,⁵⁷ and McNamara.⁵⁸ For definitions of these measures, the reader is referred to those articles. The cephalometric measurements were subjected to the paired t test to determine differences between the OB and non-OB groups. In addition, the effects of presurgical orthodontic treatment in both the open-bite and non-open-bite groups were analyzed by the one-way analysis of variance between those patients who had and those who had not undergone orthodontic treatment.

RESULTS

The results of the cephalometric analyses will be presented in the following categories: cranial base, maxillary skeletal relationships, mandibular skeletal relationships, dentoalveolar relationships, intermaxillary relationships, and vertical facial relationships. Inasmuch as only four of those measures were found in which presurgical orthodontic treatment caused significant differences ($p < 0.05$) from those without orthodontic treatment in either the open-bite or the

non-open-bite group, the means for all those patients in the open-bite and non-open-bite groups (both orthodontic and nonorthodontic) are reported. The four measures that were affected by orthodontic treatment were all dentoalveolar measures and are presented in our discussion of the results.

Mean facial polygons, which were constructed for each group, provide patterns that can be readily compared visually to illustrate the relative differences (Fig. 2). When the cranial bases, which will be shown not to be significantly different, are superimposed with registration at sella, the major differences become obvious.

Cranial base (Table I)

There were no significant differences between the two groups in any of the cranial base variables. The posterior cranial base (S-Ba) was similar in dimension, as was the cranial base angle (N-S-Ba). Nor was there any significant difference in the angle between the sella-nasion plane (S-N) and the Frankfort horizontal plane (FH) in the two groups. The anterior cranial base (S-N) was also similar in dimension. The latter, of course, is expected since the groups were paired on this dimension.

Table III. Mandibular skeletal relationships

Craniofacial variable	Non-OB (n = 88)		OB (n = 88)		Significance
	\bar{x}	SD	\bar{x}	SD	
<i>Anteroposterior mandibular skeletal relationships</i>					
Facial angle (°)	93.91	3.64	92.38	4.36	**
Pog to Na \perp (mm)	8.23	7.80	5.19	9.80	*
S-N-B (°)	83.48	4.00	82.15	5.05	*
<i>Vertical mandibular skeletal relationships</i>					
SN-MP (°)	34.50	6.84	39.38	6.89	***
FH-MP (°)	25.31	6.35	30.03	6.40	***
N-Art (mm)	98.64	6.10	98.01	6.70	NS
N-S-Art (°)	121.86	5.15	122.37	6.45	NS
S-Art (mm)	34.91	3.30	34.13	3.80	NS
Growth Axis (°)	1.82	5.04	-0.82	6.06	***
PBR-SN (°)	83.72	5.48	85.89	5.89	**
PBR-FH (°)	74.52	4.90	76.54	5.14	**
<i>Mandibular skeletal morphology</i>					
Mandibular length (mm)	136.82	9.00	139.03	9.74	*
Gonial angle (°)	130.78	6.62	133.49	6.60	**
Go-Pog (mm)	85.11	5.79	86.34	6.49	NS
Go-Gn (mm)	85.51	5.85	87.02	6.41	NS
Co-Go (mm)	65.14	6.51	64.44	6.30	NS
Art-Go (mm)	53.77	6.41	53.70	6.49	NS

NS = Not significant.

*Significant at the 5% level of confidence.

**Significant at the 1% level of confidence.

***Significant at the 0.1% level of confidence.

Maxillary skeletal relationships (Table II)

The position of the maxilla was evaluated as it relates to the cranium. The variables used to measure the anteroposterior position of the maxilla were not significantly different in the two groups. The mean S-N-A value was 79.8° for the non-OB group and 80.1° for the OB group. The point A-Na \perp measurement was -1.1 mm for the non-OB group and -0.7 mm for the OB group.

There was no significant difference in the palatal plane angles (SN-PP, FH-PP) in the non-OB and OB groups. The values for the linear distances sella to posterior nasal spine (S-PNS), ethmoid registration point to PNS (ERP-PNS), and pterygomaxillary fissure to PNS (Ptm-PNS) and the perpendicular distances between PNS and the S-N and FH planes (PNS-SN, PNS-FH) were not significantly different between the groups, indicating that the posterior nasal spine is in a similar vertical location in both groups. The measures between the cranial base and anterior nasal spine are presented under vertical facial relationships.

Mandibular skeletal relationships (Table III)

The position of the mandible as it relates to the cranial base and the size and shape of the mandible were evaluated.

All of the variables used to evaluate the anteroposterior position of the mandible relative to the cranium, the facial angle, pogonion to the nasion perpendicular, and the S-N-B angle had significantly higher values in the non-OB group. This indicates that the mandible was more protrusive in the non-OB group than in the OB group.

The mandibular plane (MP) angle values were significantly larger in the OB group for both SN-MP and FH-MP angles. For instance, the SN-MP angle averaged 34.5° for the non-OB group and 39.4° for the OB group, almost 5° larger in the OB group. The angles between the posterior border of the mandibular ramus (PBR) and the cranial base (PBR-SN, PBR-FH) were significantly greater in the OB group, indicating a backward- and downward-opening position of the mandibular ramus in this group. There was also a significant difference in the values for the growth axis angle, the OB group being -0.8° versus 1.8° in the non-OB group. This indicates that gnathion is in a more inferior and backward position in the OB group.

There was no significant difference in the relative position of articulare (S-Art and N-Art) or in the saddle angle (N-S-Art), indicating that the temporomandibular joint is similarly located in the two groups.

The gonial angle in the OB group was significantly

Table IV. Dentoalveolar relationships

Craniofacial variable	Non-OB (n = 88)		OB (n = 88)		Significance
	\bar{x}	SD	\bar{x}	SD	
<i>Anteroposterior relationships</i>					
U1-Pt A Vert (mm)	6.50	2.31	6.57	2.86	NS
U1-NA (°)	27.06	7.51	27.20	7.89	NS
U1-NA (mm)	6.84	2.40	6.76	2.69	NS
IMPA (°)	81.31	8.11	80.96	8.23	NS
L1-NB (°)	19.30	7.35	22.49	7.71	**
L1-NB (mm)	4.96	2.48	6.20	2.36	***
<i>Vertical relationships</i>					
SN-OP (°)	15.57	4.58	17.94	4.85	***
SN-MxOP (°)	—	—	14.24	4.88	—
SN-MnOP (°)	—	—	21.52	5.35	—
FH-OP (°)	6.38	4.20	8.59	4.25	***
FH-MxOP (°)	—	—	4.84	4.25	—
FH-MnOP (°)	—	—	12.12	4.68	—
U6-SN ⊥ (mm)	78.11	5.43	79.67	5.94	*
U6-FH ⊥ (mm)	52.13	4.85	53.66	4.71	*
U6-ERP (mm)	80.31	6.22	81.79	6.30	*
UIE-ANS (mm)	29.83	3.45	30.88	3.96	*
U6-PP ⊥ (mm)	25.67	3.07	26.92	2.91	**
OP-PP (°)	6.44	3.87	8.94	4.07	***
MxOP-PP (°)	—	—	5.46	4.18	—
L1-Mc (mm)	46.13	4.31	46.69	4.00	NS
L6-MP ⊥ (mm)	34.23	3.73	35.64	3.57	**
OP-MP (°)	18.92	4.54	21.44	4.17	***
MnOP-MP (°)	—	—	18.18	4.18	—

NS = Not significant.

*Significant at the 5% level of confidence.

**Significant at the 1% level of confidence.

***Significant at the 0.1% level of confidence.

greater than in the non-OB group. The mean gonial angle for the OB group was 133.5° versus 130.8° for the non-OB group.

The mandibular body length (Go-Gn and Go-Pog) and the mandibular ramus length (Co-Go and Art-Go) were not significantly different between the two groups. Mandibular length (Co-Pog), however, was significantly longer in the OB group than in the non-OB group. This apparent conflict in measurements will be discussed later.

Dentoalveolar relationships (Table IV)

There was no significant difference in anteroposterior position of the maxillary incisor in the two groups, either in angulation or in relation to the maxilla and cranium (U1-NA°, U1-NA mm, U1 to point A vertical).

There was no significant difference in the angle between the lower incisor and the mandibular plane (IMPA). However, the values for L1-NB (in degrees) and L1-NB (in millimeters) were significantly greater in the OB group than in the non-OB group. This appar-

ent conflict is due to the change in the angulation of the two lines (L1-NB) when the mandible is positioned downward and backward and is not due to differences in the angulation between the incisor and the mandible (IMPA). Thus, the relationship of the lower incisor to the mandible is not different between the OB and non-OB populations.

The patients in both the OB and non-OB groups who had undergone presurgical orthodontic treatment had significantly increased values for the L1-NB angular and linear measures ($p < 0.01$). Similarly, the OB group showed IMPA values that were significantly increased in those patients who had undergone presurgical orthodontic treatment.

The occlusal plane angle (SN-OP) was significantly greater in the OB group (17.9° versus 15.6° in the non-OB group). The maxillary occlusal plane angle (SN-MxOP) in the OB group was only 14.2°, which was less than the SN-OP values of either group. The mandibular occlusal plane angle (SN-MnOP) was 21.5°, which was much greater than the SN-OP value of either group. Similar results occurred when the

Table V. Intermaxillary relationships

Craniofacial variable	Non-OB (n = 88)		OB (n = 88)		Significance
	\bar{x}	SD	\bar{x}	SD	
A-N-B (°)	-3.60	2.87	-2.00	2.55	***
WITS (mm)	-10.85	4.25	-10.77	4.41	NS
Overjet (mm)	3.60	2.84	3.80	2.60	NS
U1-L1 (°)	137.24	10.33	132.30	11.30	**

NS = Not significant.

**Significant at the 1% level of confidence.

***Significant at the 0.1% level of confidence.

Table VI. Vertical facial components

Craniofacial variable	Non-OB (n = 88)		OB (n = 88)		Significance
	\bar{x}	SD	\bar{x}	SD	
AFH (mm)	131.77	9.67	137.89	10.27	***
UFH (mm)	58.17	4.19	58.60	4.25	NS
LFH (mm)	74.11	7.11	80.17	7.51	***
UFH/LFH	0.79	0.07	0.73	0.06	***
UFH/AFH	0.44	0.02	0.42	0.02	***
LFH/AFH	0.56	0.02	0.58	0.02	***
N-A (mm)	64.63	5.06	65.88	5.10	*
A-Gn (mm)	66.87	5.97	71.70	6.37	***
NA/AGn	0.97	0.08	0.92	0.07	***
PFH (mm)	83.28	7.29	82.99	8.08	NS
PFH/AFH	0.63	0.05	0.60	0.40	***

NS = Not significant.

*Significant at the 5% level of confidence.

***Significant at the 0.1% level of confidence.

Frankfort plane was used to determine the occlusal plane angles (FH-OP, FH-MxOP, and FH-MnOP).

The distance from the incisal edge of the upper incisor to the anterior nasal spine (UIE-ANS) was significantly greater in the OB group. The OB group demonstrated more than a 1 mm larger value in this distance than did the non-OB group. This was also true of the values for the perpendicular distance between the mesial cusp tip of the maxillary first molar and the palatal plane, the sella-nasion plane, the Frankfort horizontal plane (U6-PP, U6-SN, U6-FH) and the linear distance between the maxillary first molar cusp tip and the ethmoid registration point (U6-ERP), indicating a greater posterior alveolar hyperplasia of the maxilla in the OB group. The occlusal plane to palatal plane angle (OP-PP) also was significantly greater in the OB group, being almost 2° greater than in the non-OB group. When the MxOP-PP was evaluated, it was found to be less than the values for the OP-PP angles of the non-OB cases.

Anterior mandibular dentoalveolar height (L1-Me) was similar in both groups. However, posterior mandibular dentoalveolar height (L6-MP) was significantly greater in the OB group, as was the angle between the occlusal plane and the mandibular plane (OP-MP). However, when the mandibular occlusal plane was used (MnOP-MP), there was little difference in the OP-MP values between the OB and non-OB groups.

Intermaxillary relationships (Table V)

There was a significantly greater discrepancy in the relative anteroposterior relationship of the maxilla and the mandible in the non-OB group than in the OB group based on the analysis of the A-N-B angle. However, the Wits analysis demonstrated no significant difference between the groups.

The relative anteroposterior position of the maxillary and mandibular incisors, based on the analysis of the incisor overjet, was not significantly different in the two groups. The 40 patients who underwent presurgical

orthodontic treatment in the non-OB group showed significantly higher incisor overjet measures than the 48 without orthodontics (4.4 versus 2.9 mm, $p < 0.01$). The OB group showed no such variation. The interincisal angle (U1-L1) was significantly greater in the non-OB group, averaging 137.2° versus 132.3° in the OB group.

Vertical facial relationships (Table VI)

The values for AFH, LFH, N-A, and AGn were all significantly greater in the OB group. The values for AFH, LFH, and AGn were all significantly higher at the 0.1% level of confidence and the NA values at the 1.0% level of confidence. The ratios of the various vertical measures were also significant. Posterior facial height and upper facial height were the only vertical measures that showed no significant difference between the two groups.

Summary of results

These results indicate that the OB group, as opposed to the non-OB group, has a larger gonial angle, a downward and backward positioning of the mandible, a larger mandibular plane angle, a longer lower facial height, vertical maxillary excess, and a divergent occlusal plane angle.

DISCUSSION

Although the incidence of open bite in the general population is not known, the results of this study clearly indicate that it is not a rare phenomenon in the adult Class III population. Approximately one third of the patients in the overall sample of 302 cases had an open-bite component to their Class III malocclusion. The incidence of open bite found in this sample of *adult* Class III patients may be higher than the incidence of open bite in *children* with a Class III malocclusion. This may be due to the nature of the sample used in this study. There is general agreement that the Class III open-bite malocclusion is difficult to correct orthodontically. In fact, Sassouni and Nanda³⁴ believe that this population of patients should not undergo attempts at orthodontic treatment. However, orthodontic correction of Class III deep-bite malocclusion is normally manageable if treatment is instituted at an early age. The present sample demonstrated few deep-bite cases, and this may reflect a bias in our sample.³³ All of the cases in the present sample were surgical cases and, therefore, deemed not correctable with orthodontic treatment alone. We hypothesize that fewer adults with Class III deep-bite malocclusion find their way to the surgeon, since orthodontic correction of this deformity

may produce satisfactory results if treated early. Conversely, more cases of adults with Class III open-bite malocclusion are seen by the surgeon, since orthodontic treatment may have been considered impossible and/or deferred when the patient was young or may have been undertaken unsuccessfully.

The data from the present study indicate that the open-bite component of the Class III open-bite malocclusion arises below the cranial base. All measures of cranial base dimension in the OB group are similar to those in the non-OB group. These findings are in contrast to those by Subtelny and Sakuda,³⁵ who noted a shortened posterior cranial base dimension in their open-bite sample.

The major areas of difference between the OB and non-OB groups are found in the posterior maxillary and mandibular dentoalveolar regions and in the mandible.

Dentoalveolar regions

Posterior maxillary dentoalveolar hyperplasia with overeruption of the maxillary molars occurred in the OB group. This is indicated by various measures. The angle between the occlusal plane and the sella-nasion plane (SN-OP, Table II) is significantly greater in the OB group, which indicates that the occlusal plane in the OB group is much steeper than in the non-OB group. However, an examination of the maxillary occlusal plane angle in the OB group (MxOP-SN, Table II) shows that it is much smaller than the occlusal plane angle of the non-OB group (14.2° versus 15.6°), which indicates that the maxillary occlusal plane angle in the OB group is less steep than the non-OB occlusal plane angle. The decreased maxillary occlusal plane in the OB group is the result of inferiorly positioned maxillary molars as verified by the significantly greater values for U6-SN, U6-FH, and U6-ERP.

The fact that the distance between the mandibular first molar cusp tip and the mandibular plane is greater in the OB group indicates the presence of posterior mandibular dentoalveolar hyperplasia, which could greatly contribute to the open-bite deformity. This would be especially detrimental when taken in concert with posterior maxillary dentoalveolar hyperplasia.

One possible cause for an open-bite deformity is less eruption of the anterior teeth. In this study, however, the anterior maxilla did not demonstrate an inadequate vertical dimension or undereruption of the maxillary incisors. In fact, the OB group had a significantly greater amount of anterior maxillary dentoalveolar height. This finding suggests that, in the OB group, the malocclusion is not due to an underdevelopment of the dentoalveolus in this area but that, instead, adaptations

have occurred to perhaps try to overcome the open-bite condition by overeruption of the maxillary incisors.

Mandible

The mandible seems to be the other major site of aberration in the open-bite deformity. The actual mandibular dimensions in the two groups are of interest. Although the height of the mandibular ramus and the length of the mandibular body are not significantly different in the two groups (Table III), the effective mandibular length is significantly longer in the OB group (mandibular length, Table III). The increase in the overall length of the mandible is caused by an increase in the gonial angle. The gonial angle is markedly increased in the OB group, indicating that there is a gross difference in mandibular morphology between the OB and non-OB groups. This is a remarkable finding since studies have shown that the Class III population in general has significantly greater gonial angles than normal samples. The oblique gonial angle, considered by itself, can theoretically contribute to both a Class III malocclusion and an open-bite deformity. However, the oblique gonial angle is only one aspect of the difference in the morphology of the mandibles within the OB group. Another is the downward- and backward-opening positioning of the mandibular ramus in the OB group. Taken together, the oblique gonial angles and the downward and backward positioning of the mandible contribute significantly to the open-bite deformity and give rise to the marked increase in mandibular plane angle found in the OB group.

The consequence of the downward and backward positioning of the mandibular ramus in the OB group is to make the anteroposterior discrepancy of the Class III component of the malocclusion less obvious. This is exemplified by the less negative A-N-B values found in the OB group. It also accounts for the less protrusive position of the mandible and the smaller growth axis variable in the OB group.

Vertical facial relationships

Analysis of the vertical facial proportions demonstrates significant increases in all linear measurements except upper facial height and posterior facial height. The total anterior facial height was markedly greater, averaging 6 mm more in the OB group. This agrees with the results of several other studies.^{7,34,35,41,48-52} Most investigators attribute the majority of this increase to the increase in lower anterior facial height.^{7,34,36,37,41,42,44,47,48,53} The present study confirms this, as lower anterior facial height is 6 mm greater on the average in the OB group.

There is no significant difference in posterior facial height in the two groups in this study. However, sev-

eral other studies show a decrease in posterior facial height in their open-bite samples.^{7,34,35,37,38,45} The reason for this discrepancy may be related to the nature of our sample. While most investigators agree that posterior facial height is less in OB patients than in Class I controls, few have examined the difference between the Class III open-bite and Class III non-open-bite populations. Horowitz and co-workers²⁸ examined 52 adults with mandibular prognathism; in sixteen of these the deformity had an open-bite component. There was no significant difference in the posterior facial height in these two groups. However, when all 52 subjects with mandibular prognathism (open-bite and non-open-bite) were compared to subjects in a control group, posterior facial height was significantly less in the prognathic group. When posterior facial height (82 to 83 mm) in the present sample is compared to the values given for posterior facial height in Class I controls (87.7 mm²⁸, 91.7 mm³⁷), the posterior facial height values of the present sample are smaller. Thus, our Class III population exhibits decreased PFH values, whether or not an open-bite component is present.

Clinical implications

In devising a therapeutic regimen for the patient with a Class III open-bite malocclusion, in addition to the routine aspects of the malocclusion, treatment must address the following specific problems: (1) the presence of posterior maxillary dentoalveolar hyperplasia; (2) a steep mandibular plane angle; (3) an oblique gonial angle; (4) a downward and backward position of the mandibular ramus; (5) a long lower anterior face; and (6) the Class III anteroposterior malrelationship.

Although this study did not analyze the spectrum of skeletal and dental components of the Class III open-bite malocclusion and, instead, provides only mean differences between the open-bite and non-open-bite groups, it is impossible to make categorical statements as to the most appropriate treatment modalities for the correction of this deformity. However, we can discuss treatment techniques for the average Class III open-bite malocclusion, realizing that treatment of each case must be individually planned on the basis of the particular dental and skeletal aberrations present in the given patient.

Orthodontic correction of open-bite deformities is prone to failure, as it does not address the underlying causes of the deformity. In fact, the open-bite group has a greater anterior maxillary dentoalveolar height than the non-OB group. Thus, orthodontic extrusion of the anterior teeth is clearly inappropriate treatment.

Not all surgical procedures for correcting open-bite malocclusions have been universally successful. Results of surgery in the mandibular ramus have been

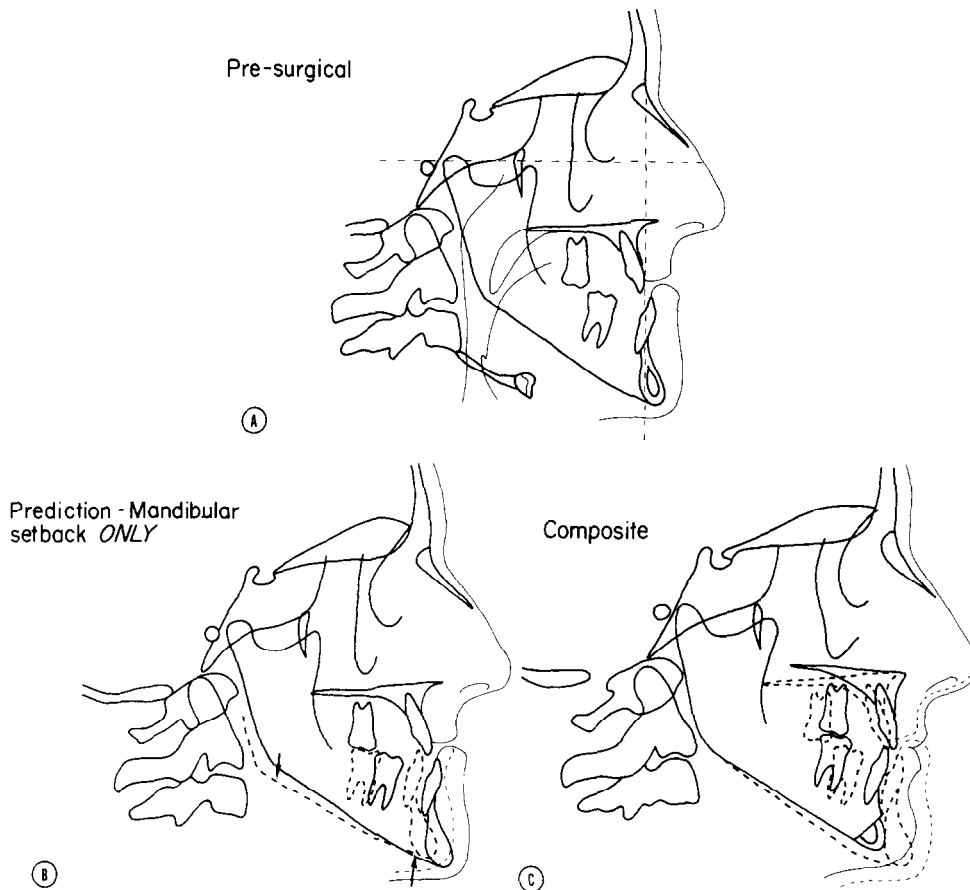


Fig. 3. Cephalometric tracings of a patient who exhibits a Class III open bite malocclusion. **A,** Presurgical tracing demonstrating maxillary retrusion, mandibular protrusion, and slight open bite. **B,** Prediction composite tracing of mandibular setback procedure. Note lengthening of mandibular ramus caused by rotation of mandible to close open bite component. **C,** Postoperative composite tracing following maxillary advancement with posterior intrusion, mandibular setback, and reduction genioplasty. *Note:* The mandibular ramus length is unchanged.

unstable, with variable amounts of postoperative relapse reported.⁵⁹⁻⁶¹ This is not surprising when one carefully examines the biomechanics of this procedure. Fig. 3 demonstrates the effects of correcting a Class III open-bite deformity via a mandibular ramus osteotomy. In its new position, the body of the mandible is rotated in such a fashion that two powerful groups of muscles (the elevators and suprahyoids) are stretched. The posterior aspect of the mandible is now in a more inferior position than it was preoperatively, thus stretching the elevator musculature (the masseter, medial pterygoid, and temporalis). The mandibular symphysis is rotated to a more superior location, stretching the suprahyoid musculature (of questionable importance when also retruding the mandible). Thus, in the mandibular body the second molar teeth serve as a fulcrum for two powerful and opposing muscle groups.

Experimental documentation of the adverse effects of stretching the elevator musculature is offered by

Carlson and Schneiderman.⁶² They cemented bite-opening splints onto the occlusal surfaces of the teeth of adult rhesus monkeys and analyzed the effects on the craniofacial complex. Stretching the elevator muscles in this fashion caused an anterosuperior displacement of the entire maxilla, severe intrusion of the dentition, and a tendency for the masseter muscle to return to its original resting length. Thus, stretching of elevator muscles should be avoided whenever possible as in the clinical situation of closing an open bite via a mandibular ramus operation. The stretched musculature may be the primary reason these operations produce unstable results.

Correction of open-bite via anterior segmental surgical procedures is a very stable procedure.¹³ The stability of these procedures probably relates directly to the noninvolvement of the muscles of mastication in the biomechanics of the surgical change. However, anterior segmental osteotomies have limited use in cases

of gross skeletal open bite and/or cases of gross anteroposterior malrelationships.

The total mandibular alveolar osteotomy proposed by MacIntosh^{3,4} also avoids alteration of the muscles of mastication and produces good stability. However, technical aspects and morbidity of this procedure preclude its use for routine correction of open-bite deformities.^{6,3} The operation also does not correct the posterior maxillary dentoalveolar hyperplasia or the aberrant maxillary occlusal plane angle.

After examining the various aspects of the Class III open-bite malocclusion, one can clearly see that this deformity is not confined to one particular anatomic structure but, instead, involves various aspects of both the maxilla and the mandible. It is not surprising, therefore, that treatment may involve surgery in both jaws. The treatment that would correct most of the open-bite problems in the Class III open-bite deformity would include surgical intrusion of the posterior maxilla via either segmental or total maxillary surgery. This would correct both the posterior maxillary dentoalveolar hyperplasia and the aberrant maxillary occlusal plane angle. Posterior maxillary intrusion also would allow the mandible to autorotate "closed," partially correcting the high mandibular plane angle and decreasing the lower anterior facial height, while at the same time worsening the mandibular protrusion. However, this treatment would now allow the mandible to be retruded via a mandibular ramus osteotomy without stretching the masticatory musculature (Fig. 3, C).

Combined maxillary and mandibular surgery is, in our opinion, the most appropriate and stable method of correcting the Class III open-bite malocclusion in the majority of cases. Not only does it return the dental and skeletal elements of the maxillofacial complex to their proper location, but it does so without upsetting the delicate balance between the soft-tissue elements (musculature in particular) and the skeletal elements. As Carlson and Schneiderman^{6,3} have demonstrated very effectively, in the continuing struggle between the soft and hard tissues of an altered homeostasis, the soft tissues will certainly win.

SUMMARY AND CONCLUSIONS

Lateral cephalograms of 302 adults with Class III malocclusion were studied to determine the frequency of open-bite deformity in the sample. Differences in the skeletal and dental components between those with and those without open-bite as a part of their deformity were evaluated in two groups of 88 patients. The following conclusions can be drawn:

1. Thirty percent of the entire adult Class III sam-

ple exhibited an open-bite component to their Class III malocclusion.

2. The Class III open-bite malocclusion, as compared to the Class III non-open-bite malocclusion, exhibits a larger mandibular plane angle, a larger gonial angle, downward and backward positioning of the mandibular ramus, a longer mandibular length, decreased mandibular protrusion, posterior maxillary and mandibular dentoalveolar hyperplasia, anterior maxillary dentoalveolar hyperplasia, a longer total anterior facial and lower anterior facial height, and no difference in cranial base.

Proper diagnosis and treatment planning in cases of adult Class III open-bite malocclusion may indicate the need for surgical correction of both jaws in a significant number of cases. Since, in the average case, aberrations exist in both the maxilla and the mandible, correction via surgery in one jaw only may significantly compromise esthetic results and functional skeletal and dental stability.

The authors would like to thank Drs. John Spolyar, Donald Shapiro, Martin Moss, James Gallo, John Gaul, and Michael Heath for the use of their cephalograms and Robert L. Wainright for his help with the data analysis.

REFERENCES

1. Köle H: Surgical operations on the alveolar ridge to correct occlusal abnormalities. *Oral Surg* **12**: 277-288, 413-420, 515-529, 1959.
2. Köle H: Results, experience and problems in the operative treatment of anomalies with reverse overbite (mandibular protrusion). *Oral Surg* **19**: 427-450, 1965.
3. MacIntosh RB: Total mandibular alveolar osteotomy. *J Maxillofac Surg* **2**: 210-218, 1974.
4. MacIntosh RB, Carlotti AE: Total mandibular alveolar osteotomy in the management of skeletal (infantile) apertognathia. *J Oral Surg* **33**: 921-928, 1975.
5. Epker BN, Fish LC: Surgical-orthodontic correction of open-bite deformity. *AM J ORTHOD* **71**: 278-299, 1977.
6. Epker BN, Fish LC: The surgical-orthodontic correction of Class III skeletal open-bite. *AM J ORTHOD* **73**: 601-618, 1978.
7. Frost DE, Fonseca RJ, Turvey TA, Hall DJ: Cephalometric diagnosis and surgical-orthodontic correction of apertognathia. *AM J ORTHOD* **78**: 657-699, 1980.
8. Mohnac AM: Maxillary osteotomy in the management of occlusal deformities. *J Oral Surg* **24**: 305-317, 1966.
9. Taylor RG, Mills PB, Brenner LD: Maxillary and mandibular subapical osteotomies for the correction of anterior open-bite. *Oral Surg* **23**: 141-147, 1967.
10. Hinds EC, Kent JN: Diagnosis and selection of surgical procedures in management of open bite. *J Oral Surg* **27**: 939-949, 1969.
11. Kent JN, Hinds EC: Management of dental facial deformities by anterior alveolar surgery. *J Oral Surg* **29**: 13-26, 1971.
12. Bell WH: Correction of skeletal type anterior open-bite. *J Oral Surg* **29**: 706-714, 1971.
13. Bell WH, Dann JJ: Correction of dentofacial deformities by

- surgery in the anterior part of the jaws. *AM J ORTHOD* **64**: 162-187, 1973.
14. Kostecka F: A contribution to the surgical treatment of open-bite. *INT J ORTHOD* **20**: 1082-1092, 1934.
 15. Pichler N, Trauner R: *Mund und kieferchirurgie*, Vienna, 1948, Urban & Schwarzenberg, vol. 1, pp. 626-634.
 16. Shira RB: Surgical correction of open-bite deformities by oblique sliding osteotomy. *Oral Surg* **19**: 275-290, 1961.
 17. Alfaro R, Othon LG, Levine B, Topazian DS, Weyler M, Sleeper HR: Correction of mandibular prognathism with associated apertognathia by intraoral sagittal osteotomy of rami. *Oral Surg* **27**: 285-292, 1969.
 18. Kline SN, Shensa DR, Kahn M: Skeletal open-bite—surgical management: report of case. *J Oral Surg* **28**: 791-794, 1970.
 19. Schuchardt K: Experiences with surgical treatment of some deformities of the jaws: prognathia, micrognathia and open bite. *In* Wallace AB (editor): *Transactions of Second Congress of International Society of Plastic Surgeons*, Edinburgh, 1961, E & S Livingstone, Ltd., pp. 73-78.
 20. Kufner J: Experience with a modified procedure for correction of open bite. *In* Walker RV (editor): *Transactions of the Third International Conference on Oral Surgery*, Edinburgh, 1970, pp. 18-23.
 21. West RA, Epker BN: The posterior maxillary osteotomy: its place in the treatment of selected dentofacial deformities. *J Oral Surg* **30**: 562-575, 1972.
 22. Stoker NC, Epker BN: The posterior maxillary osteotomy: a retrospective study of treatment results. *Int J Oral Surg* **3**: 153-157, 1974.
 23. Bell WH: LeFort I osteotomy for correction of maxillary deformities. *J Oral Surg* **33**: 412-426, 1975.
 24. Wolford LM, Epker BN: The combined anterior and posterior maxillary osteotomy: a new technique. *J Oral Surg* **33**: 842-851, 1975.
 25. Epker BN, Schendel SA: Total maxillary surgery. *Int J Oral Surg* **9**: 1-24, 1980.
 26. Stapf WC: A cephalometric roentgenographic appraisal of the facial pattern in Class III malocclusions. *Angle Orthod* **18**: 20-23, 1948.
 27. Sanborn RT: Differences between facial skeletal patterns of Class III malocclusion and normal occlusion. *Angle Orthod* **25**: 208-222, 1955.
 28. Horowitz SL, Converse JM, Gerstman LJ: Craniofacial relationship in mandibular prognathism. *Arch Oral Biol* **14**: 121-131, 1969.
 29. Ahlgren J: Form and function of Angle Class III malocclusion: a cephalometric and electromyographic study. *Trans Eur Orthod Soc*, pp. 77-88, 1970.
 30. Deitrich UC: Morphological variability of skeletal Class III relationship as revealed by cephalometric analysis. *Trans Eur Orthod Soc*, pp. 131-143, 1970.
 31. Ridell A, Soremark R, Lundberg M: Roentgenographic-cephalometric analysis of the jaws in subjects with and without mandibular protrusion. *Acta Odontol Scand* **29**: 103-121, 1971.
 32. Jacobson A, Evans CB, Preston CB, Sadowsky PL: Mandibular prognathism. *AM J ORTHOD* **66**: 140-171, 1974.
 33. Ellis E, McNamara JA Jr: Components of adult Class III malocclusion. *J Oral Maxillofac Surg* **42**: 295-305, 1984.
 34. Sassouni V, Nanda S: Analysis of dentofacial vertical proportions. *AM J ORTHOD* **50**: 801-823, 1964.
 35. Subtelny JD, Sakuda M: Open-bite: diagnosis and treatment. *AM J ORTHOD* **50**: 337-358, 1964.
 36. Nahoum HI: Vertical proportions and the palatal plane in anterior open-bite. *AM J ORTHOD* **59**: 273-282, 1971.
 37. Nahoum HI, Horowitz SL, Benedicto EA: Varieties of anterior open-bite. *AM J ORTHOD* **61**: 486-492, 1972.
 38. Enunlu N: Palatal and mandibular plane variations in open bite cases with varying aetiology. *Trans Eur Orthod Soc*, pp. 165-171, 1974.
 39. Lowe AA: Correlations between orofacial muscle activity and craniofacial morphology in a sample of control and anterior open-bite subjects. *AM J ORTHOD* **78**: 89-98, 1980.
 40. Schendel SA, Eisenfeld J, Bell WH, Epker BN, Mischevich DJ: The long-face syndrome: vertical maxillary excess. *AM J ORTHOD* **70**: 398-408, 1976.
 41. Hapak FM: Cephalometric appraisal of the open-bite case. *Angle Orthod* **34**: 65-72, 1964.
 42. Schudy FF: Vertical growth versus anteroposterior growth as related to function and treatment. *Angle Orthod* **34**: 75-93, 1964.
 43. Björk A: Prediction of mandibular growth rotation. *AM J ORTHOD* **55**: 585-599, 1969.
 44. Sassouni V: A classification of skeletal facial types. *AM J ORTHOD* **55**: 109-118, 1969.
 45. Isaacson JR, Isaacson RJ, Speidel TM, Worms FW: Extreme variation in vertical facial growth and associated variation in skeletal and dental relations. *Angle Orthod* **41**: 219-229, 1971.
 46. Kim YH: Overbite depth indicator with particular reference to anterior open-bite. *AM J ORTHOD* **65**: 586-611, 1974.
 47. Arvystas MG: Treatment of anterior skeletal open-bite deformity. *AM J ORTHOD* **72**: 147-164, 1977.
 48. Richardson A: Skeletal factors in anterior open-bite and deep overbite. *AM J ORTHOD* **56**: 114-127, 1969.
 49. Björk A: The face in profile. *Svensk Tandl Tidsskr* **40**: Suppl. 5B, 1947.
 50. Prakash P, Margolis HI: Dento-craniofacial relations in varying degrees of overbite. *AM J ORTHOD* **38**: 657-673, 1952.
 51. Atherton JD: The influence of the face height upon the incisor occlusion and lip posture. *Dent Pract* **15**: 227-231, 1965.
 52. Horowitz SL, Thompson RH: Variations of the craniofacial skeleton in postadolescent males and females. *Angle Orthod* **34**: 97-102, 1967.
 53. Moyers R: *Handbook of orthodontics*, ed. 2, Chicago, 1963, Year Book Medical Publishers, Inc.
 54. Downs WB: Variations in facial relationships: their significance in treatment and prognosis. *AM J ORTHOD* **34**: 812-840, 1948.
 55. Riedel RA: Relation of maxillary structures to cranium in malocclusion and in normal occlusion. *Angle Orthod* **22**: 142-145, 1952.
 56. Steiner CC: Cephalometrics for you and me. *AM J ORTHOD* **39**: 729-755, 1953.
 57. Jacobson A: The "Wits" appraisal of jaw disharmony. *AM J ORTHOD* **67**: 125-138, 1975.
 58. McNamara JA Jr: A method of cephalometric analysis, *In* McNamara JA Jr, Ribbens KA, Howe RP (editors): *Clinical alteration of the growing face*, Monograph 14, Craniofacial Growth Series, Ann Arbor, 1983, Center for Human Growth and Development, The University of Michigan.
 59. Poulton DR, Ware WH: Surgical-orthodontic treatment of severe mandibular retrusion. *AM J ORTHOD* **59**: 244-265, 1971.
 60. McNeill WR, Hooley JR, Sundberg RI: Skeletal relapse during intermaxillary fixation. *J Oral Surg* **31**: 212-227, 1973.
 61. Epker BN, Wolford LM, Fish LC: Mandibular deficiency syn-

- drome: surgical considerations for mandibular advancement. *Oral Surg* **45**: 349-363, 1978.
62. Carlson DS, Schneiderman ED: Cephalometric analysis of adaptations after lengthening of the masseter muscle in adult rhesus monkeys. *Arch Oral Biol* **28**: 627-637, 1983.
63. Rittersma J: Total mandibular osteotomy. *J Oral Surg* **39**: 903-906, 1981.

Reprint requests to:

Dr. Edward Ellis III
Department of Oral and Maxillofacial Surgery
Room 2046
University of Michigan School of Dentistry
Ann Arbor, MI 48109

BOUND VOLUMES AVAILABLE TO SUBSCRIBERS

Bound volumes of the AMERICAN JOURNAL OF ORTHODONTICS are available to subscribers (only) for the 1984 issues from the Publisher, at a cost of \$42.50 (\$51.00 international) for Vol. 84 (January-June) and Vol. 85 (July-December). Shipping charges are included. Each bound volume contains a subject and author index and all advertising is removed. Copies are shipped within 30 days after publication of the last issue in the volume. The binding is durable buckram with the journal name, volume number, and year stamped in gold on the spine. *Payment must accompany all orders.* Contact The C. V. Mosby Company, Circulation Department, 11830 Westline Industrial Drive, St. Louis, Missouri 63146, USA; phone (800) 325-4177, ext. 351.

Subscriptions must be in force to qualify. Bound volumes are not available in place of a regular Journal subscription.