

JCO-Online Copyright 2009

Clinical Management of the Bonded Herbst Appliance

VOLUME 17 : NUMBER 07 : PAGES (456-463) 1983

RAYMOND P. HOWE, DDS, MS

JAMES A. MCNAMARA, JR., DDS, PHD

The Herbst appliance is used in the correction of Class II malocclusion associated with mandibular retrognathia. Several articles describing design modification have focused on the methods by which the Herbst is attached to the maxillary and mandibular dental arches, including the use of orthodontic bands,¹⁻⁴ stainless steel crowns,⁵ and bonded acrylic splints.^{6,7}

Over the last few years, we have been developing a system of clinical management of the bonded Herbst appliance ([Fig. 1](#)). This effort has been frustrating, due to appliance breakage, splint loosening, and other technical problems; but most of the difficulties encountered in the initial use of the bonded Herbst have been overcome. The following step-by-step protocol is suggested. In outlining this procedure, it is assumed that the usual diagnostic records have been taken and thoroughly studied, and that the use of a Herbst appliance is indicated. Furthermore, it is assumed that the relationship of the maxillary and mandibular incisor teeth to lower anterior facial height has been evaluated prior to treatment, and that the incisors are now in an acceptable position.⁸

Impression Taking and Bite Registration

During the first appointment of the Herbst phase of treatment, all teeth are inspected and, if necessary, cleaned with a toothbrush or a rotating rubber cup prior to taking impressions. Accurate, bubble-free maxillary and mandibular alginate impressions are then taken, and a wax bite registration is obtained with the patient's mandible postured approximately 4mm forward. If a 4mm advancement is insufficient to correct the malocclusion, a procedure for readvancing the mandible, which will be described later, can be employed.

To ensure an accurate wax bite registration, the patient should practice the forward repositioning of the mandible before the actual procedure is performed. This allows the clinician to inspect the molar relationship and to use the incisor overjet as an index of the amount of forward repositioning necessary. Care must be taken to align the skeletal midlines, using the dental midlines as reference points. For example, if there is a 2mm deviation of the dental midlines when the skeletal midlines are coincident, the same 2mm deviation must be reproduced in the wax bite. Once the patient has practiced aligning the skeletal midlines and posturing the mandible forward, the wax bite registration can be taken. Wax coverage of the anterior teeth should be avoided so that the overjet and midline relationship can be observed ([Fig. 2](#)). It also is important to allow sufficient vertical opening for the construction of the acrylic splints.

Before the first appointment has ended, the patient's parent should be questioned regarding possible contraindications to the administration of an antiallogogue.^{9,10} If there are no contraindications, the patient is given an envelope containing the prescribed drug and is instructed

to take the dosage one hour before the next appointment, at which time the appliance will be delivered.

Since an accurate fit of the bonded splints is critical, every precaution must be taken to maintain accuracy throughout the impression taking and appliance construction. Any tooth movement that is likely to occur after taking the appliance construction impressions must be considered. This is especially important if individual teeth are in the process of erupting, or if the patient has undergone recent orthodontic treatment such as incisor repositioning, rapid palatal expansion, or facebow treatment. If tooth movement is likely, invisible retainers should be constructed, as described by Ponitz,¹¹ and given to the patient to wear until the delivery of the Herbst appliance.

Construction

The impressions are poured in dental stone, and any bubbles or imperfections are removed. The models are inserted into the wax bite registration and checked. Then the models are sent to an orthodontic laboratory with a prescription for the fabrication of maxillary and mandibular bonded acrylic splints for use with the Herbst appliance. The prescription should state that all maxillary teeth, exclusive of the maxillary central and lateral incisors, should be included in the upper acrylic splint ([Fig. 3](#)), and all mandibular teeth should be included in the lower acrylic splint ([Fig. 4](#)) in order to minimize individual tooth movement in the mandibular arch. Lower incisor coverage may be omitted if posterior anchorage is adequate and the patient has an anterior open bite. Auxiliary attachments such as buccal tubes or maxillary palatal expansion devices are requested, if needed.⁷

After the assembled appliance has been returned from the laboratory, it is replaced on the construction models and tested for protrusive, opening, and lateral movements. If the appliance binds in any of these movements, the upper and lower telescoping elements are removed, keeping left and right sides separate, and each of the four connection holes are reamed out to permit more freedom of movement ([Fig. 5](#)). The appliance is then reassembled and rechecked on the construction models. Even though this

procedure is usually followed at the laboratory, it is important to recheck the freedom of movement, since binding may dislodge the bonded splints.

Preparations for Bonding

The patient is seated and the prior administration of the antisialogogue is confirmed. The upper and lower halves of the appliance are tried in the mouth separately to check the fit of the acrylic splint ([Fig. 6](#)). Then both splints are tried in with the plungers and sleeves engaged, in order to check the length of the lower plungers as they exit the distal end of the upper sleeves ([Fig. 7](#)). Whenever second molars are present, the distal end of the lower plunger can extend as far back as the distal end of the maxillary axle. However, if only first molars are present, the distal end of the plunger must be cut flush with the posterior opening of the sleeve. This is done to prevent the plungers from impinging on and ulcerating the mucosa overlying the mandibular ramus, which is repositioned forward by the appliance. If either the left or the right plunger extends too far out of the distal end of its sleeve and impinges on the mucosa, it is marked, removed, and shortened to the

desired length. Once rounded, it is replaced and rechecked. If this step is omitted and the plunger impinges on the mucosa, ulceration and serious infection can result.

After the length of the plungers has been checked, the splints are removed, cleaned, and dried. In preparation for bonding, the lower plungers are removed from the lower splint by unscrewing the screws on the left and right sides. If there is a difference in the lengths of the left and right plungers, they are kept separate. The upper splint is bonded with the left and right sleeves in place ([Fig. 8](#)).

Bonding

The appropriate teeth in both arches are cleaned using a rotating rubber cup and pumice. The arches are then isolated using cheek retractors that have extensions into the buccal vestibule, but that do not cross over the occlusal surface of the dental arches. The teeth are carefully etched and dried in preparation for bonding. Because of the forces of mastication involved and the required bond strength, a mixed paste-paste system is preferable to a no-mix system, and more suitable for bonding a large acrylic splint. In addition, the bonding agent should be of low viscosity and have a long working time (at least 3 minutes) to permit cleanup of the excess bonding medium.

A four-handed approach is advisable when bonding the acrylic splints. As the teeth are being etched and dried, an auxiliary paints the bonding surfaces of the lower splint with a plastic bracket primer, which improves bonding strength between the acrylic appliance and the bonding medium. The mandibular teeth are redried and strict isolation is maintained by placing small, foil-backed Theta Dri-Angles vertically beside the tongue with the foil side toward the teeth ([Fig. 9](#)).

The auxiliary then mixes the two-paste bonding medium and loads the lower acrylic splint. The clinician firmly places the loaded acrylic splint onto the mandibular dental arch and holds it in place. The splint is then carefully inspected, and if any voids are evident, a composite syringe is used to inject additional adhesive through the small openings in the occlusal surface of the splint ([Fig. 10](#)). Excess adhesive that has exuded from under the splint is wiped away using cotton-tipped applicators ([Fig. 11](#)). The 3-minute working time of the bonding medium is ample for complete cleanup of excess material while the splint is being held in place. It is important to monitor the salivary control visually in order to avoid contamination of the curing adhesive. The use of rubber gloves will prevent the bonding material from adhering to the fingers and facilitate hand cleanup once the procedure has been completed.

The maxillary splint is bonded in a similar manner, except that the left and right sleeves remain attached during bonding. If, in anticipation of the bonding procedure, the mandibular arch is not dry, one of two courses of action can be followed. The order of bonding the splints can be reversed so that the maxillary arch is bonded first. This may allow additional time for the antisialogogue to affect salivary secretion. If this proves unsuccessful and the entire mandibular arch cannot be isolated, the mandibular splint can be sectioned between the mandibular central incisors ([Fig. 12](#)) and bonded in two separate procedures.¹² Usually half of the mandibular jaw can be adequately isolated for bonding of the splint, even if some saliva is present. As the second half of the mandibular splint is bonded, additional bonding adhesive can be injected into the sectioned area to reunite the two halves of the splint.

Final Assembly

First, the lower left plunger is inserted into the upper sleeve. Then the patient is asked to posture the mandible forward so that the free end of the plunger can be placed over the lower axle and the screw inserted. The lower right plunger is inserted in a similar manner and all screws are tightened. Manipulation of the screw is made somewhat easier by placing a small piece of green wax over the tip of the screwdriver and inserting the screwdriver through the wax into the slot of the screw ([Fig. 13](#)). The wax holds the screw on the tip of the screwdriver until it is inserted and tightened. Magnetic, scissor-tipped, and plastic sleeve-tipped screwdrivers can also be used for this purpose.

With the telescoping mechanism in place ([Fig. 14](#)), the patient is asked to gently move the mandible in all excursions, while the

clinician explains that the appliance will limit the range of movement. The clinician shows the patient how to avoid forceful lateral and retrusive movements of the lower jaw, since these movements can break the adhesive bond and cause the appliance to become loose.

Next, the patient is given a mirror and asked to open the mouth as wide as possible. If, during wide opening, the plunger and sleeve assemblies telescope apart and become disengaged ([Fig. 15](#)), the patient is shown how to reinsert the lower plungers into the upper sleeves by holding the mouth wide open, aligning the lower plungers with the upper sleeves, and then closing the mouth so that the plungers reinsert into the sleeves.

Instructions

Once appliance delivery is complete, the patient and the patient's parents are given the following information. The patient is told that it will take several days to get used to the Herbst appliance. During this period, the jaw muscles may become tired and sore. With time, however, the patient will become increasingly comfortable. Also, the connections on the appliance may rub against the cheeks, causing irritation. This condition is temporary and can be ameliorated by placing soft wax over the connections until the irritation passes. Furthermore, the patient is likely to experience some difficulty in chewing. A soft diet is suggested until the patient accommodates to the appliance and is able to chew. The initial difficulty experienced in wearing the Herbst appliance usually passes quickly. However, if the patient experiences pain that increases over time and is accompanied by hot or swollen cheeks and a bad taste and odor in the mouth, an ulcerated area of mucosa may be infected, and the patient must be seen immediately.

The patient's responsibilities in caring for the mouth and the Herbst appliance include paying attention to diet, cleaning, and fluoride rinsing. The patient is cautioned to avoid hard and sticky foods that may dislodge the appliance. It is especially important for the patient to restrict the intake of foods containing sugar, in order to avoid damage to the teeth from decalcification and caries. The patient is also instructed to clean the teeth and appliance by brushing carefully several times each

day (an oral irrigation device can be used in addition to the toothbrush), and to use a fluoride rinse.

The patient is seen at regular intervals to check progress and to inspect the appliance. During each progress appointment, the four screws on the appliance are tightened and the condition of the bonded splints is checked. If any part of a splint becomes loose, the entire splint must be removed and rebonded.

Subsequent Advancement

If the initial amount of mandibular advancement, built into the Herbst appliance at the time of construction, is inadequate in establishing an acceptable incisor and molar relationship, the appliance can be reactivated two or three months after its initial placement. This is accomplished by removing the upper left and right sleeves and replacing them with longer sleeves, thereby repositioning the mandible farther forward ([Fig. 16A](#)). An alternative procedure involves sliding a short section of unused upper sleeve over each lower plunger ([Fig. 16B](#)). Regardless of the technique employed, advancement can be repeated at two-to-three-month intervals until the desired amount of mandibular repositioning is obtained.

Figures

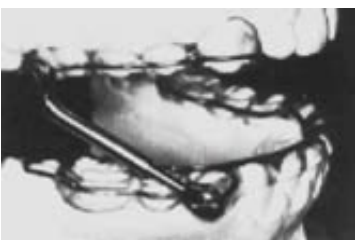

Fig. 1 Herbst appliance with maxillary and mandibular acrylic splints.

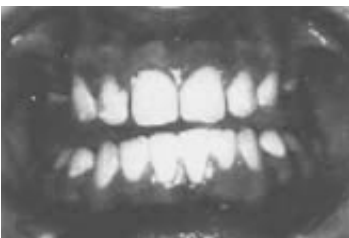

Fig. 2 Proper wax bite registration allows visual inspection of the dental midline, overjet correction, and vertical opening.

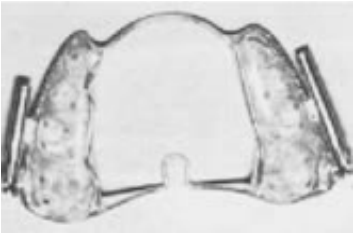


Fig. 3 Maxillary acrylic splint with transpalatal arch and upper sleeves attached.

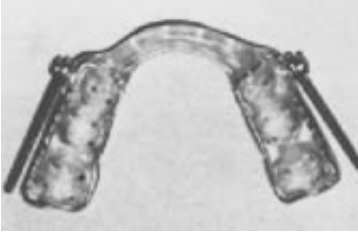

Fig. 4 Mandibular splint with Incisor and cuspid coverage and lower plungers attached.

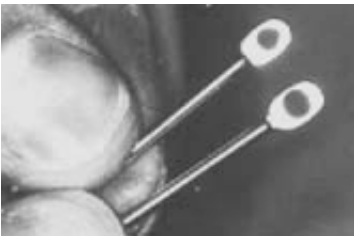

Fig. 5 The small connecting holes are enlarged to permit greater lateral movement.

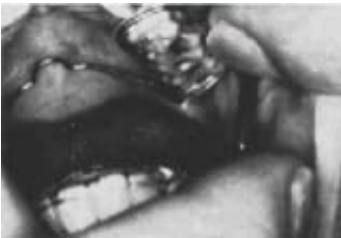

Fig. 6 Try in stage of acrylic splints.

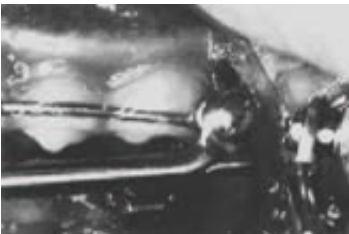

Fig. 7 Intraoral inspection of the distal extension of the lower plunger as it exits the upper sleeve.

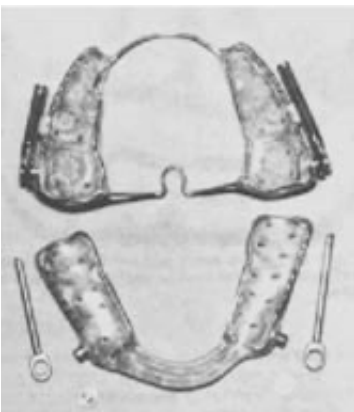


Fig. 8 Splints ready for bonding. Mandibular splint with plungers removed; maxillary splint with sleeves attached.

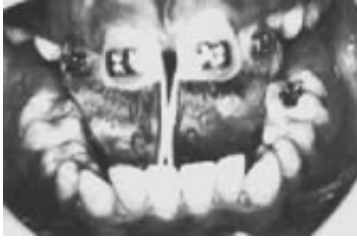

Fig. 9 Mandibular dental arch Isolated with cheek retractors and foil-backed absorbent wafers in place.

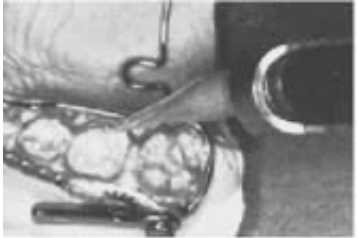

Fig. 10 A composite syringe can be used to inject bonding material into any voids left once the splint has been placed on the teeth (simulated on model).

Fig. 13 A small bead of green wax is used to hold the slotted screw onto the screwdriver.

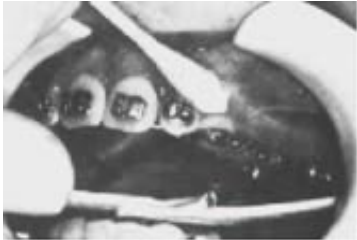

Fig. 11 A cotton-tipped applicator is used to wipe excess bonding material from the cervical area.

Fig. 16

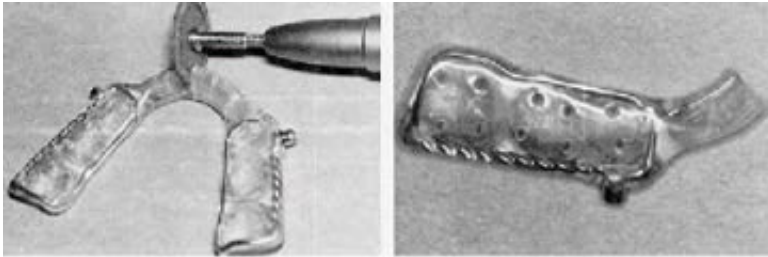


Fig. 12 A. The lower splint can be sectioned. B. Each half is then bonded separately.

Fig.




Fig.

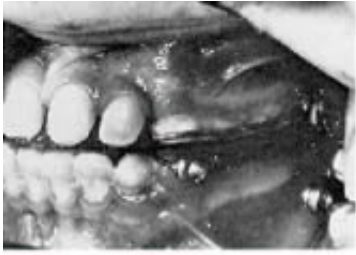

Fig. 14 Appliance delivery is complete and the mandible is repositioned forward.

Fig.

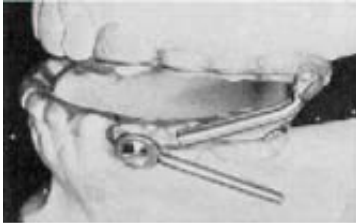


Fig. 15 Plunger and sleeve assembly may telescope apart on wide opening (simulated on model).

Fig.

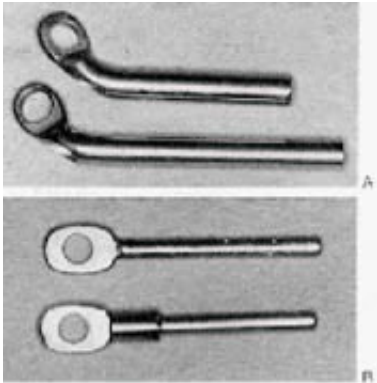


Fig. 16 Reactivation is accomplished by exchanging the original upper sleeves (A), or by adding a short section of unused sleeve over the lower plunger (B).

Fig.