

A Prospective Study of the Short-term Treatment Effects of the Acrylic-splint Rapid Maxillary Expander Combined with the Lower Schwarz Appliance

Lisa K. Wendling, DDS, MS^a; James A. McNamara Jr, DDS, PhD^b; Lorenzo Franchi, DDS, PhD^c; Tiziano Baccetti, DDS, PhD^d

Abstract: This prospective clinical study evaluated the short-term treatment effects of acrylic-splint rapid maxillary expander in conjunction with lower Schwarz appliance (RME-Sz) therapy to the acrylic-splint rapid maxillary expansion alone (RME-only group). Pretreatment and posttreatment lateral cephalograms were analyzed for 25 RME patients and 19 RME-Sz patients. The average time between films ranged between nine and 12 months. Statistical comparisons of the treatment changes in the RME-only and RME-Sz groups were performed by means of independent sample *t*-tests ($P < .05$). The largest difference between the two groups was in lower anterior facial height (LAFH). The normally occurring increase in LAFH was not observed in the RME-only group during the treatment period, indicating that the acrylic-splint expander had a posterior “bite block effect” on the developing craniofacial complex. LAFH increased by 1.7 mm in the RME-Sz group, a value similar to that observed in untreated individuals. Slight forward displacement of the maxilla was observed when RME was used alone, and the sagittal position of the maxilla remained unchanged in the RME-Sz group. A significant amount of intrusion of the maxillary molars (−0.8 mm) was noted in the RME-only group, whereas the maxillary molars were prevented from erupting in the RME-Sz group. The lower dentition showed a significantly greater amount of extrusion in the RME-Sz group than in the RME-only group. Finally, the Sz appliance prevented the mesial movement of the lower molars during the treatment period. (*Angle Orthod* 2004;75:7–14.)

Key Words: Rapid maxillary expansion; Schwarz appliance; Cephalometrics; Orthodontic treatment

INTRODUCTION

During the last two decades, the bonded acrylic-splint rapid maxillary expander¹ (RME) has received considerable

interest from the orthodontic community. This design of the appliance, typically used in mixed dentition patients, does not require banding of the dentition before fabrication. Treatment effects other than simply transverse expansion of the dental arches in young patients have been suggested for the bonded RME. These effects include bite closure through the presumed intrusive force produced by the posterior bite block effect of the acrylic-splint design.^{2,3} In addition, spontaneous Class II and Class III corrections can be observed in some mixed dentition patients.^{1,4}

The palatal acrylic coverage incorporated into the Haas-type RME appliance designs⁵ has been deemed undesirable by many orthodontists because of potential food entrapment and mucosal ulceration. Howe² described a bonded acrylic maxillary expansion appliance that did not cover the occlusal surfaces of the posterior teeth and, more importantly, lacked acrylic palatal coverage. He reported that this appliance could be used when band placement was difficult or impossible for patients with severe dental rotations or for patients in the deciduous or mixed dentition who would benefit from the bonded design.

Interest in vertical dimension control led to modifications in the acrylic maxillary expansion appliance design. In

^a Graduate Orthodontic Program, The University of Michigan, Ann Arbor, Michigan and Private Practice, Flint, Mich.

^b Thomas M. and Doris Graber Endowed Professor of Dentistry, Department of Orthodontics and Pediatric Dentistry, School of Dentistry; Professor of Cell and Developmental Biology, School of Medicine; and Research Scientist, Center for Human Growth and Development, The University of Michigan, Ann Arbor, Michigan; Private practice of orthodontics, Ann Arbor, Mich.

^c Research Associate, Department of Orthodontics, The University of Florence, Florence, Italy; Thomas M. Graber Visiting Scholar, Department of Orthodontics and Pediatric Dentistry, School of Dentistry, The University of Michigan, Ann Arbor, Mich.

^d Assistant Professor, Department of Orthodontics, The University of Florence, Florence, Italy; Thomas M. Graber Visiting Scholar, Department of Orthodontics and Pediatric Dentistry, School of Dentistry, The University of Michigan, Ann Arbor, Mich.

Corresponding author: James A. McNamara, DDS, PhD, Department of Orthodontics and Pediatric Dentistry, School of Dentistry, The University of Michigan, Ann Arbor, MI 48109-1078 (e-mail: mcnamara@umich.edu).

Accepted: March 2004. Submitted: November 2003.

© 2004 by The EH Angle Education and Research Foundation, Inc.

1984, Spolyar⁶ advocated the incorporation of occlusal acrylic coverage to increase the vertical dimension and eliminate anterior crossbite relationships during expansion. Alpern and Yurosko⁷ also recommended the addition of a bite plane to maxillary expansion appliances in adults to eliminate occlusal intercuspation that may interfere with palatal expansion and to provide vertical restraint on the posterior dentition during the expansion process. They advocated the incorporation of a posterior bite plane in RME appliances used on patients who exhibit increased vertical dimension to provide vertical orthopedic restraint to the maxilla.

McNamara^{3,8} described an acrylic-splint RME that incorporated a maxillary posterior bite plane. The appliance consisted of a stainless steel framework adapted to the posterior dentition to which a midline palatal expansion screw was attached. Clear 3-mm-thick splint Biocryl[®] (Great Lakes Orthodontics, Tonawanda, NY) was applied to the framework and over the occlusal surfaces of the maxillary posterior teeth using a thermal pressure machine. The occlusal coverage acted as a posterior bite block and was hypothesized to inhibit the vertical eruption of the posterior teeth during treatment.

A typical treatment protocol for patients showing a moderate amount of crowding and the need for expansion in both arches is the combination of the acrylic-splint rapid maxillary expander and the lower Schwarz (Sz) removable plate.¹ The protocol comprised an initial phase with the removable expansion plate in the lower arch activated once per week for four to five months, followed immediately by rapid maxillary expansion. Dentoalveolar decompensation of the lower arch by means of the Schwarz appliance provides a widened dentoalveolar template to which the maxillary arch can be expanded.⁴

Studies on the effects of the bonded RME appliance alone on the dentition and the facial skeleton are limited in number. Although several studies have evaluated the treatment effects produced by the bonded RME by means of dental cast analysis,⁹⁻¹¹ there are only a few published reports that have considered the cephalometric effects of this appliance on lateral headfilms. Sarver and Johnston¹² compared the effects of the bonded RME appliance to a Haas-type banded device. They examined the effect of the acrylic-splint expander in 20 patients with a mean age of 10.8 years at the beginning of treatment. The effects of acrylic-splint treatment were compared with the findings from 60 patients who wore Haas-type expanders and who had been studied previously by Wertz.¹³ A decrease in the displacement of the maxilla was noted in the bonded appliance group, and it was confirmed in a more recent study by Asanza et al.¹⁴ Sarver and Johnston¹² suggested that the inferior displacement of the maxilla might be limited during treatment by the forces placed on the dentition by the elevator musculature and by the force associated with the stretch of other soft tissues.

Reed et al¹⁵ compared the treatment outcomes of 38 patients treated with a banded expander with those of 55 patients treated with a bonded RME appliance. Both lateral cephalometric radiographs and orthodontic study models were evaluated. Overall, the banded rapid palatal expansion group had a slightly more vertical change than did the bonded group.

A study by Akkaya et al¹⁶ evaluated the sagittal and vertical effects of the bonded RME in a group of 12 subjects at the mean starting age of 12 years. The authors found an anterior displacement of the maxilla in relation to the cranial base and a downward and backward rotation of the mandible associated with the sagittal maxillary change. The interincisal angle and the overjet increased significantly in subjects treated with the bonded maxillary expander.

To our knowledge, to date, the literature does not report any cephalometric investigation of the dental and skeletal changes produced by the Schwarz appliance. More significantly, no scientific contribution is available regarding the effects of a combined expansion protocol that includes the bonded RME and the Schwarz appliance.

The aim of this prospective clinical study was to evaluate cephalometric data gathered from a group of children treated with rapid maxillary expansion with a bonded acrylic splint combined with a lower Schwarz appliance to compare the skeletal and dentoalveolar effects of this treatment protocol with the dentoskeletal changes produced by the bonded RME alone.

MATERIALS AND METHODS

The 58 patients obtained from a single-group orthodontic practice included in this study underwent maxillary expansion treatment alone or in conjunction with mandibular dental expansion with a lower Schwarz appliance. Lateral cephalograms were obtained prospectively at the beginning of treatment (T_1) and after the removal of the acrylic-splint expander (T_2).

Of the 58 children, 14 were excluded from the study at T_2 observation. These patients were excluded because their mandible was postured forward in the T_2 film (possible reasons for this somewhat unusual observation will be discussed later).

Of the 44 patients, 25 were treated with RME alone (RME-only group) and 19 underwent RME in conjunction with lower Schwarz appliance therapy (RME-Sz group). Both treatment groups comprised subjects with a mild to moderate degree of crowding, associated with either Class I or Class II malocclusions. The RME-only group consisted of 10 boys and 15 girls whose average age was 9 years eight months at the time of the T_1 film and 10 years five months at T_2 . The RME-Sz group consisted of 10 boys and nine girls who averaged 9 years of age at the beginning of treatment and 10 years one month at the end of treatment. The mean treatment duration for the RME-Sz group was

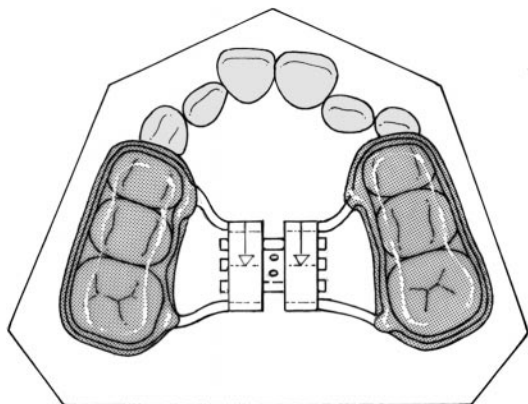


FIGURE 1. The acrylic-splint rapid maxillary expander (after McNamara and Brudon).¹

12.1 months and that for the RME-only group was 9.7 months.

Treatment protocol

The rapid maxillary expansion appliance (Figure 1) consisted of a Hyrax-type screw (Leone, Sesto Fiorentino, Italy) secured to the maxillary arch with a 0.045-inch-wire framework imbedded in 3 mm of acrylic covering the buccal, lingual, and occlusal surfaces of the first and second deciduous molars and the first permanent molars. The appliance was bonded to the maxillary arch with ExcelTM adhesive (Reliance Orthodontic Products, Itasca, Ill) according to a standardized protocol.¹

The RME patients had the rapid maxillary expansion appliance activated once per day. A single activation resulted in about 0.2 mm of expansion of the midline jackscrew per day. The patients were given appointments at 2- or 4-week intervals until the desired amount of expansion was achieved. Typically, the bonded RME appliance was activated until the lingual cusps of the maxillary posterior teeth approximated the buccal cusps of the mandibular posterior teeth. Patients then were seen at 6-week intervals for an average of five additional months. At the end of the retention period, the appliance was removed and a posttreatment lateral cephalogram (T_2) was taken at the same appointment.

Subjects undergoing combined therapy with the Schwarz appliance (Figure 2) began treatment with this removable dental expansion device worn in the mandible.¹ Patients were instructed to activate the midline expansion screw once a week, which resulted in approximately 1 mm of expansion per month. After an average of three to five months of treatment with the Schwarz appliance, the bonded RME device was delivered. The protocol for activation with the maxillary expander was identical to that used for the RME subjects.

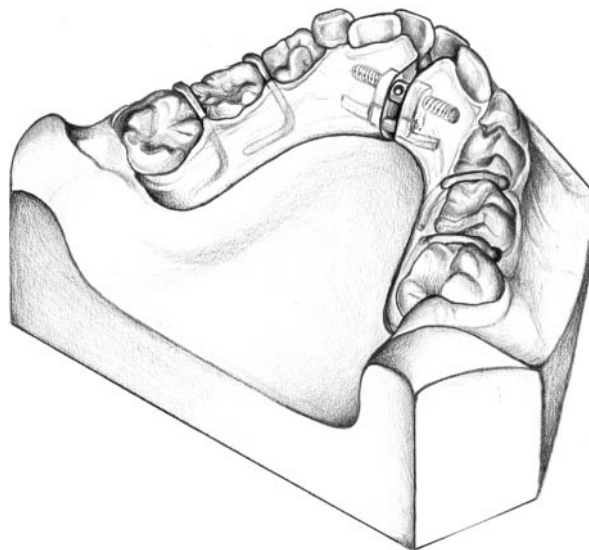


FIGURE 2. The lower Schwarz expansion plate (after McNamara and Brudon).¹

Cephalometric analysis

Lateral cephalograms were available for each subject at T_1 and T_2 . Serial lateral cephalograms were traced at a single sitting by the primary investigator (LKW), verified by a second investigator (JAM), and digitized using customized digitization package. The magnification factor of cephalograms was standardized at 8%. A cephalometric and regional superimposition analysis containing measures chosen from the analyses of McNamara,¹⁷ McNamara et al,^{18,19} Ricketts,²⁰ Steiner,²¹ and the Wits appraisal²² was performed on each cephalogram.

From the digitizations, 32 linear and angular measurements were generated. Horizontal movements of the maxillary teeth were measured from the pterygoid vertical (a line perpendicular to Frankfort horizontal drawn from the most posterosuperior point on the pterygomaxillary fissure), whereas vertical change was measured relative to the palatal plane. Reference lines for determining mandibular dental movement included the mandibular plane and pogonion perpendicular, a line tangent to pogonion and perpendicular to the mandibular plane.¹⁸ In addition, changes in the dentition were measured using regional superimpositions based on fiducial registration points. Reference lines were constructed parallel and perpendicular to the Frankfort horizontal at the pterygomaxillary fissure in the maxilla and to the mandibular plane at pogonion in the mandible.¹⁷⁻¹⁹

Statistical analysis

Descriptive statistics, including means and standard deviations, were calculated for each of the cephalometric measures. Independent sample Student's *t*-tests were used to examine between-group differences of pretreatment morphology. Statistical significance was tested at $P < .05$.

TABLE 1. Comparison of Starting Form between the RME-only Group and the RME-Schwarz Group^a

| Cephalometric Measures | RME | | RME-SZ | | Significance |
|-------------------------------------|-------|-----|--------|-----|--------------|
| | Mean | SD | Mean | SD | |
| Maxillary Skeletal | | | | | |
| SNA (°) | 80.2 | 3.3 | 79.6 | 2.9 | NS |
| Na perpendicular to point A (mm) | -1.4 | 3.1 | -2.4 | 2.5 | NS |
| Maxillary length (Co-A) (mm) | 87.5 | 4.6 | 84.5 | 4.8 | NS |
| Mandibular Skeletal | | | | | |
| SNB (°) | 75.9 | 3.6 | 76.0 | 3.0 | NS |
| Na perpendicular to pogonion (mm) | -9.7 | 5.3 | -10.2 | 5.0 | NS |
| Condylion to gonion (mm) | 50.1 | 3.8 | 48.2 | 3.2 | NS |
| Gonion to pogonion (mm) | 71.6 | 3.6 | 69.2 | 2.9 | * |
| Mandibular length (Co-Gn) (mm) | 108.5 | 5.6 | 104.5 | 3.9 | * |
| Maxilla to Mandible | | | | | |
| ANB (°) | 4.4 | 2.6 | 3.6 | 1.8 | NS |
| Wits (mm) | -0.3 | 2.9 | -1.4 | 2.3 | NS |
| Maxillomandibular differential (mm) | 21.6 | 4.2 | 21.5 | 3.3 | NS |
| Vertical | | | | | |
| SN to occlusal plane (°) | 20.8 | 5.0 | 21.5 | 3.8 | NS |
| SN to palatal plane (°) | 6.8 | 4.2 | 7.3 | 3.1 | NS |
| SN to mandibular plane (°) | 35.3 | 6.1 | 35.5 | 5.0 | NS |
| Lower facial height (ANS-Me) (mm) | 64.7 | 5.2 | 62.3 | 4.5 | NS |
| Maxillary Dental | | | | | |
| Upper 1 to SN (°) | 102.5 | 6.5 | 101.2 | 7.4 | NS |
| Mandibular Dental | | | | | |
| Lower 1 to A-pogonion (mm) | 2.0 | 1.7 | 1.4 | 1.2 | NS |
| Lower 1 to mandibular plane (°) | 94.1 | 6.1 | 89.9 | 6.8 | * |
| Interdental | | | | | |
| Interincisal angle (°) | 127.0 | 4.8 | 134.6 | 9.4 | ** |

^a NS, indicates not significant; RME, rapid maxillary expander; SZ, Schwarz.

* $P < .05$.

** $P < .01$.

Comparison of T_2 - T_1 changes over time between RME-only group and RME-Sz group also was accomplished by way of independent sample Student's *t*-tests. The error of the data acquisition method has been described previously by McNamara et al.¹⁹

RESULTS

Comparison of starting form

Means and standard deviations for the cephalometric variables derived before orthodontic treatment are shown in Table 1. Significant between-group differences were noted for only a few measures. The RME-SZ treatment groups had significantly shorter mandibles (condylion to gnathion and gonion to pogonion) than seen in the RME-only group. The lower incisors were more upright in the RME-Sz treatment group, in association with a more obtuse interincisal angle. For all other measures, the two treatment groups were similar.

Analysis of treatment effects

Descriptive statistics for changes that occurred during treatment, along with the between-group comparisons, are

summarized in Table 2. The mean treatment interval for the RME-Sz group was 2.4 months longer than for those patients treated with RME alone. Because of the relatively short durations of treatment, however, the data presented reflect actual values and not annualized values.

Skeletal effects

The largest significant difference between the two groups was in the increase in lower anterior facial height (LAFH), as measured from ANS to menton. There was virtually no change (0.2 mm) in the LAFH in the RME-only group, whereas LAFH increased by 1.7 mm in the RME-Sz group. The two measures of the inclination of the mandibular plane revealed that the mandibular plane angle opened slightly in both groups.

In general, neither treatment protocol affected the sagittal position of both the maxilla and the mandible substantially, although the length of the mandible increased more in the RME-Sz group than in the RME-only group. The RME-only group showed a minor but statistically significant increase in the SNA angle in comparison with the other treat-

TABLE 2. Treatment Changes (T₂-T₁)-RME Group vs RME-Schwarz Group^a

| Cephalometric Measures | RME | | RME-Schwarz | | Significance |
|--------------------------------------|------|-----|-------------|-----|--------------|
| | Mean | SD | Mean | SD | |
| Maxillary Skeletal | | | | | |
| SNA (°) | 0.4 | 0.9 | -0.2 | 1.0 | * |
| Na perpendicular to Point A (mm) | 0.2 | 1.0 | 0.1 | 1.1 | NS |
| Maxillary length (Co-A) (mm) | 0.8 | 1.2 | 1.4 | 1.2 | NS |
| Mandibular Skeletal | | | | | |
| SNB (°) | 0.0 | 1.0 | -0.1 | 1.3 | NS |
| Na perpendicular to pogonion (mm) | -0.3 | 1.4 | 0.2 | 1.6 | NS |
| Condylion to gonion (mm) | 0.7 | 1.8 | 1.3 | 1.3 | NS |
| Gonion to pogonion (mm) | 0.9 | 1.6 | 1.7 | 1.8 | NS |
| Mandibular length (Co-Gn) (mm) | 1.5 | 1.2 | 2.9 | 1.9 | ** |
| Maxilla to Mandible | | | | | |
| ANB (°) | 0.4 | 1.0 | -0.1 | 1.3 | * |
| Wits (mm) | 0.7 | 1.9 | 0.7 | 1.9 | NS |
| Maxillomandibular differential (mm) | 0.2 | 1.4 | 1.4 | 1.5 | ** |
| Vertical | | | | | |
| SN to occlusal plane (°) | -0.3 | 3.2 | -0.9 | 1.9 | NS |
| SN to palatal plane (°) | 0.5 | 1.2 | 0.2 | 0.8 | NS |
| SN to mandibular plane (°) | 0.2 | 1.0 | 1.0 | 0.9 | ** |
| Lower facial height (ANS-Me) (mm) | 0.2 | 1.4 | 1.7 | 1.4 | ** |
| Maxillary Dental | | | | | |
| Upper 1 to SN (°) | -1.7 | 4.0 | -2.4 | 4.4 | NS |
| Upper 6 vertical (mm) ^b | -0.8 | 0.9 | 0.1 | 0.8 | ** |
| Upper 6 horizontal (mm) ^b | 0.4 | 0.9 | 0.4 | 0.7 | NS |
| Upper 1 vertical (mm) ^b | 0.1 | 0.8 | -0.6 | 1.4 | * |
| Upper 1 horizontal (mm) ^b | -0.3 | 1.0 | 0.1 | 1.0 | NS |
| Mandibular Dental | | | | | |
| Lower 1 to A-pogonion (mm) | 0.3 | 0.9 | 0.2 | 0.8 | NS |
| Lower 1 to mandibular plane (°) | 0.3 | 5.5 | -0.7 | 3.7 | NS |
| Lower 6 vertical (mm) ^b | 0.1 | 0.8 | 0.8 | 1.3 | * |
| Lower 6 horizontal (mm) ^b | 0.6 | 1.0 | -0.2 | 1.1 | * |
| Lower 1 vertical (mm) ^b | 0.3 | 1.4 | 1.3 | 1.1 | * |
| Lower 1 horizontal (mm) ^b | -0.5 | 0.9 | -0.8 | 0.9 | NS |
| Interdental | | | | | |
| Interincisal angle (°) | 1.3 | 7.2 | 2.6 | 5.9 | NS |

^a NS indicates not significant; RME, rapid maxillary expander; SZ, Schwarz.

^b Measurements made from regional superimpositions.

* $P < .05$.

** $P < .01$.

ment group. Thus, the relative increase in the maxillomandibular differential and the decrease in the ANB angle in the RME-Sz group were a reflection of the changes in the bony bases.

Dentoalveolar effects

The maxillary first molars in the RME-Sz group maintained their vertical position relative to the palatal plane (only 0.1 mm of eruption) as compared with intrusion (-0.8 mm) during the treatment period in the RME-only group, a statistically significant difference. Extrusion of lower molars and incisors was significantly greater in the RME-Sz group than in the RME-only group. The mandibular first molars in the RME-Sz group maintained their po-

sition in the sagittal plane (-0.2 mm), as compared with the slight but significant mesial movement (0.6 mm) in the RME-only group.

DISCUSSION

This prospective clinical investigation of consecutively treated patients was aimed at describing the short-term skeletal and dentoalveolar effects of bonded acrylic-splint RME in conjunction with the lower Schwarz appliance. This study provides new information on a treatment protocol for arch expansion, the bonded RME and the lower removable Schwarz expander, the treatment effects of which have not previously been analyzed cephalometrically. The prospective nature of the investigation, together with the high de-

gree of similarity in starting forms, allowed an adequate assessment of the dentofacial changes produced by the addition of a removable plate for expansion of the lower arch to the classical rapid maxillary expansion procedure with a bonded appliance.

Skeletal effects

Vertical changes. The two protocols examined in this study had interesting effects on vertical skeletal relations. Previous investigations have monitored changes in LAFH in untreated children of the same age as the patients monitored in this study. For example, Riolo et al²³ reported that boys increase about 1.5 mm in LAFH (measured from ANS to menton) for a one year period beginning at age nine years and untreated girls increase about 1.2 mm per year during the same period.

The 0.2 mm increase in LAFH observed in the RME-only group indicated that the acrylic-splint expander has a posterior "bite block effect" in inhibiting occlusal vertical development. In the RME-Sz group, however, the inhibition of vertical development due to the bonded expander may have been counterbalanced by lower arch decompensation (uprighting with consequent extrusion of the lower posterior teeth). The net result of the RME-Sz treatment was an increase in LAFH of 1.5 mm, a value that can be considered within normal limits.

Patients treated with the bonded RME alone did not show modification in the vertical position of the mandible relative to the cranial base. These results differ from those reported by Sarver and Johnston¹² and by Akkaya et al,¹⁶ who observed a downward and backward rotation of the mandible in their analysis of the acrylic-splint RME. They attributed the mandibular change to either maxillary palatal cuspal interference after expansion or remnants of bonding material on the occlusal surface of posterior teeth after appliance removal. Retained bonding agent was not a factor in this study because the occlusal surfaces were not etched before placement of the appliance and all adhesive was removed at the time of splint debonding. Furthermore, in the RME-only group, maxillary molar intrusion probably counteracted any cuspal interference, resulting in no overall change in mandibular position. Neither Sarver and Johnston¹² nor Akkaya et al¹⁶ included maxillary molar vertical measures in their cephalometric analysis; therefore, a direct comparison with the results of this study is not possible.

Regardless of the dentoalveolar changes affecting the position of the mandible, the acrylic-splint RME has been shown to produce less downward and backward rotation of the mandible than the banded RME.¹⁵ Short-term analyses of the banded RME have reported 1° to 2° of mandibular "clockwise" rotation,^{5,12,22-25} as compared with 0.2° increase in the mandibular plane angle with the acrylic-splint RME appliance. These outcomes have been confirmed fully by this study.

Sagittal changes. Patients undergoing combined RME-Sz therapy did not experience the increase in the SNA angle, an observation described previously by several investigators, as a result of rapid maxillary expansion alone with banded appliances. Short-term studies^{5,24} reported forward positioning of Point A after banded RME. Long-term studies^{13,26,27} have reported forward movement of the maxilla after banded RME removal, followed by recovery of the maxillary position at the end of fixed appliance treatment.

On the other hand, the findings of this study regarding treatment effects of the bonded RME used alone are similar to previous data provided by Akkaya et al,¹⁶ who described a 1° advancement of the maxilla. They differ, however, from the results of Sarver and Johnston¹² who noted a slight decrease (-0.8°) in the SNA angle in their treated sample. Even though this investigation and the one by Sarver and Johnston¹² are both short-term cephalometric studies, the treatment interval differed. Sarver and Johnston reported a 3-month appliance stabilization period, whereas the treatment regimen in this study included a 5-month stabilization period after the completion of active expansion.¹ The additional two months of treatment in this study may have resulted in the forward movement of the maxilla, perhaps due in part to the continued posterior bite block effect. In fact, the slight forward movement of the maxilla seen in the patients treated with the acrylic-splint RME alone correlates with the results of several experimental investigations of the effects of posterior bite blocks.²⁸⁻³⁰

RME treatment resulted in an increase in the ANB angle as a consequence of the forward movement of the maxilla described previously. The change in the ANB angle was an average of 0.6° greater in the RME-only group than in the RME-Sz group at the end of treatment. In the study by Akkaya et al,¹⁶ the rather large increase in the ANB angle (1.6°) was ascribed both to the increase in SNA angle and the decrease in SNB angle.

Subjects treated with the acrylic-splint RME in conjunction with a Schwarz appliance experienced a significant supplementary elongation of the mandible (+1.4 mm) when compared with the subjects treated with RME alone. The RME-Sz group, however, had a slightly shorter mandibular length at the beginning of treatment than did the group treated by RME alone, and there could have been a slight difference in the skeletal maturity of patients in the two groups at the start of treatment.

Dentoalveolar effects

Two of the more interesting findings of this investigation were that the acrylic-splint expansion appliance produced maxillary molar intrusion in the RME-only group and prevented maxillary molar eruption in the RME-Sz group. Banded RME devices have been shown to result in downward movement of the maxillary posterior teeth secondary to downward movement of the maxilla.^{5,13,25,31} The downward inclination of the palatal plane did not appear to play

a role in the posttreatment vertical position of the maxillary molars in this study.

The addition of the lower Schwarz appliance to the treatment protocol allowed for a significant extrusion of lower molars and incisors. These changes correlate with the increase in the vertical skeletal dimension noted previously.

The lower expander also appeared to prevent the mesial movement of the mandibular first molars (-0.2 mm), whereas the RME-only protocol led to a 0.6 mm mesial movement of the molars. This effect can be helpful in gaining arch length in subjects showing mild to moderate crowding, whereas it can be regarded as unfavorable in subjects with distal molar relationships.

Observations regarding spontaneous correction of Class II malocclusion

Some additional observations of clinical interest were made during the collection of the records for this prospective study. Fourteen of the original 58 patients in the sample for this study were eliminated because of forward positioning of the mandible in the T_2 lateral cephalogram, a percentage of patients much higher than in other cephalometric studies conducted by our group.

The forward mandibular posture was determined by the observation of an increased distance between the posterior border of the ramus and the anterior border of the atlas on the T_2 radiograph. No patients were excluded because of erroneous mandibular positioning before treatment (T_1). Because all headfilms were taken according to a standardized protocol and each patient was instructed by the operator to "move your tongue to the back of your mouth and bite on your back teeth," it seems as if this forward posturing of the mandible may be a result of the disruption of the posterior occlusion, producing a tendency for the patients to bring their jaw into a forward position on closure.

These observations may be the indirect evidence that treatment with an acrylic-splint expander may create an environment conducive for "spontaneous Class II correction," as described by McNamara and Brudon,¹ and McNamara.^{4,8} The authors contend that Class II malocclusions have a strong transverse component and that the overexpanded maxillary arch may encourage the forward positioning of the mandible to reduce the tendency to buccal crossbite and provide a more comfortable occlusal relationship. Hence, the teeth themselves may act as an "endogenous functional appliance."¹ The relationship between mandibular position and maxillary width also was discussed by Kingsley³² over a century ago. He described the correction of Class II molar relationship by "widening of the upper jaw until the lower would be received in its forward and natural place."

It may be argued that the forward posturing of the mandible after removal of an acrylic-splint RME appliance is just a transient phenomenon. After months of wear and sig-

nificant alteration in the width of the maxilla, it can be hypothesized that a child may experience a period of occlusal disorientation that may result in a change in the postural position of the mandible. The initial postural change may become permanent in a young patient as the anatomical integrity of the temporomandibular joint region becomes reestablished through further craniofacial growth.^{33,34} Long-term follow-up of such patients would provide more substantial information.

CONCLUSIONS

This prospective clinical study evaluated the short-term treatment effects of acrylic-splint rapid maxillary expansion with or without lower Sz appliance therapy. In general, the sagittal and vertical changes were relatively minimal in both treatment protocols.

- The largest difference between the two groups was in LAFH. No change in LAFH was observed in the RME-only group during the treatment period, whereas LAFH increased by 1.5 mm more in the RME-Sz group.
- The two measures of the inclination of the mandibular plane revealed that the mandibular plane angle opened by less than 1° in both groups.
- Slight forward displacement of the maxilla was observed when RME was used alone. The sagittal position of the maxilla remained unchanged in the RME-Sz group.
- A significant amount of intrusion of the maxillary molars (-0.8 mm) was noted in the RME-only group. The maxillary molars were prevented from erupting in the RME-Sz group.
- The lower dentition showed a significantly greater amount of extrusion in the RME-Sz group than in the RME-only group.

ACKNOWLEDGMENT

This research was supported in part by funds made available through the Thomas M. and Doris Graber Endowed Professorship, the Department of Orthodontics and Pediatric Dentistry, The University of Michigan.

REFERENCES

1. McNamara JA Jr, Brudon WL. *Orthodontics and Dentofacial Orthopedics*. Ann Arbor, Mich: Needham Press; 2001.
2. Howe RP. Palatal expansion using a bonded appliance. Report of a case. *Am J Orthod*. 1982;82:464-468.
3. McNamara JA Jr. An orthopedic approach to the treatment of Class III malocclusion in young patients. *J Clin Orthod*. 1987; 21:598-608.
4. McNamara JA Jr. Maxillary transverse deficiency. *Am J Orthod Dentofacial Orthop*. 2000;117:567-570.
5. Haas AJ. Rapid expansion of the maxillary dental arch and nasal cavity by opening the mid-palatal suture. *Angle Orthod*. 1961;31: 73-90.
6. Spolyar JL. The design, fabrication, and use of a full-coverage bonded rapid maxillary expansion appliance. *Am J Orthod*. 1984; 86:136-145.

7. Alpern MC, Yurosko JJ. Rapid palatal expansion in adults with and without surgery. *Angle Orthod.* 1987;57:245–263.
8. McNamara JA Jr. Early intervention in the transverse dimension: is it worth the effort? *Am J Orthod Dentofacial Orthop.* 2002;121:572–574.
9. Spillane LM, McNamara JA Jr. Maxillary adaptations following expansion in the mixed dentition. *Semin Orthod.* 1995;1:176–187.
10. Brust EW, McNamara JA Jr. Arch dimensional changes concurrent with expansion in mixed dentition patients. In: Trotman CA, McNamara JA Jr, eds. *Orthodontic Treatment: Outcome and Effectiveness, Monograph 30, Craniofacial Growth Series.* Ann Arbor, Mich: Center for Human Growth and Development, University of Michigan; 1995:193–225.
11. Memikoglu TUT, İşeri H. Effects of a bonded rapid maxillary expansion appliance during orthodontic treatment. *Angle Orthod.* 1999;69:251–256.
12. Sarver DM, Johnston MW. Skeletal changes in vertical and anterior displacement of the maxilla with bonded rapid palatal expansion appliances. *Am J Orthod Dentofacial Orthop.* 1989;95:462–466.
13. Wertz RA. Skeletal and dental changes accompanying rapid midpalatal suture opening. *Am J Orthod.* 1970;58:41–66.
14. Asanza S, Cisneros GJ, Nieberg LG. Comparison of hyrax and bonded expansion appliances. *Angle Orthod.* 1999;69:251–256.
15. Reed N, Ghosh J, Nanda RS. Comparison of treatment outcomes with banded and bonded RPE appliances. *Am J Orthod Dentofacial Orthop.* 1999;116:31–40.
16. Akkaya S, Lorenzon S, Üçem TT. A comparison of sagittal and vertical effects between bonded rapid and slow maxillary expansion procedures. *Eur J Orthod.* 1999;21:175–180.
17. McNamara JA Jr. A method of cephalometric evaluation. *Am J Orthod.* 1984;86:449–469.
18. McNamara JA Jr, Bookstein FL, Shaughnessy TG. Skeletal and dental changes following functional regulator therapy on Class II patients. *Am J Orthod.* 1985;88:91–110.
19. McNamara JA Jr, Howe RP, Dischinger TG. A comparison of the Herbst and Fränkel appliances in the treatment of Class II malocclusion. *Am J Orthod Dentofacial Orthop.* 1990;98:134–144.
20. Ricketts RM. Perspectives in the clinical application of cephalometrics. The first fifty years. *Angle Orthod.* 1981;51:115–150.
21. Steiner CC. Cephalometrics for you and me. *Am J Orthod.* 1953;39:729–755.
22. Jacobson A. The “Wits” appraisal of jaw disharmony. *Am J Orthod.* 1975;67:125–138.
23. Riolo ML, Moyers RE, McNamara JA Jr, Hunter WS. *An Atlas of Craniofacial Growth: Cephalometric Standards from The University School Growth Study, Monograph 2, Craniofacial Growth Series.* Ann Arbor, Mich: Center for Human Growth and Development, The University of Michigan; 1974:186.
24. Davis WM, Kronman JH. Anatomical changes induced by splitting of the midpalatal suture. *Angle Orthod.* 1969;39:126–132.
25. Wertz R, Dreskin M. Midpalatal suture opening: a normative study. *Am J Orthod.* 1977;71:367–381.
26. Haas AJ. Long-term posttreatment evaluation of rapid palatal expansion. *Angle Orthod.* 1980;50:189–217.
27. Chang JY, McNamara JA Jr, Herberger TA. A longitudinal study of skeletal side-effects induced by rapid maxillary expansion. *Am J Orthod Dentofacial Orthop.* 1997;112:330–337.
28. McNamara JA Jr. An experimental study of increased vertical dimension in the growing face. *Am J Orthod.* 1977;71:382–395.
29. Woods MG, Nanda RS. Intrusion of posterior teeth with magnets. An experiment in growing baboons. *Angle Orthod.* 1988;58:136–150.
30. Hoenie DC, McNamara JA Jr. The effect of interocclusal repelling magnets in a bite-opening splint on the growth of the craniofacial complex in juvenile *Macaca mulatta*. In: McNamara JA Jr, ed. *The Enigma of the Vertical Dimension, Monograph 36, Craniofacial Growth Series.* Ann Arbor, Mich: Center for Human Growth and Development, University of Michigan; 2000: 219–292.
31. Haas AJ. Palatal expansion: just the beginning of dentofacial orthopedics. *Am J Orthod.* 1970;57:219–255.
32. Kingsley NW. *A Treatise on Oral Deformities as a Branch of Mechanical Surgery.* New York, NY: Appleton; 1880.
33. McNamara JA Jr. Neuromuscular and skeletal adaptations to altered function in the orofacial region. *Am J Orthod.* 1973;64:578–606.
34. McNamara JA Jr, Carlson DS. Quantitative analysis of temporomandibular joint adaptations to protrusive function. *Am J Orthod.* 1979;76:593–611.